





Anatomische Steinstiche oder bildliche Darstellung des menschlichen Körpers so wie seiner Theile


<https://hdl.handle.net/1874/282867>




THE
IE
E
NG
EN

ER







LABORE ET STUDIO

Anatomische Steinsteife
ODER
BILDLICHE
DARSTELLUNG
DES

MENSCHLICHEN
KÖRPERS

SO WIE
SEINER THEILE

MIT
BENÜTZUNG

DES

BESTEN BISHER GELEISTETEN

GEZEICHNET

IN STEIN GESTOCHEN

UND

IN SECHS ABTHEILUNGEN

GESAMMELT UND HERAUSGEGEBEN

VON

HEINRICH OESTERREICHER

DER GESAMMTEN MEDICIN DOCTOR

MÜNCHEN

1830




4783

BENDICT IM DECEMBER DES JAHRS MDCCCXXIX

BEGONNEN IM JUNI DES JAHRES MDCCCXXVII

AS YOU LIKE IT



OESTERREICHER'S

Anatomische Steinstücke.

Erste Abtheilung

Knochen

des

Menschlichen Körpers.

München

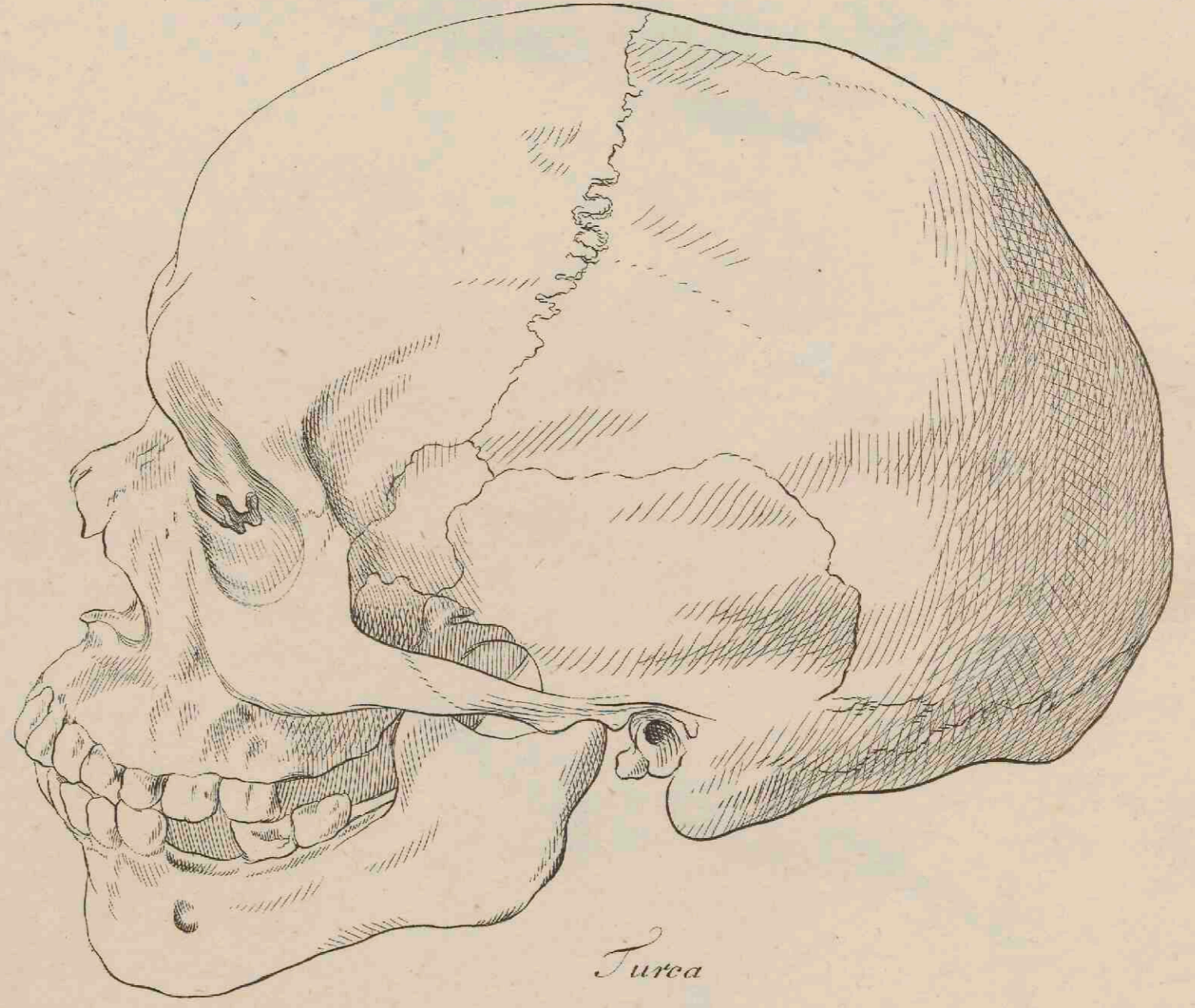
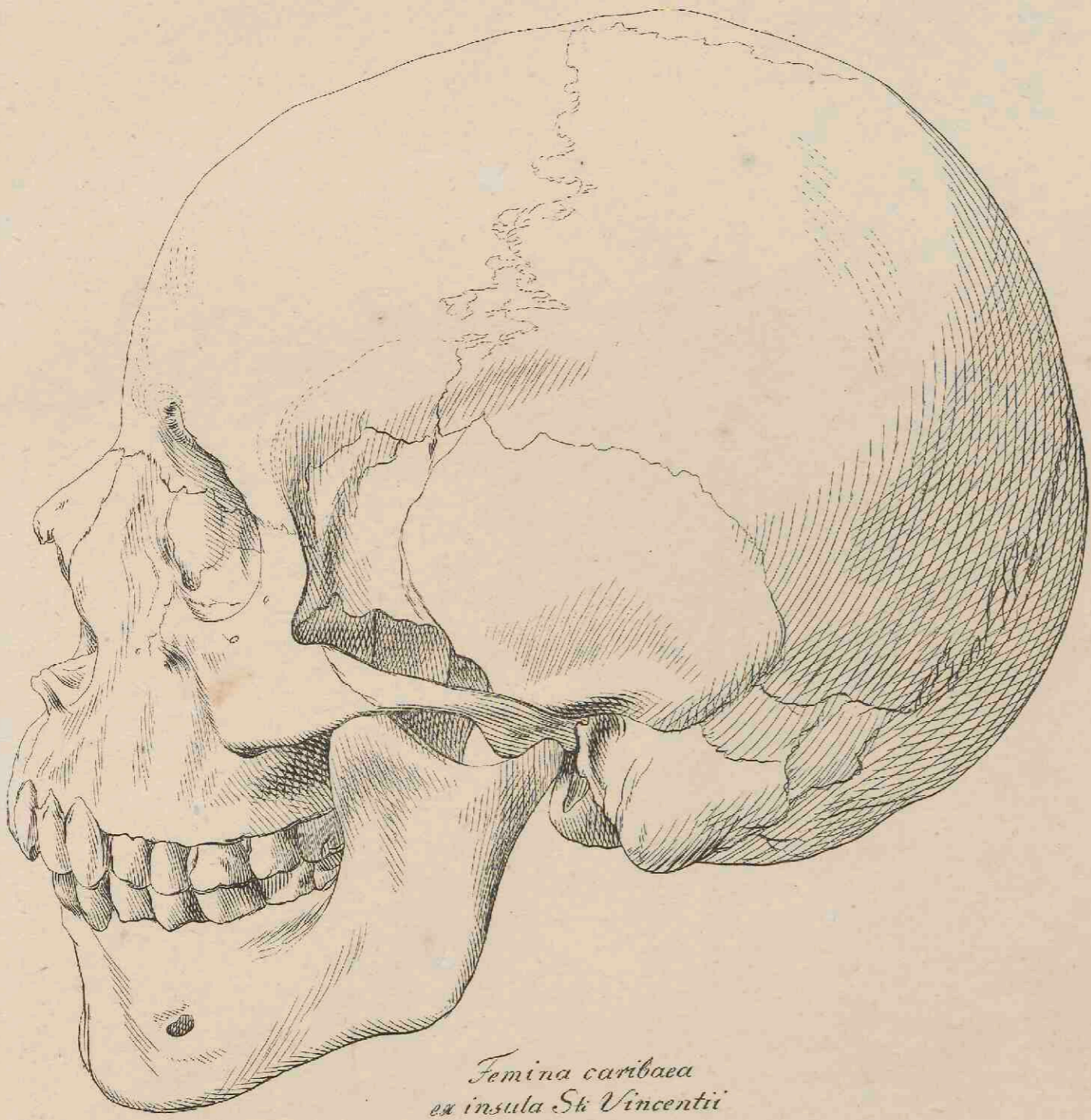
1829

Racenverschiedenheit

Tatarus casanensis.

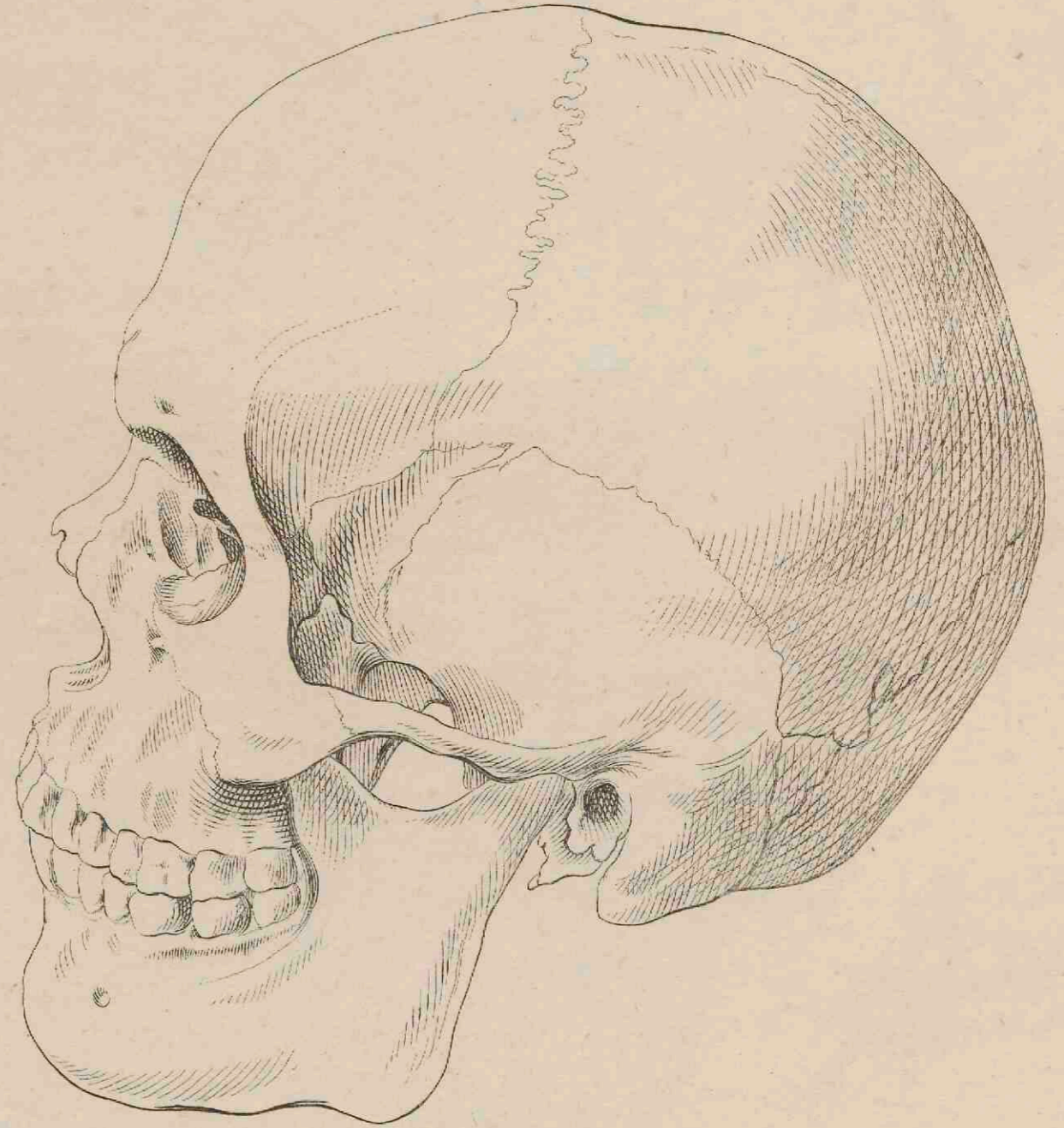
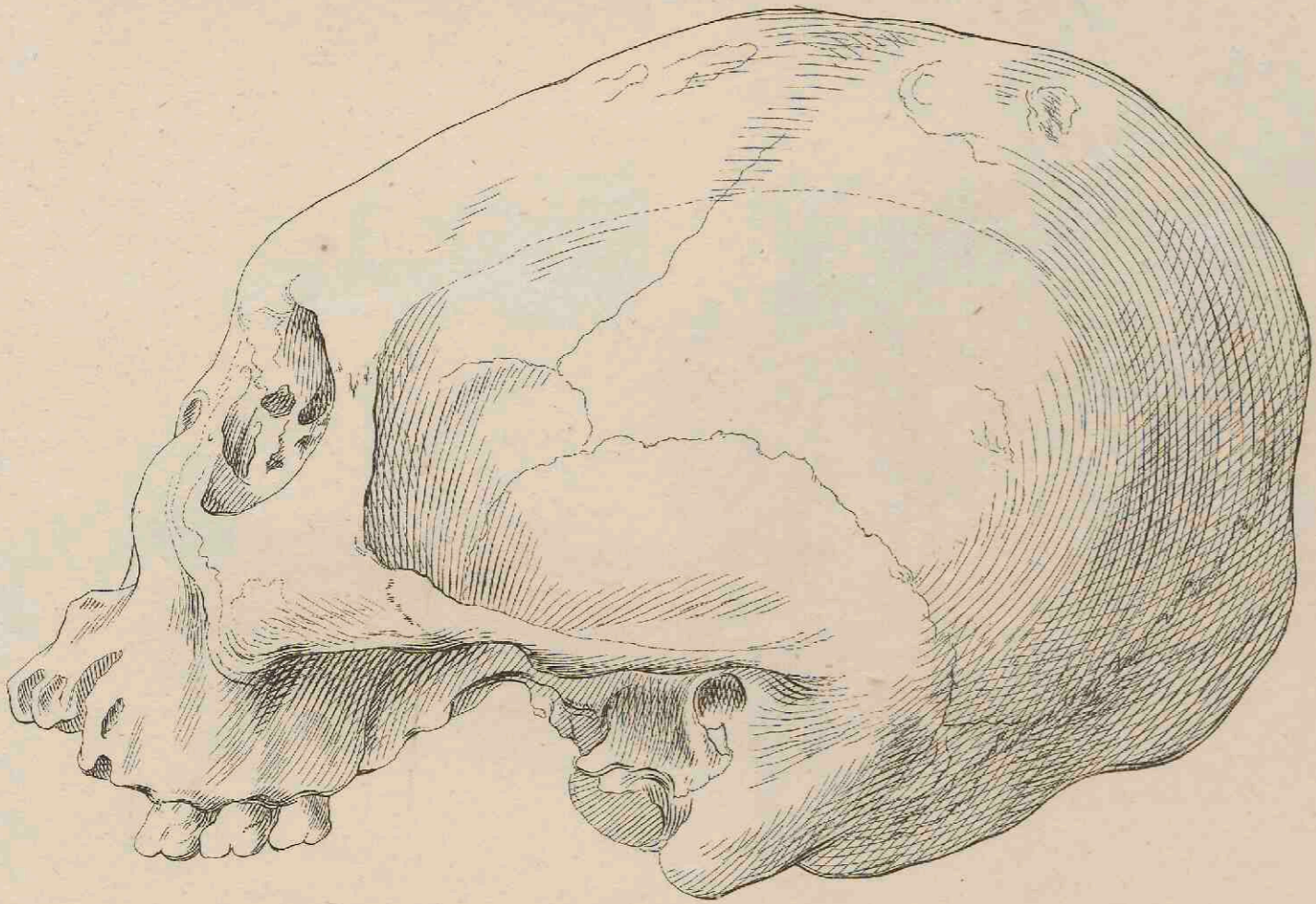
nach Blumenbach.

Aethiops



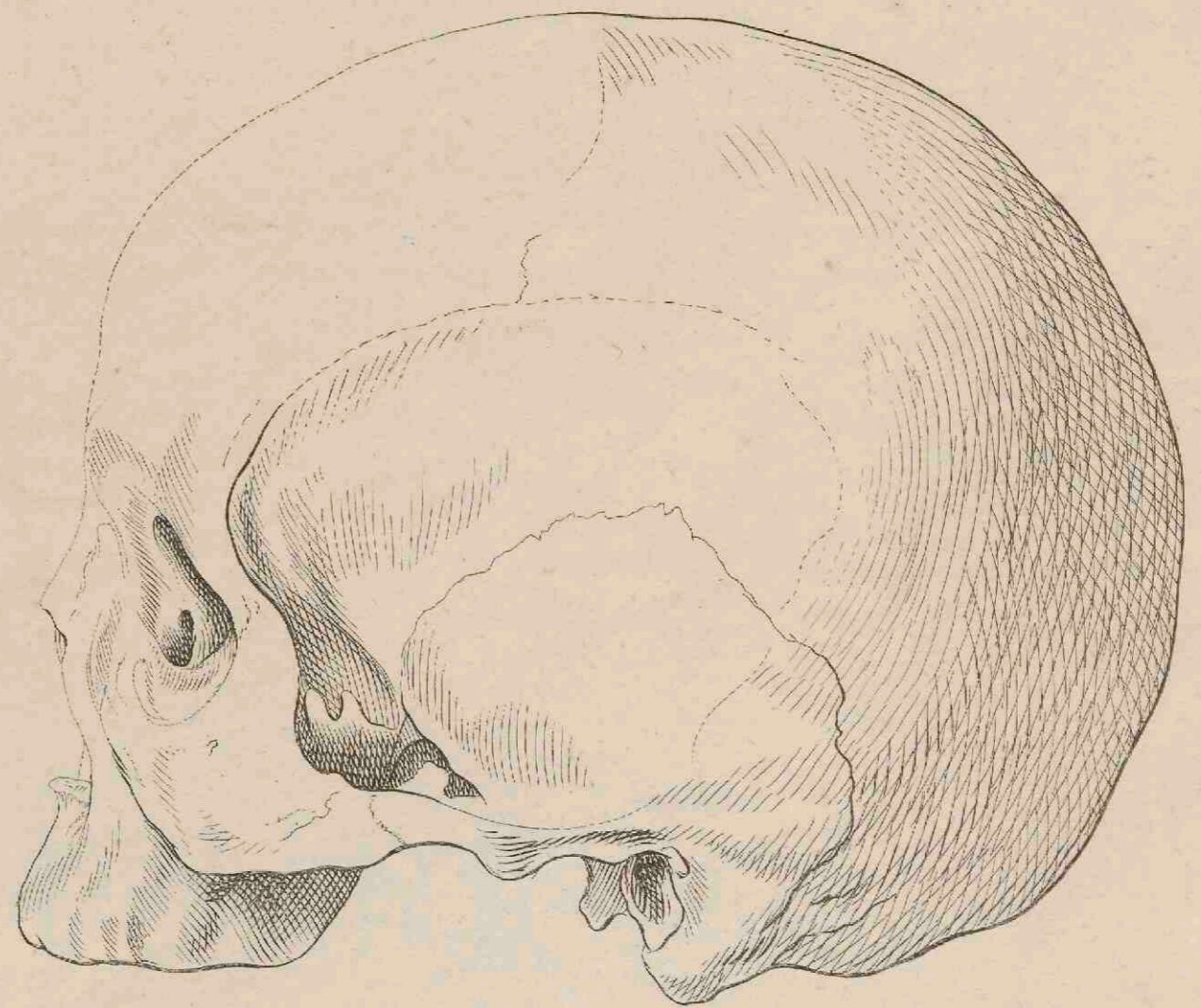
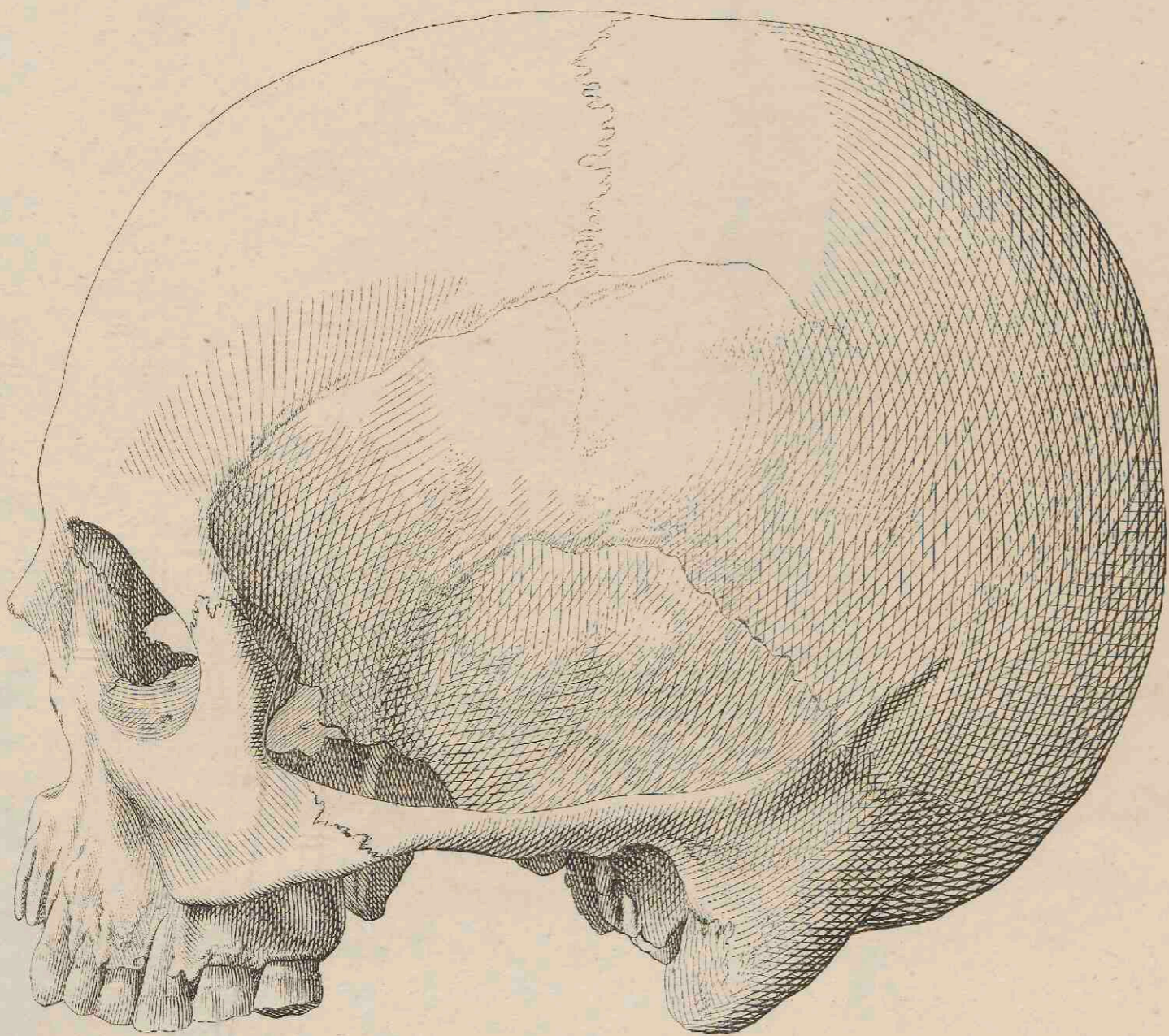
*Femina caribaea
ex insula St. Vincentii*

Tureca



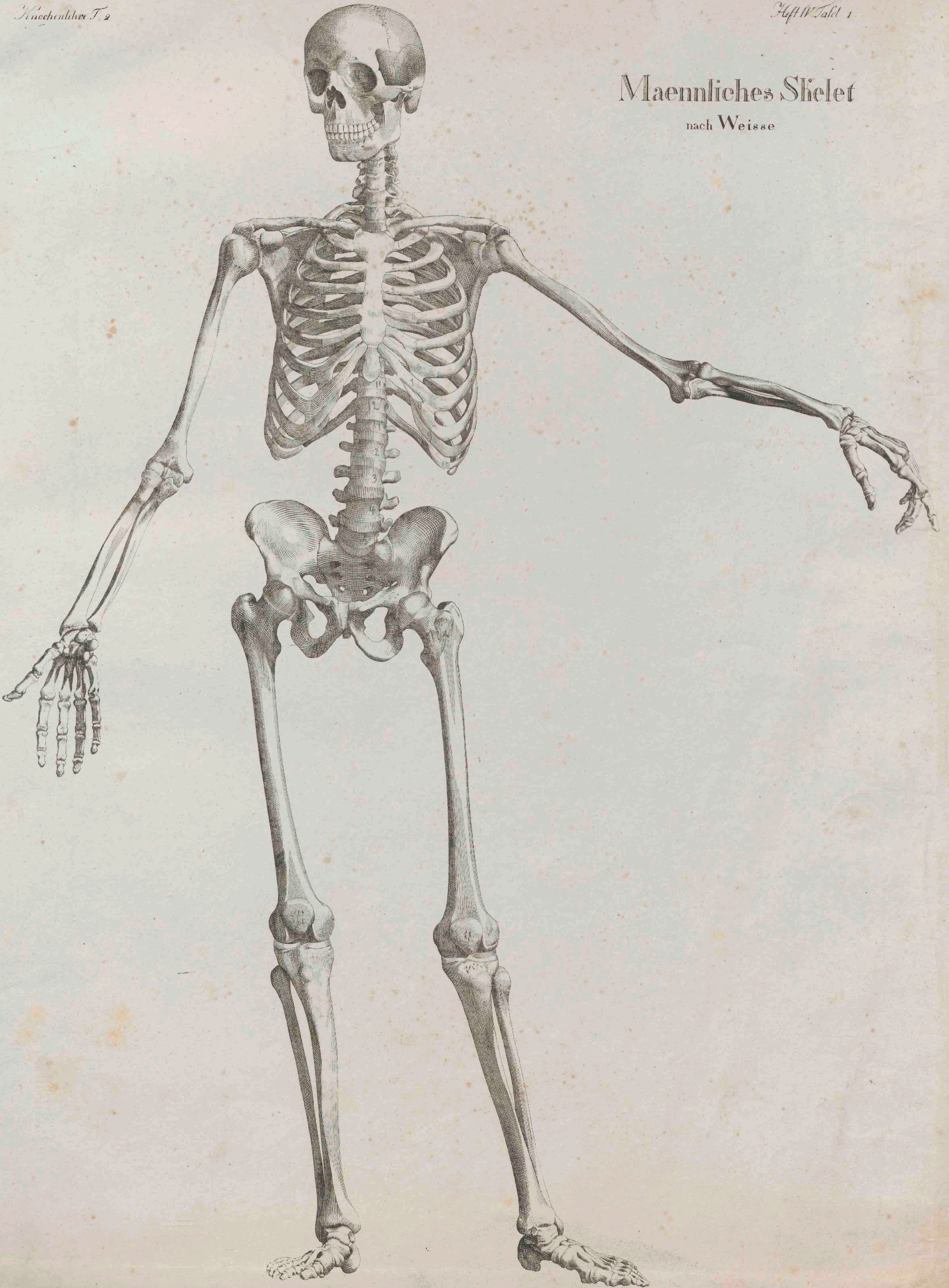
Graculus vetus

Calmuccus



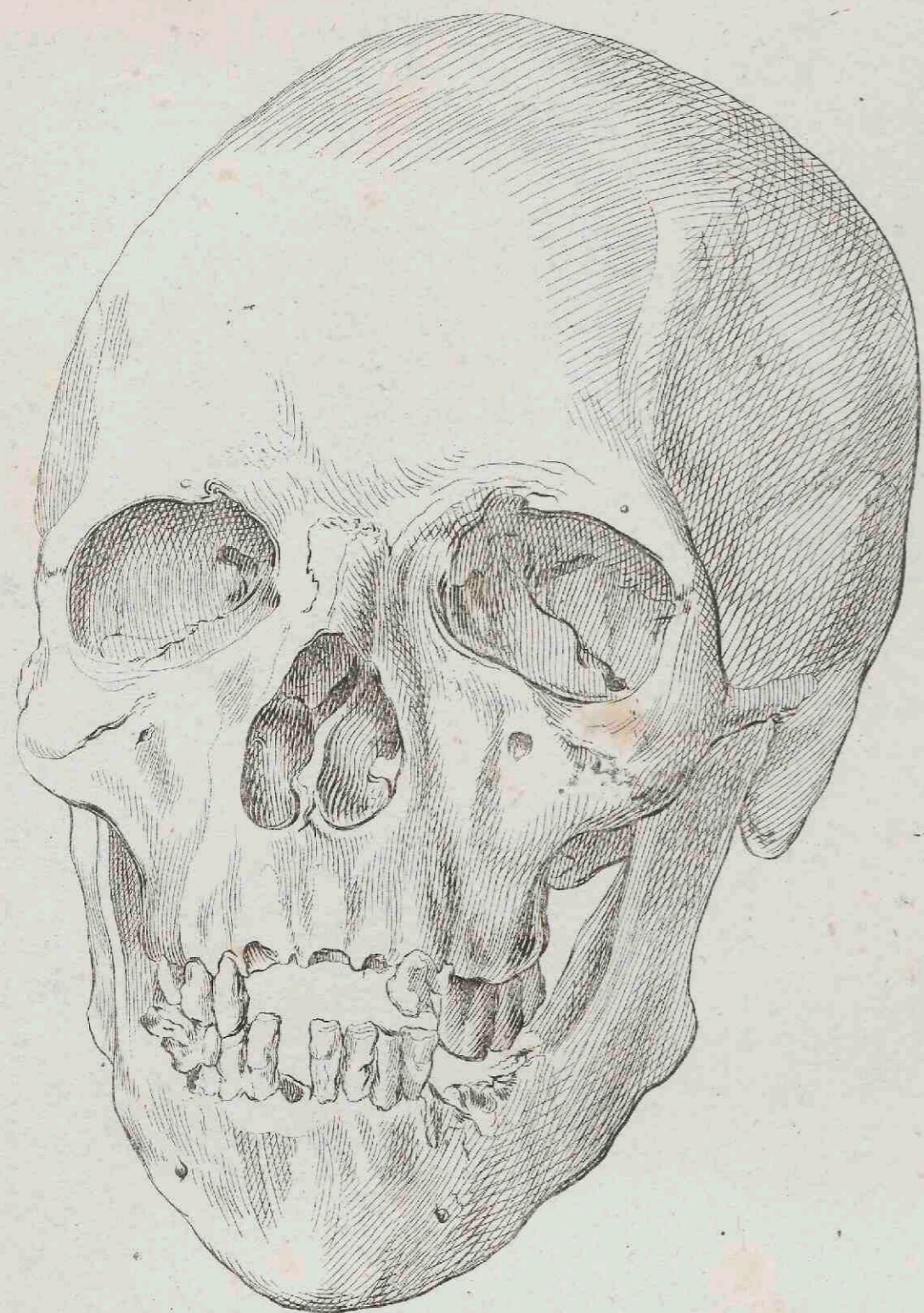
Maennliches Skelet

nach Weisse

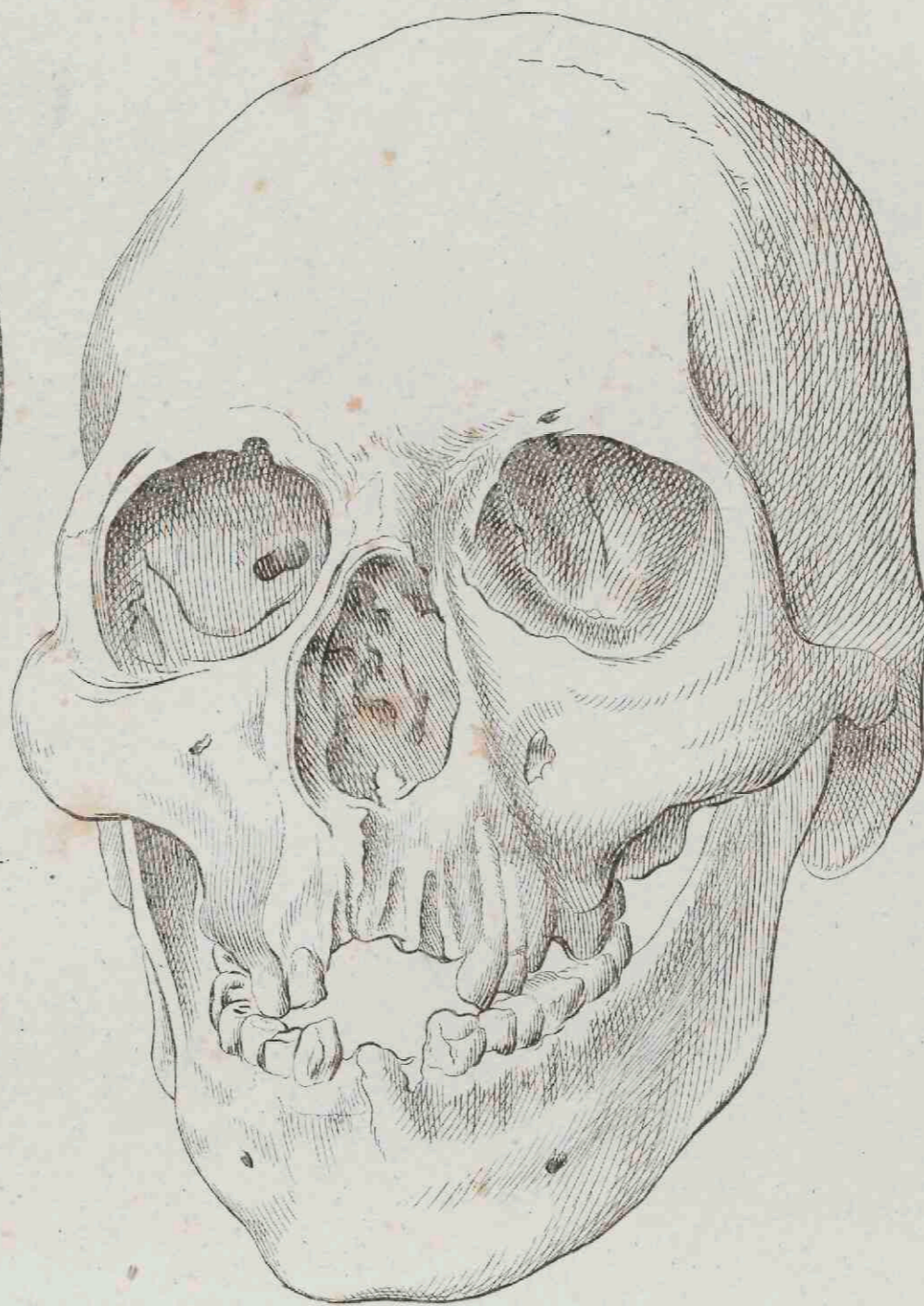


Racenverschiedenheit

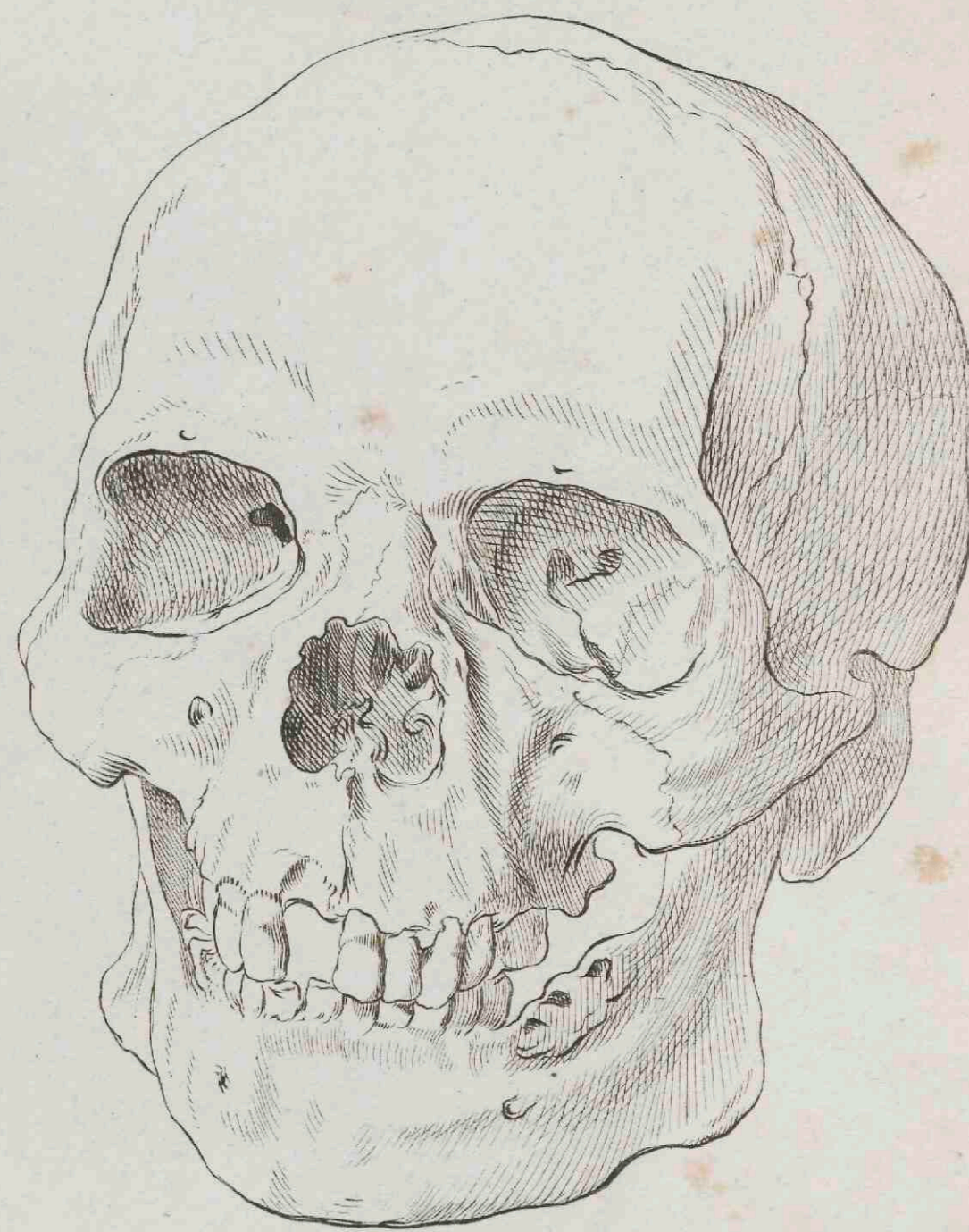
nach Blumenbach



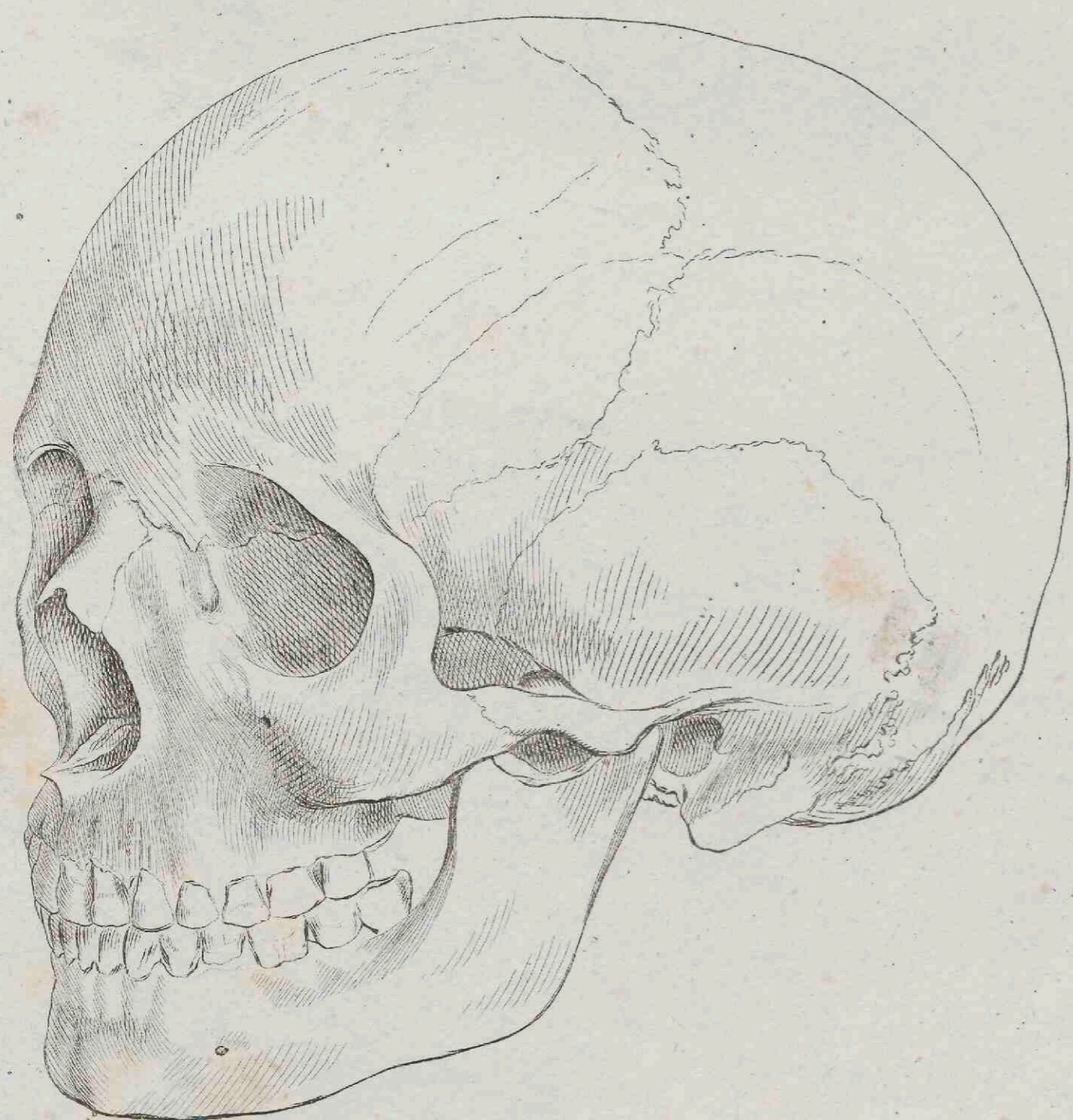Angarus genuinus



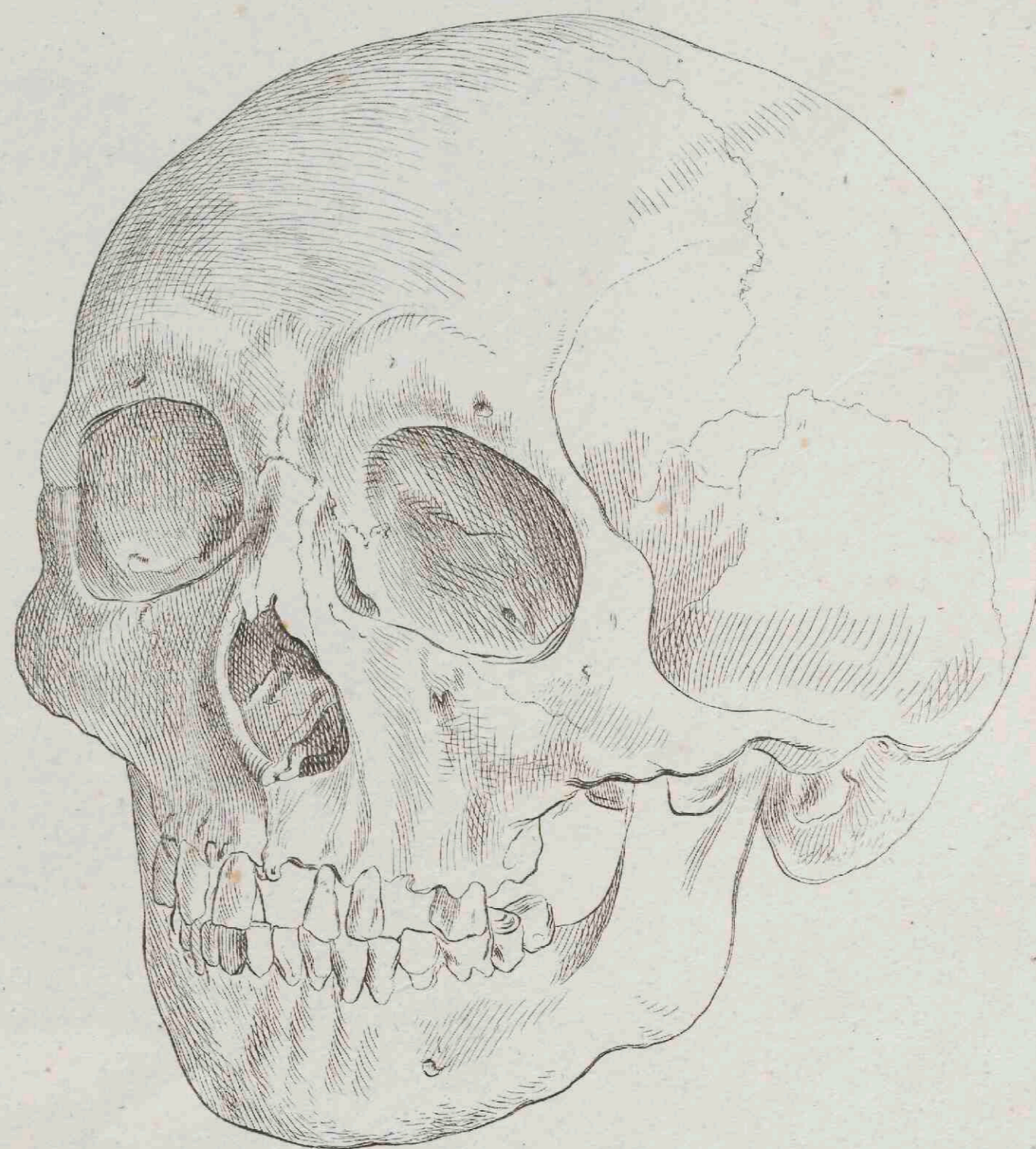
Mumia Aegyptiaca



Casaccus Donensis

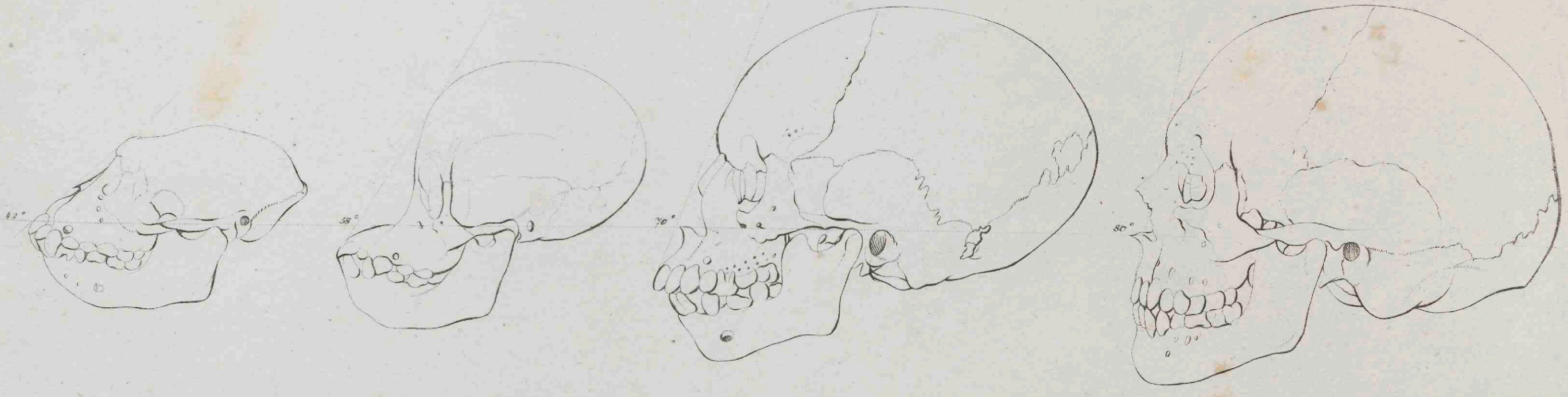


Femina Georgiana



Calmuccus

Camper's Gesichtswinkel.

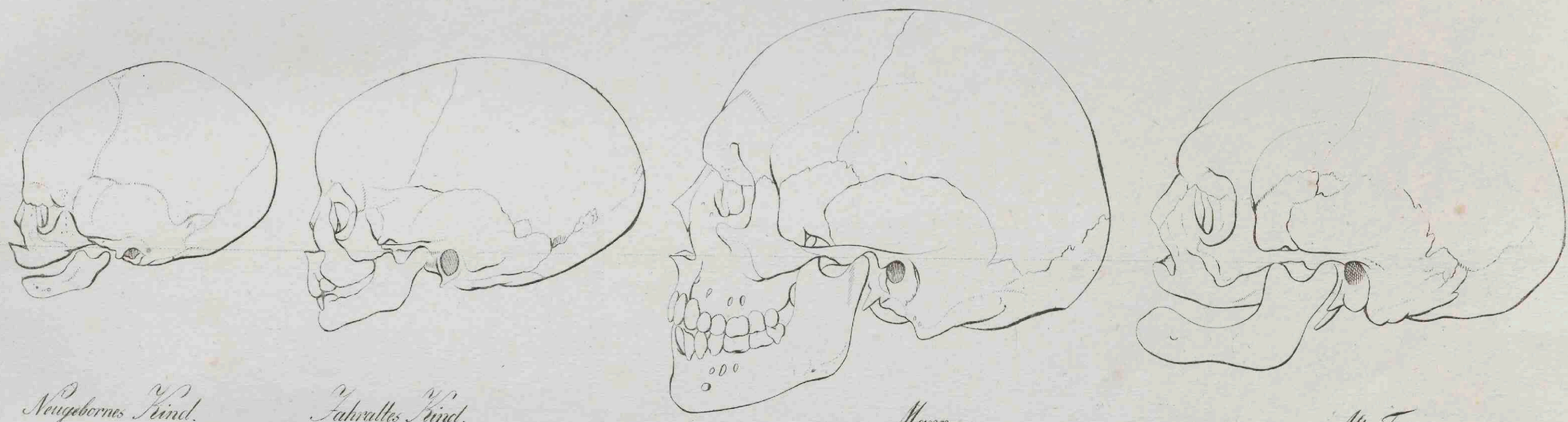


Gefchwanzter Affe.

Orang-Utang.

Neger

Eurpäer.

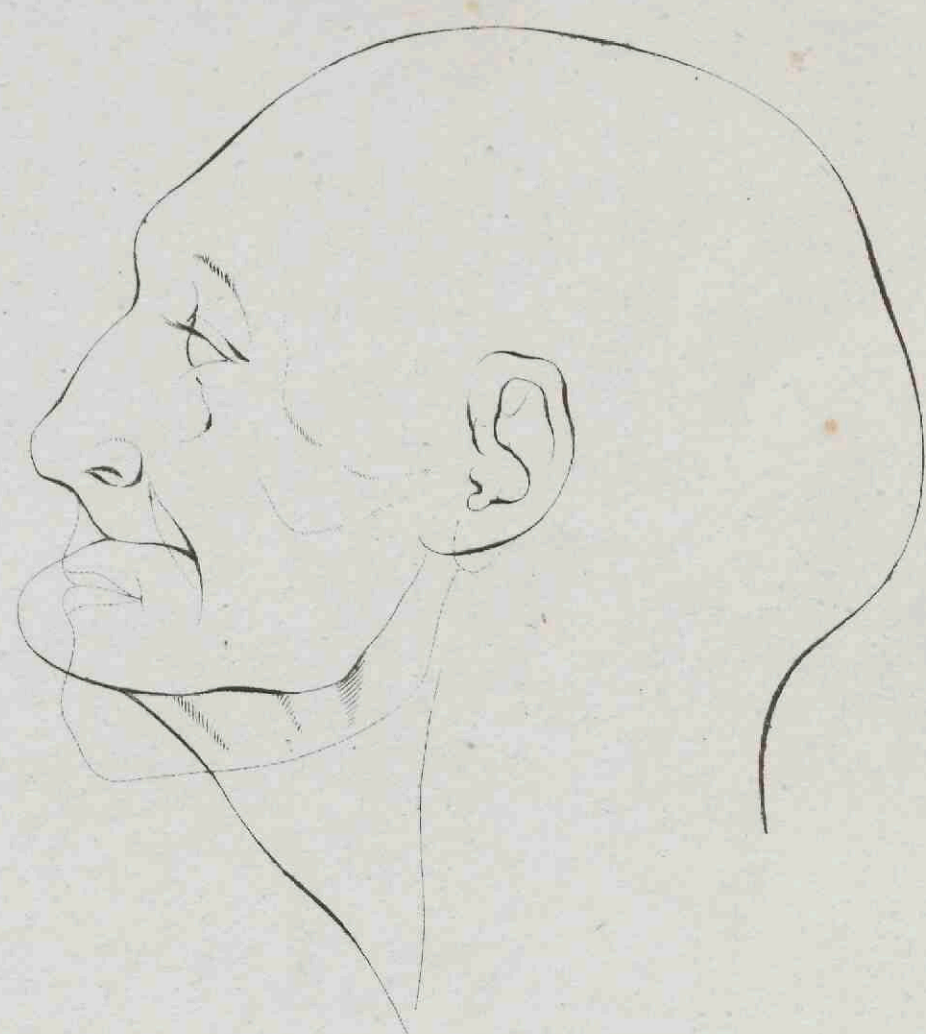
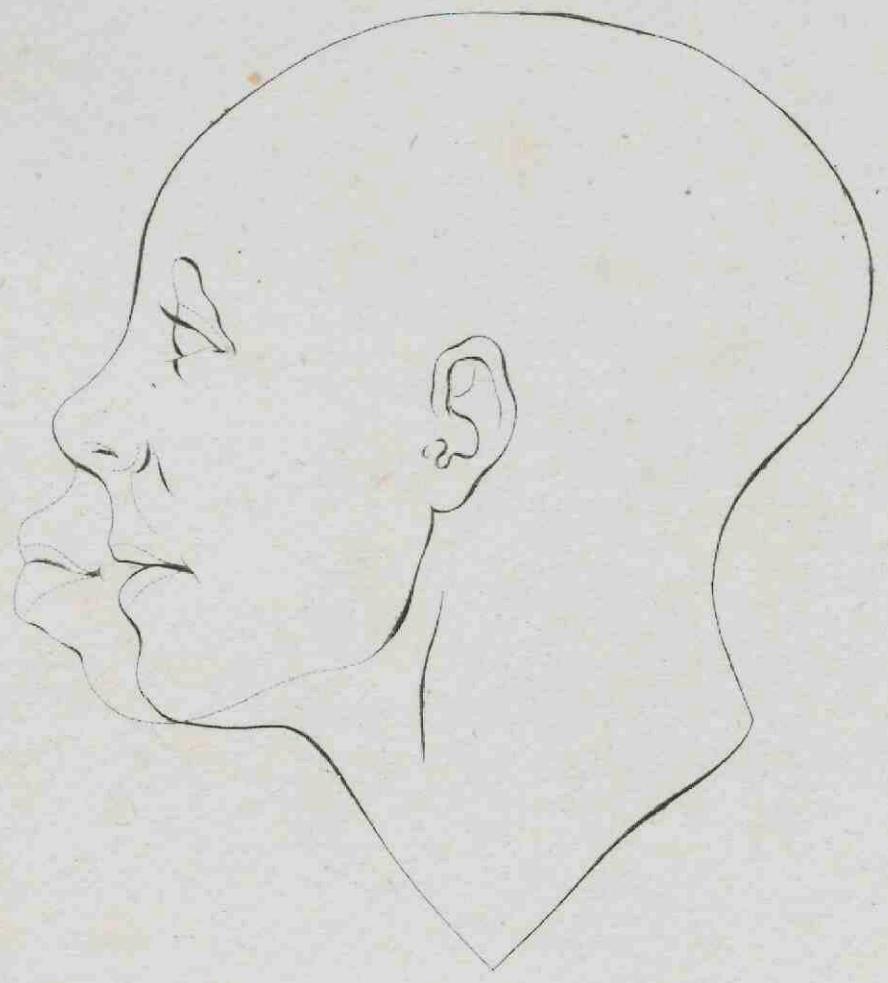


Neugeborenes Kind.

Schuldes Kind.

Mann.

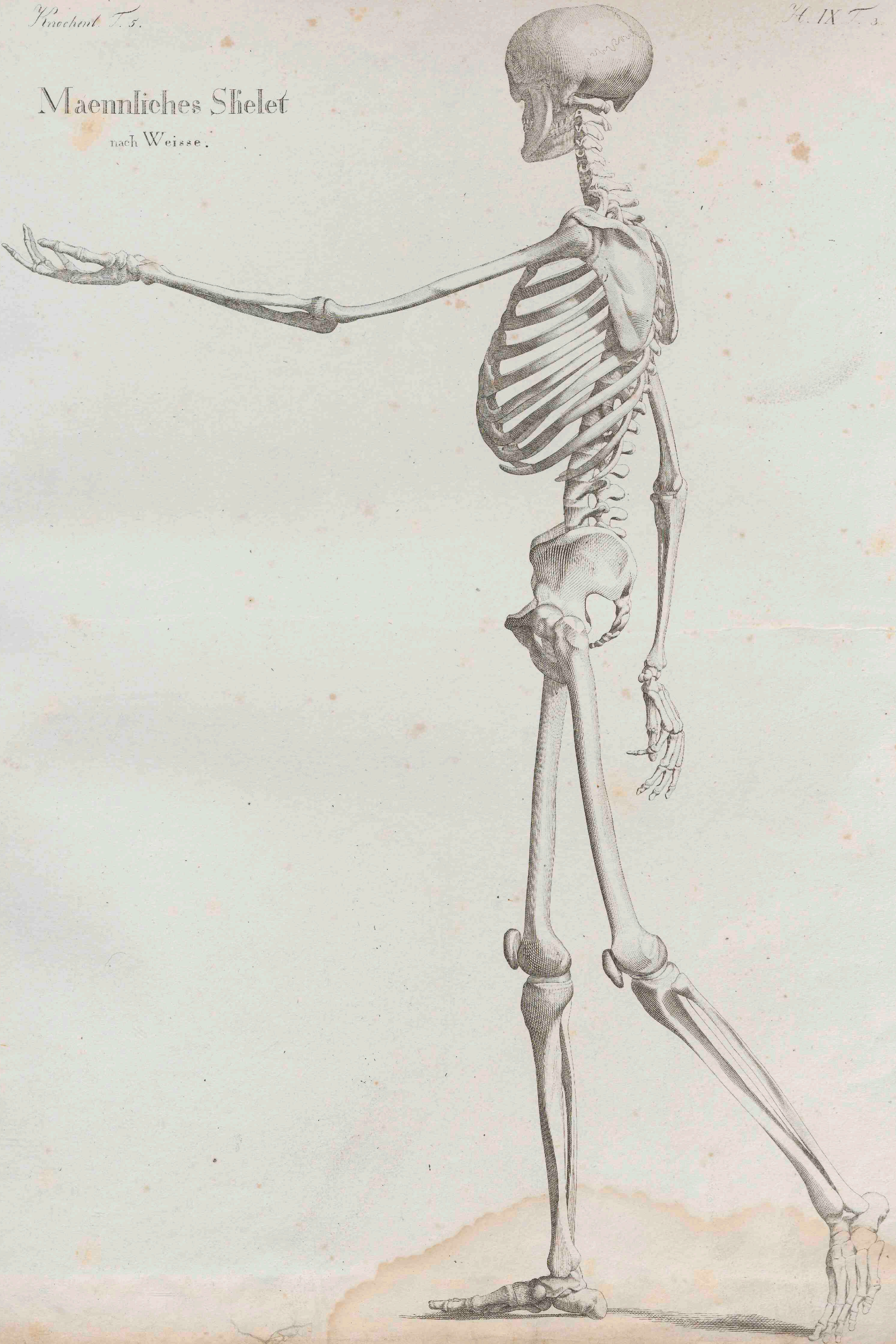
Alte Frau.



Der Gesichtswinkel des Menschen hat in der Natur eine äußerste Größe und eine äußerste Kleinheit — ein maximum und ein minimum — von 70 : 80° ; alles, was darüber läuft ist nach Kunstregeln gemacht, und alles, was sich unter 70° neigt, gibt eine Ähnlichkeit mit Affen. — Dies gilt jedoch weder vom Kindes- noch vom Greisen-Alter, da bei erstem die Nasen und Zähne noch nicht entwickelt, bei letztem aber nach dem Ausfallen der Zähne die Ausfüllungsfortsätze zusammengedrückt sind.

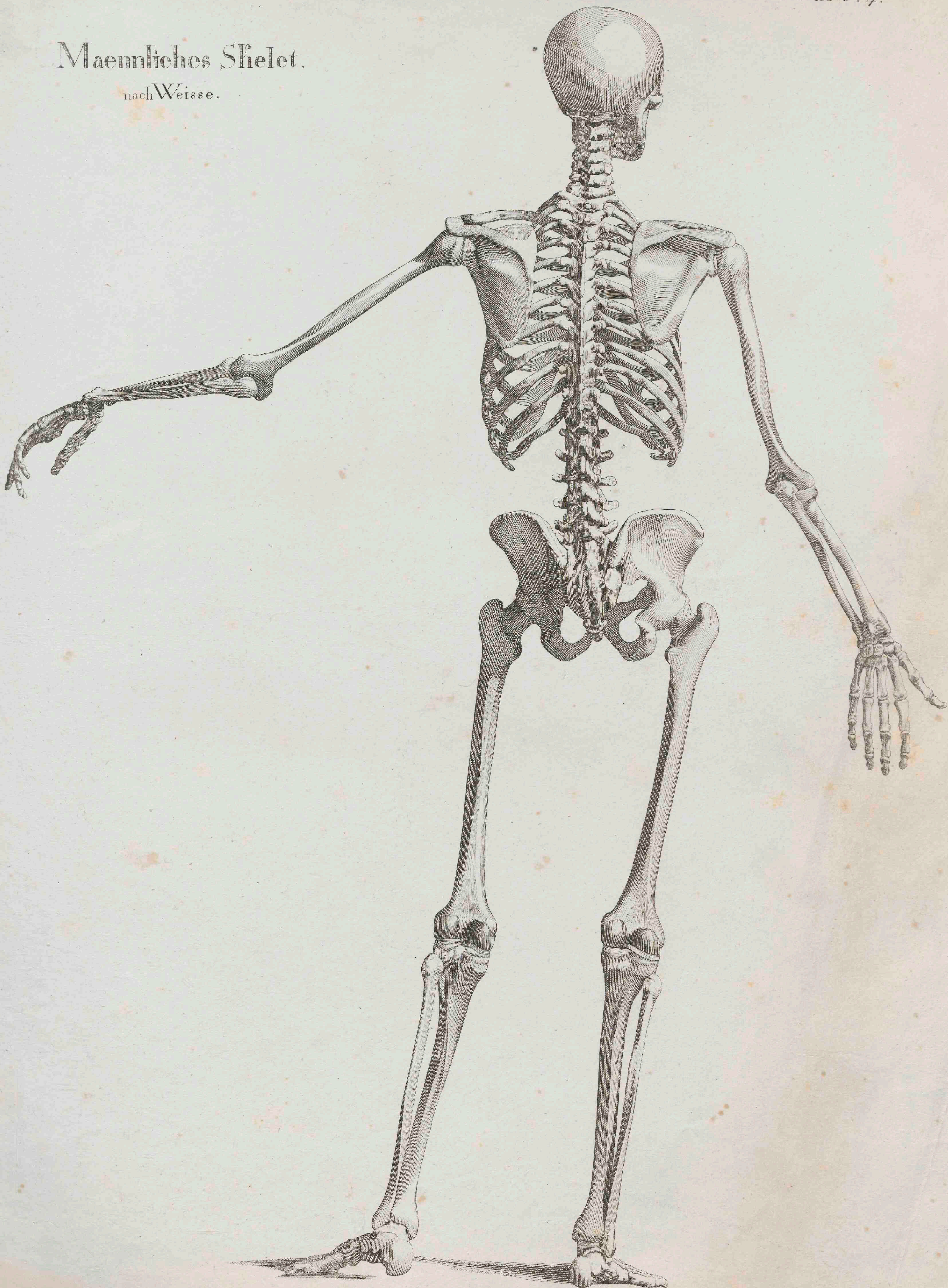Maennliches Scelet

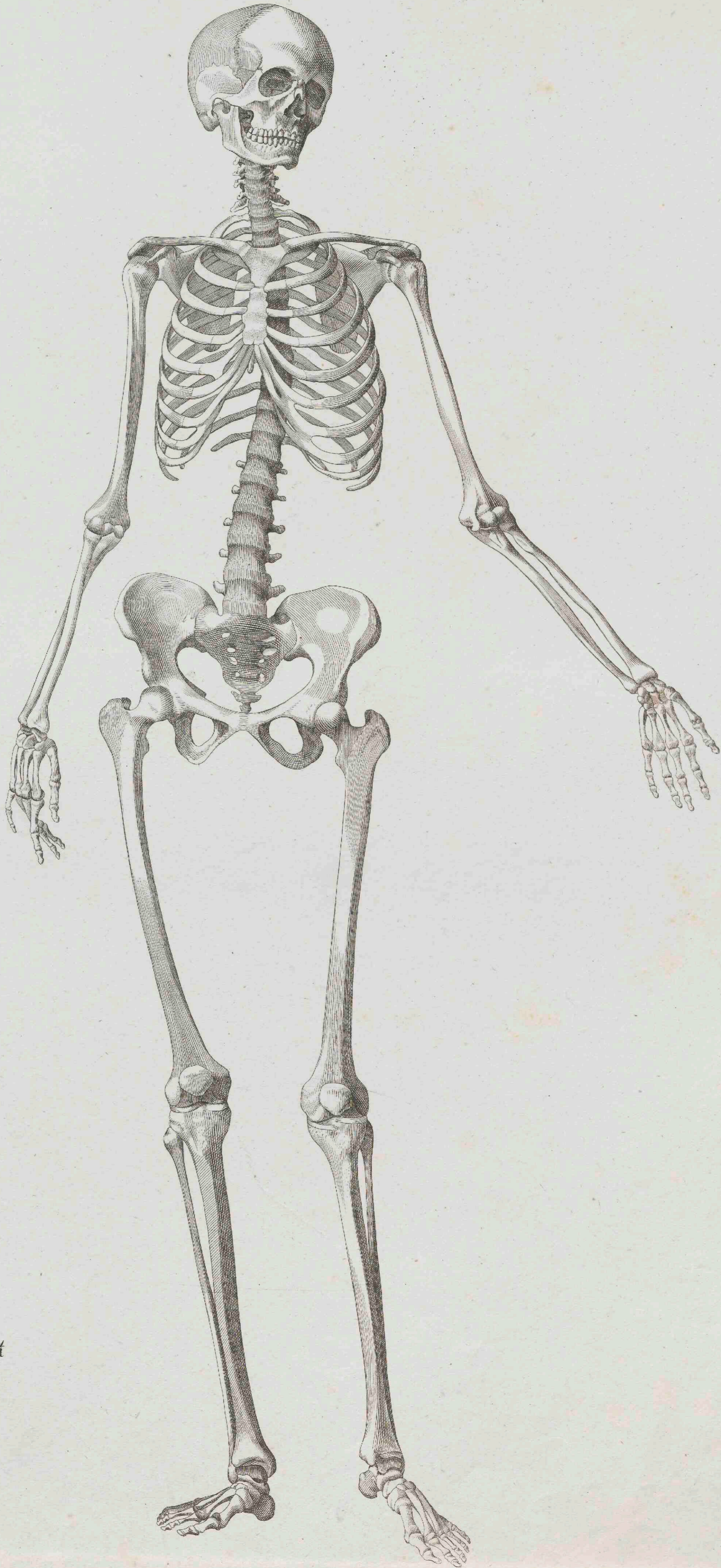
nach Weisse.



Maennliches Skelet.

nach Weisse.



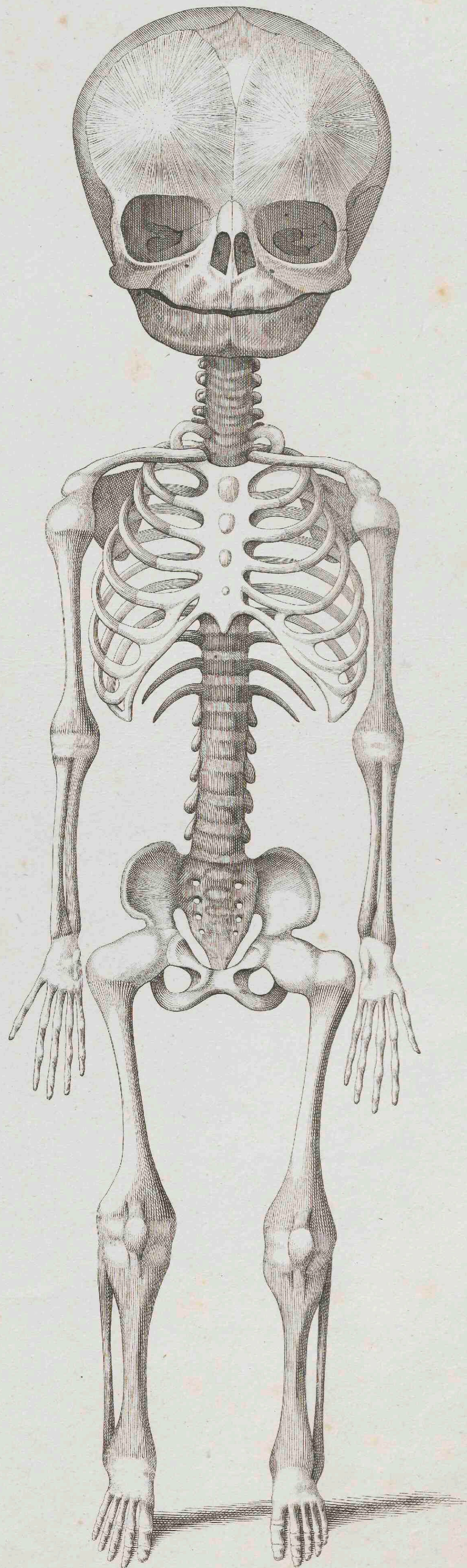
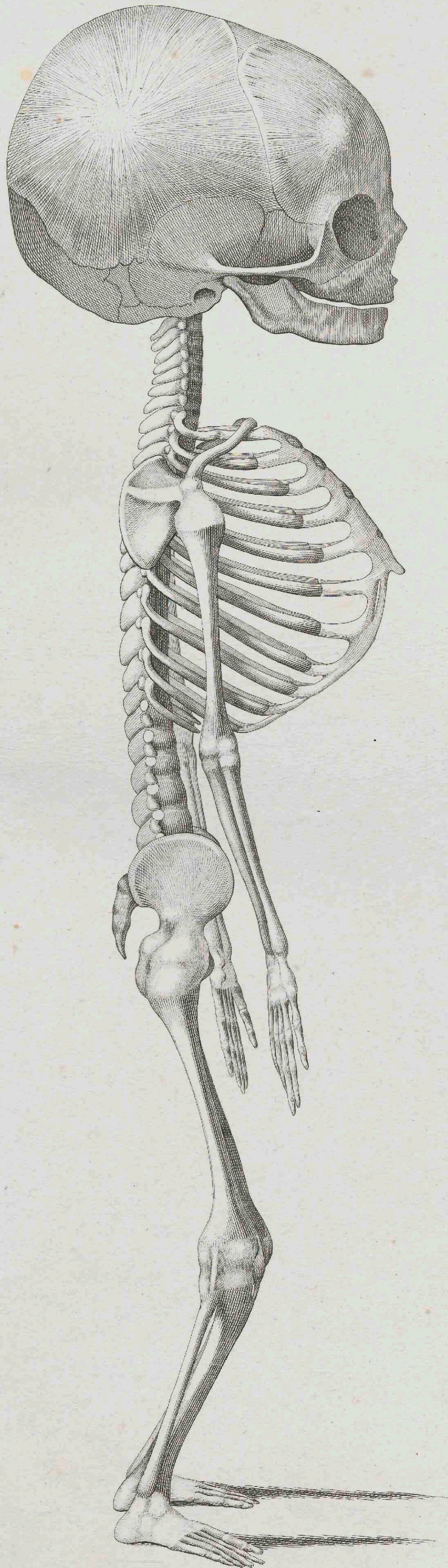


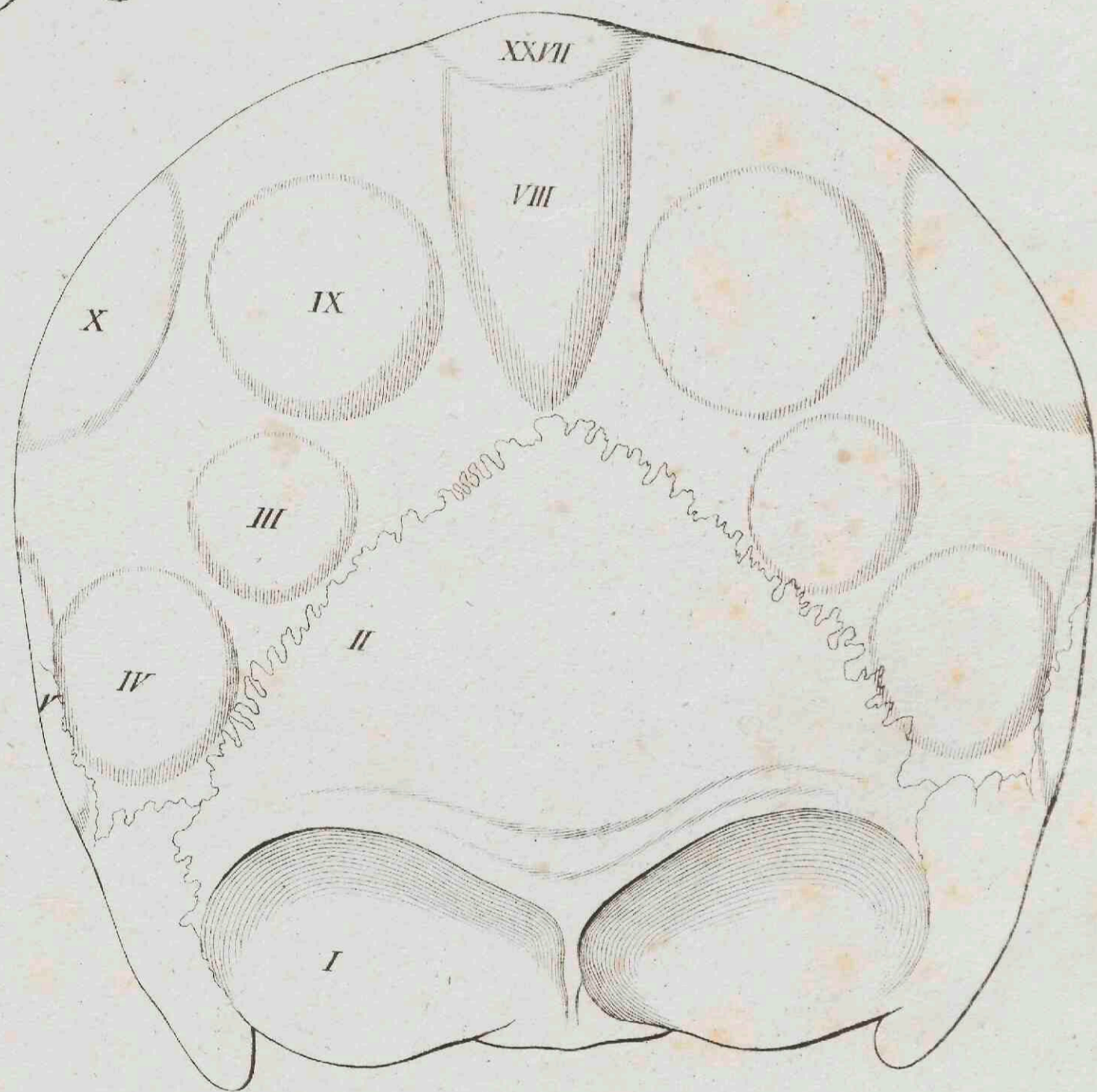
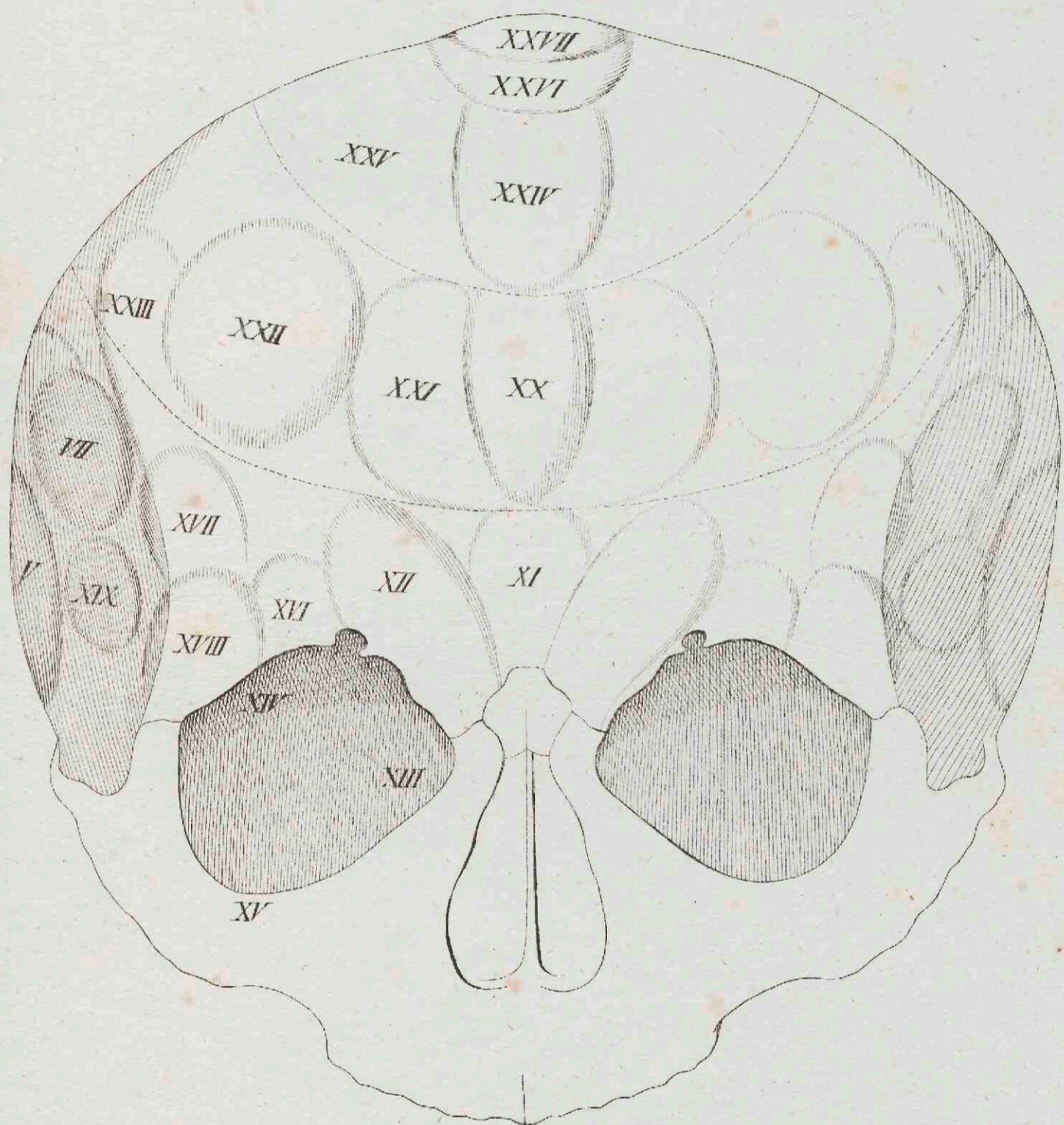
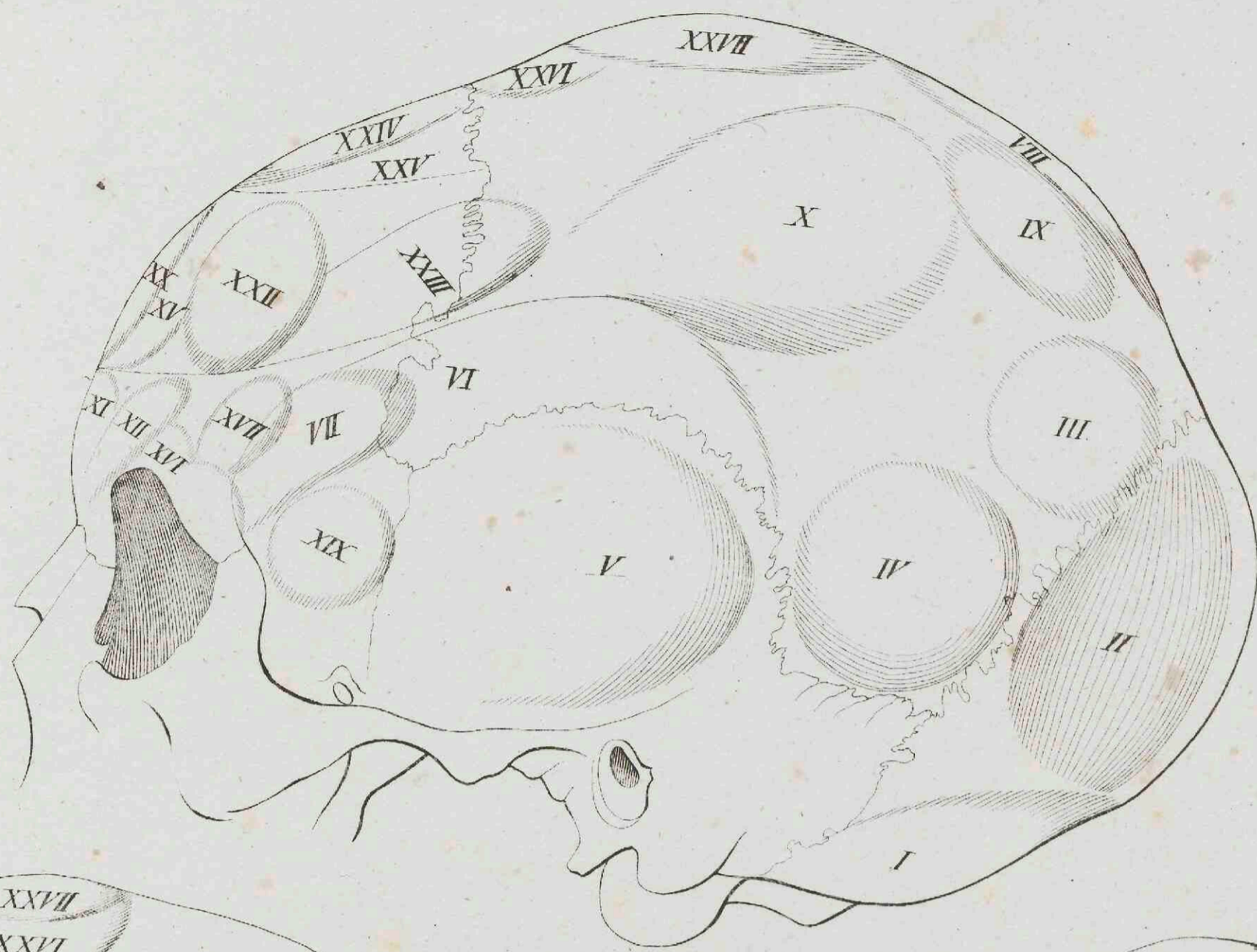
Weibliches Skelet

nach Soemmerring.

Reifes Kind,

nach Cloquet.





I Begattungstrieb.

II Kindesliebe.

III Freundschaftliche Anhänglichkeit.

IV Lebenserhaltungstrieb.

V Mordfucht.

VI Schlaueit.

VII Gewinnfucht. Diebsinn.

VIII Hochsinn.

IX Eitelheit. Sucht zu glänzen.

X Umsicht.

XI Sach -

XII Ort -

XIII Personen -

XIV Wort -

XV Sprach -

XVI Sinn für Malerei.

XVII — Musik.

XVIII Zahlengedächtniß.

Geschichte

XIX Sinn für Mechanik.

XX Vergleichender Scharfsinn.

XXI Tiefsinn.

XXII Witz.

XXIII Dichterisches Talent.

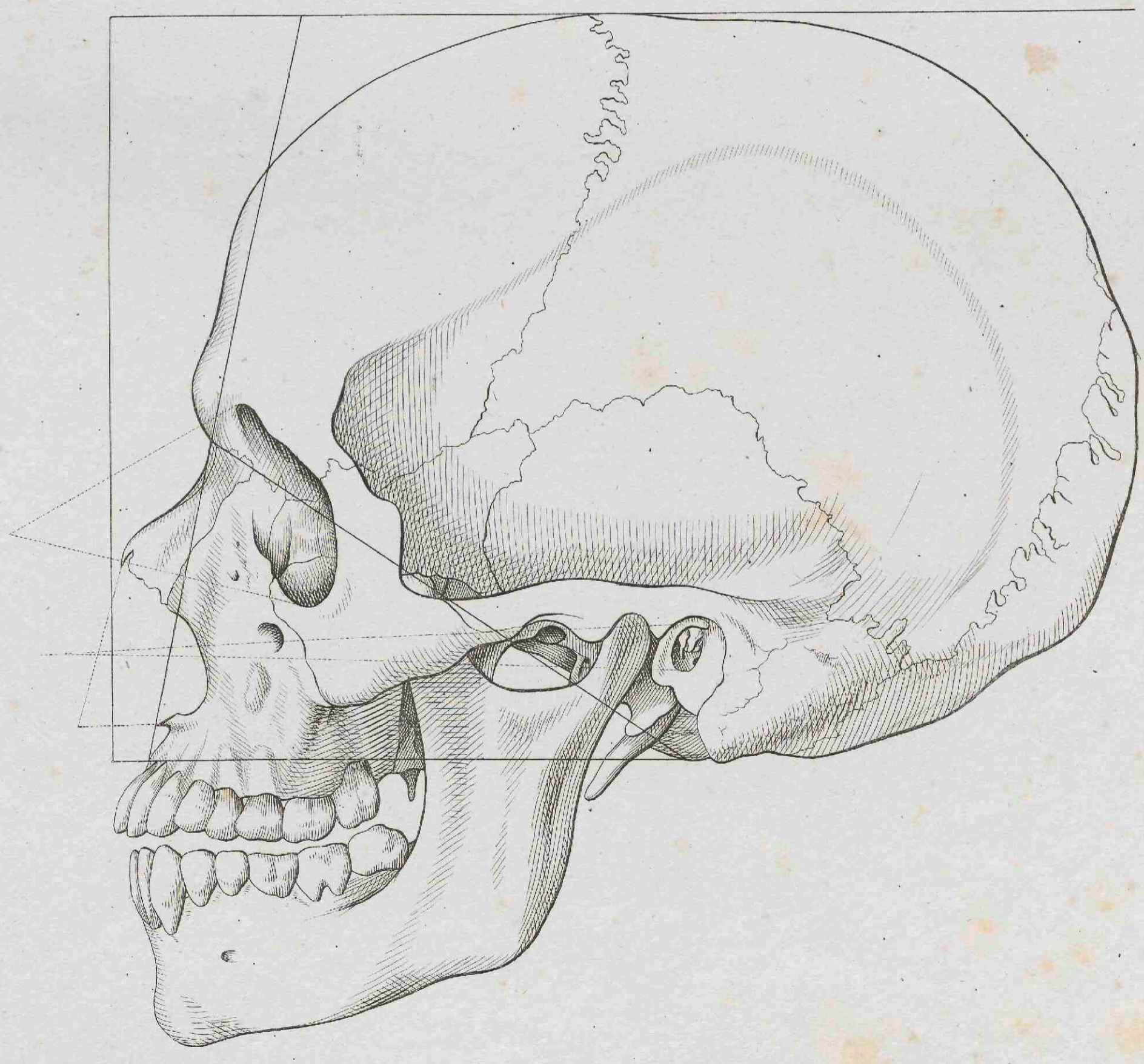
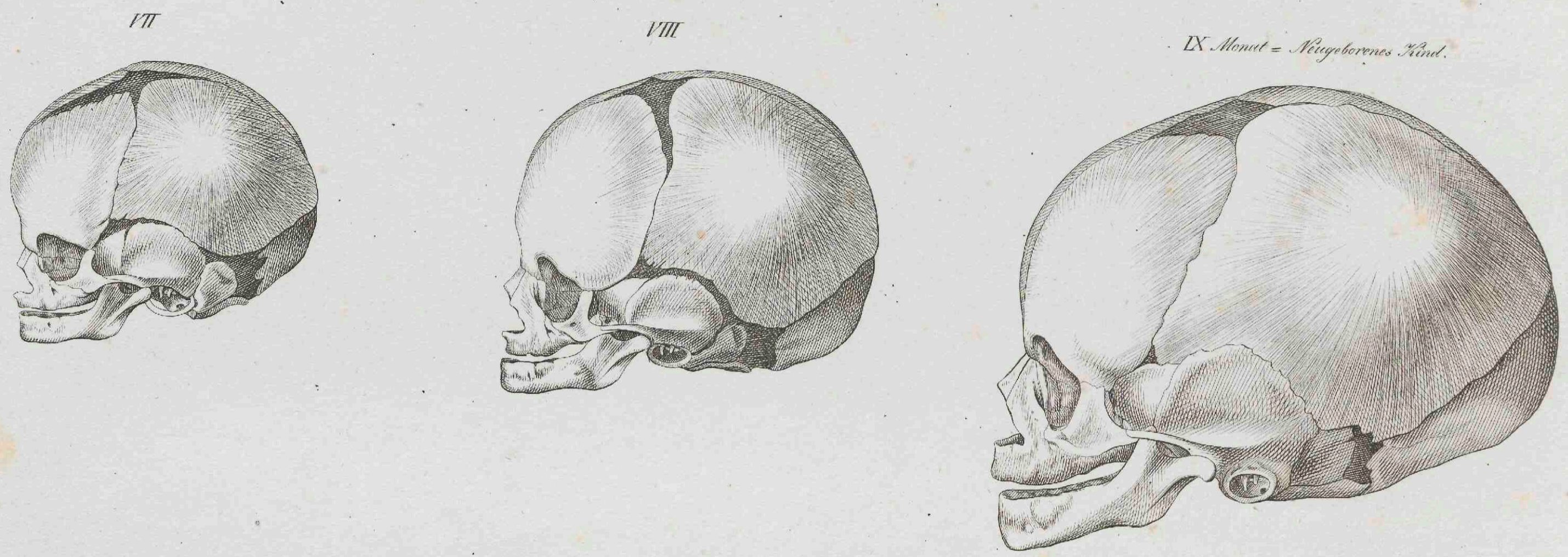
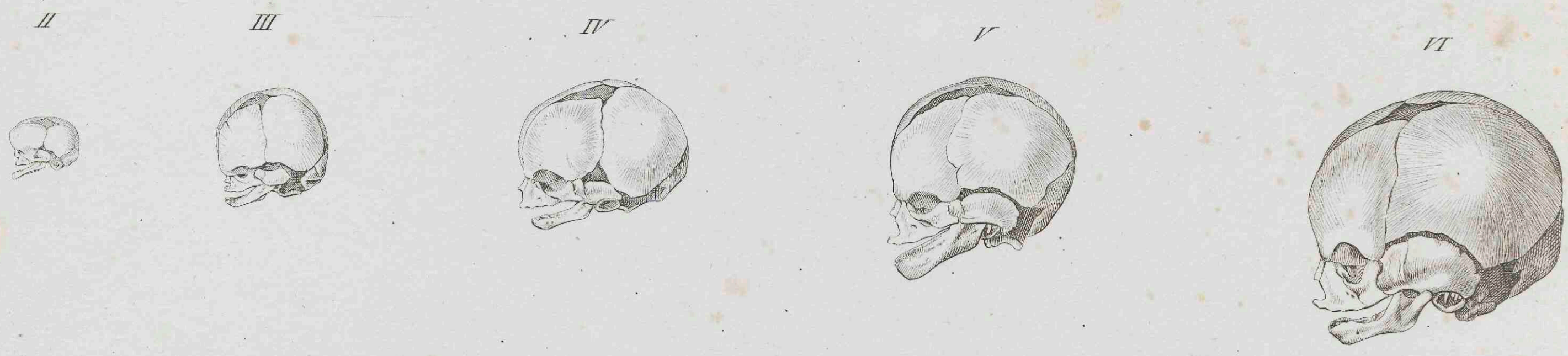
XXIV Gutmüthigkeit.

XXV Nachahmungstrieb.

XXVI Religiöser Sinn.

XXVII Beharrlichkeit.

Cephalogenesis, nach Spix.



OESTERREICHER'S

Anatomische Steinstücke.

Zweite Abtheilung

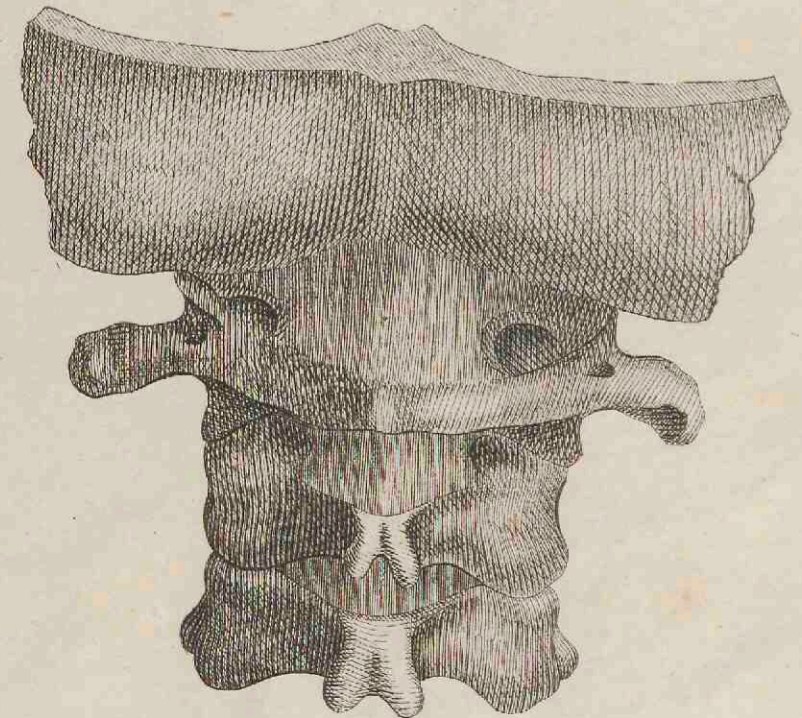
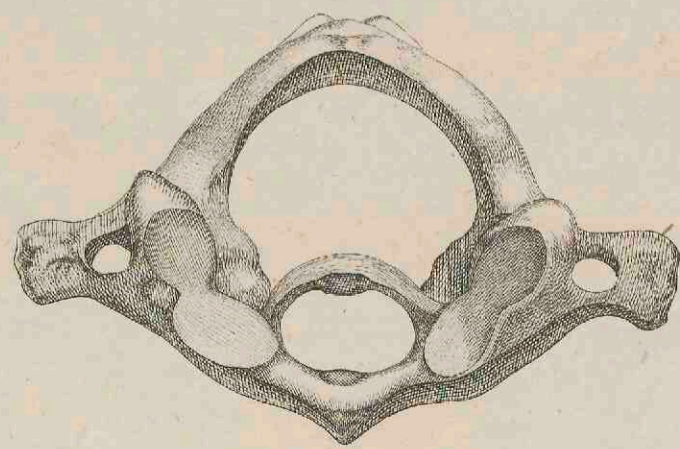
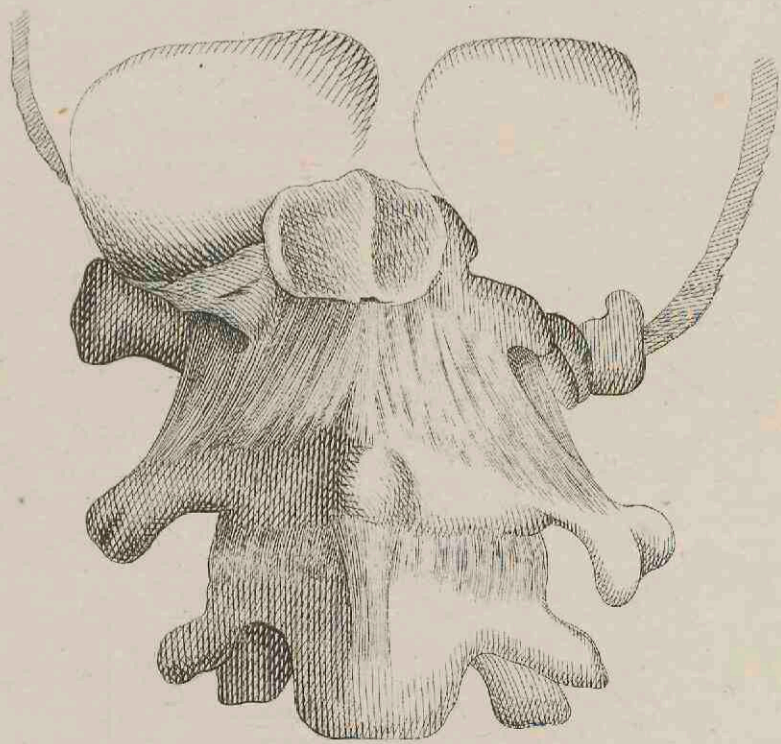
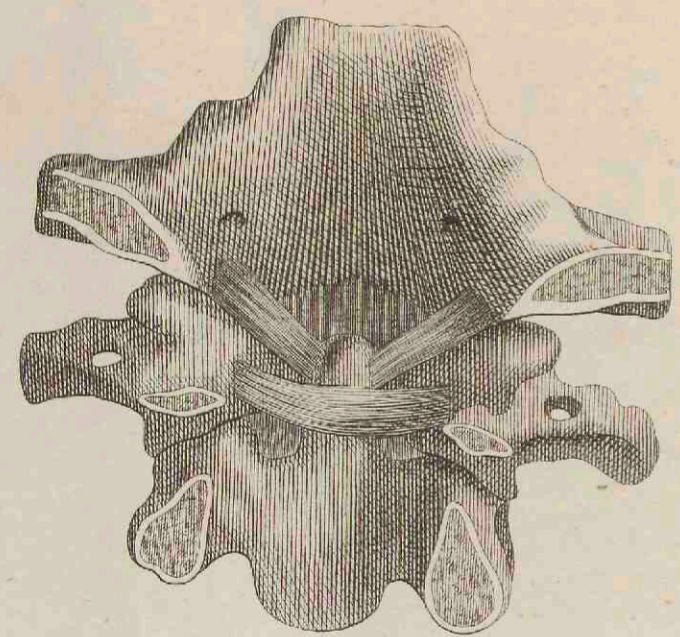
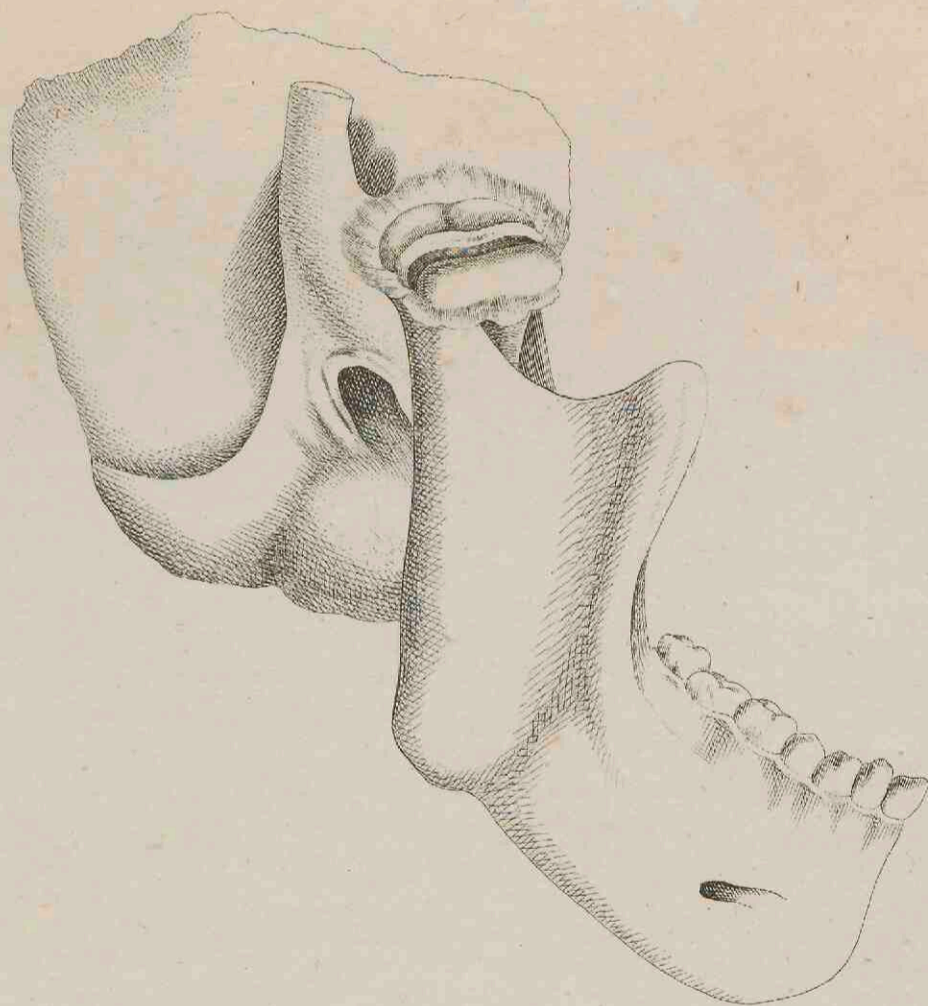
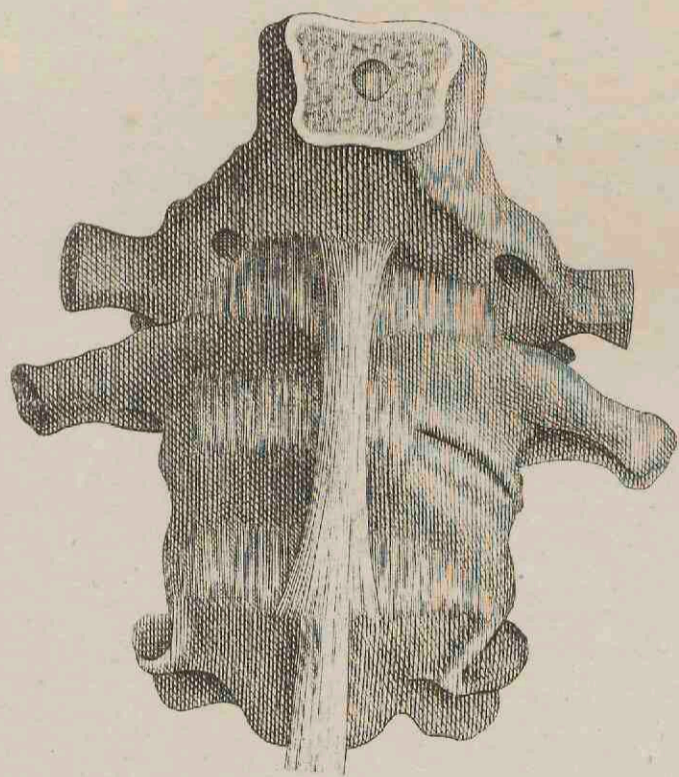
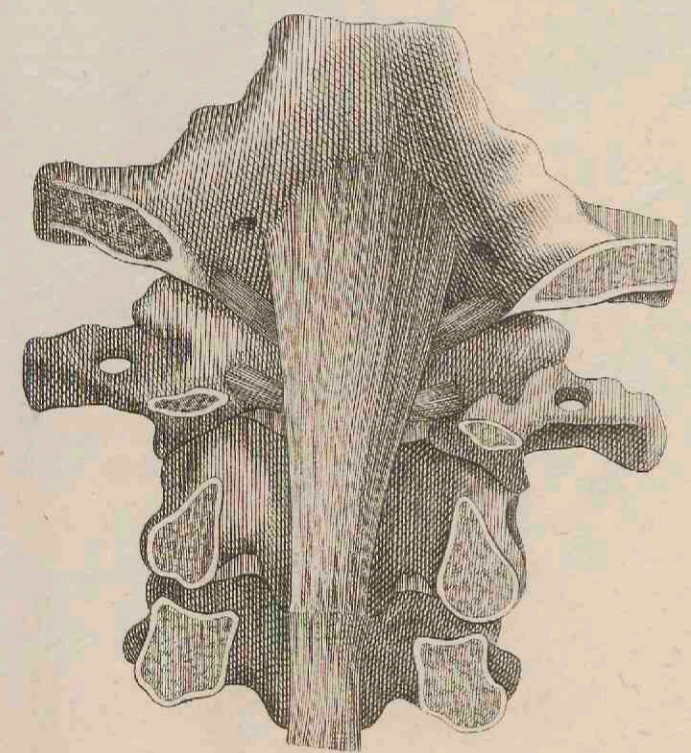
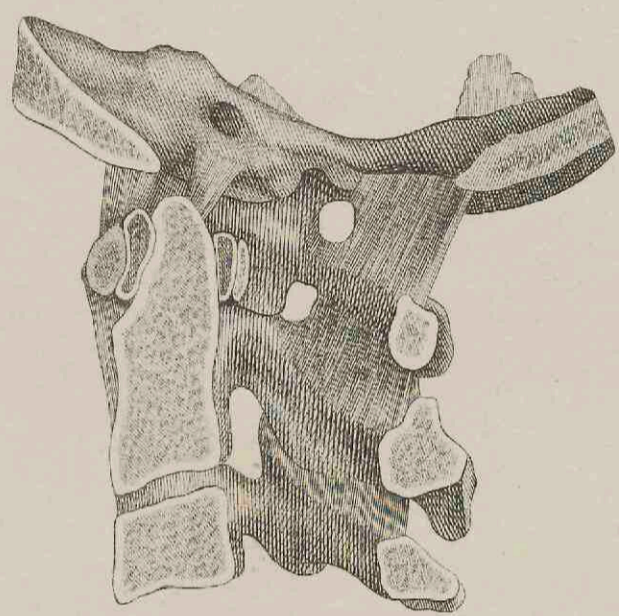
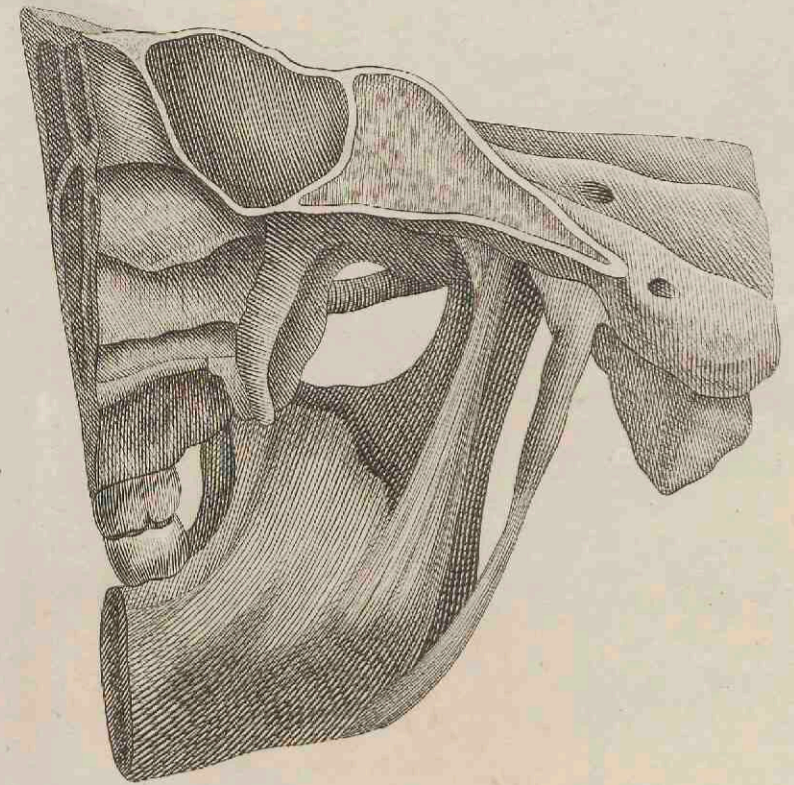
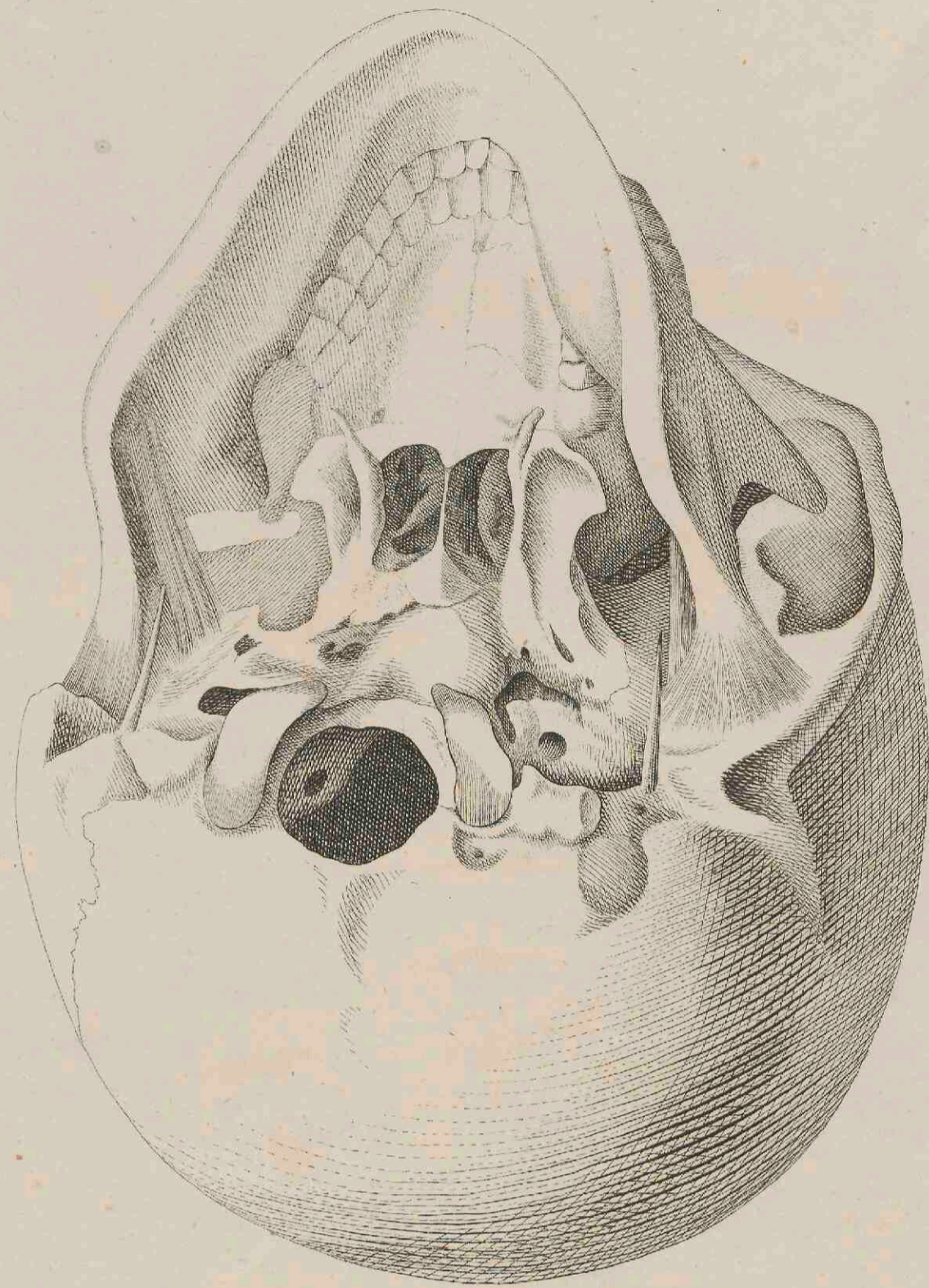
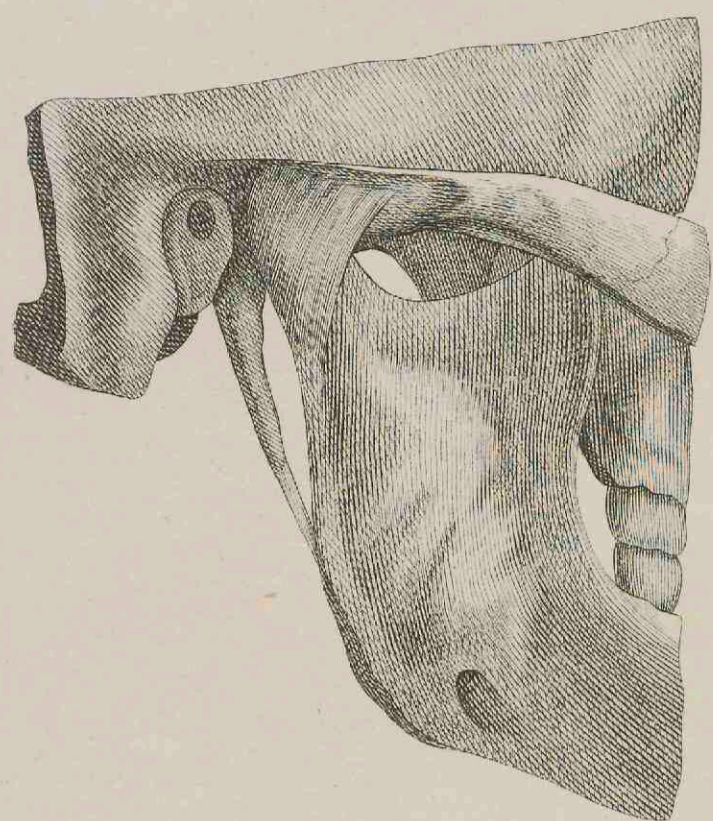
Bänder
des
Menschlichen Körpers.

München

1829

Bänder des Kopfes

nach Cloquet, Loschge, Scherer u. Weitbrecht



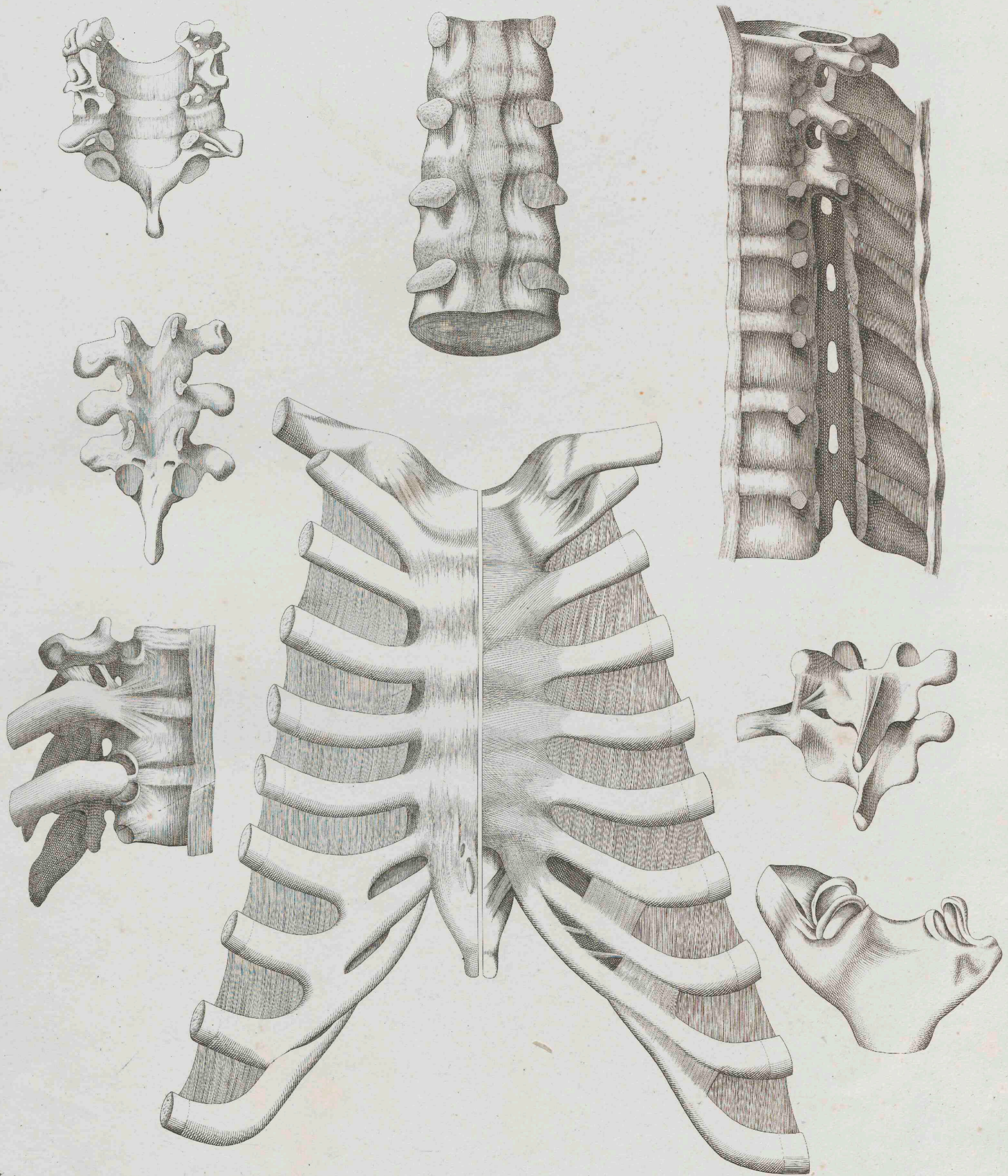
I Verbindung mit dem Unterkiefer: Kopfband / *lig. capsulare* / Zwischenkörper / *operculum cartilagineum* / Seitenband / *ligamentum laterale et stylohyaloideum*.

II ——— des Hinterhauptes mit der Wirbelsäule, und zwar

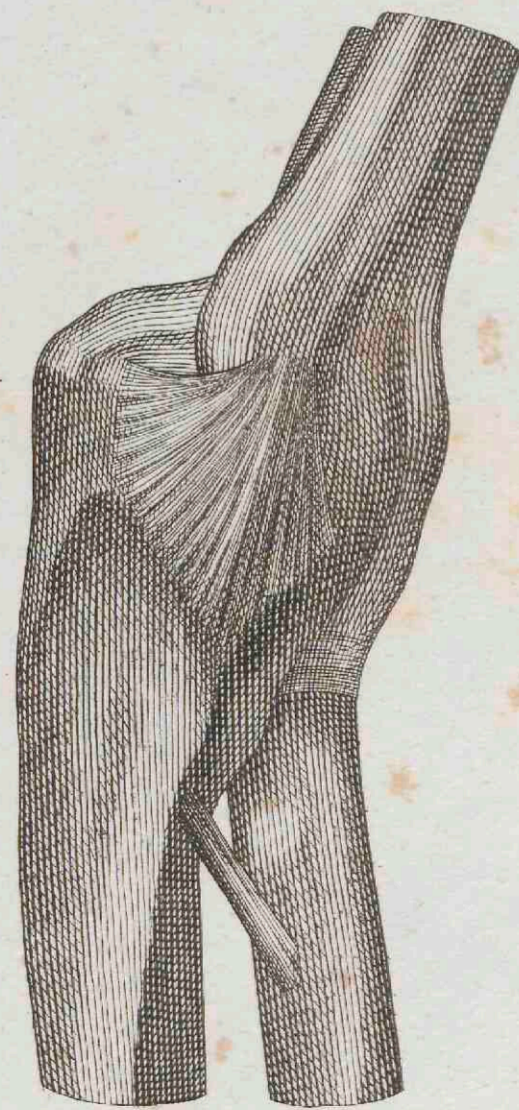
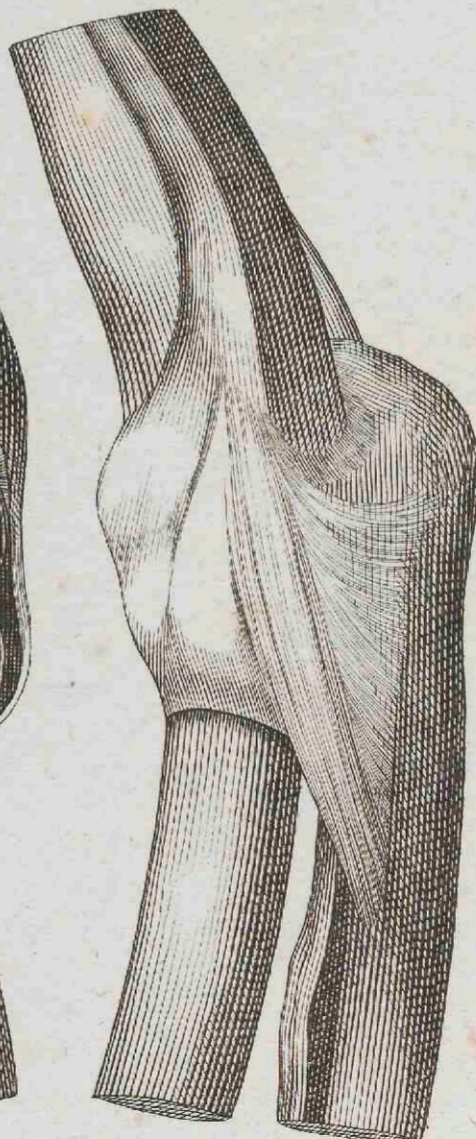
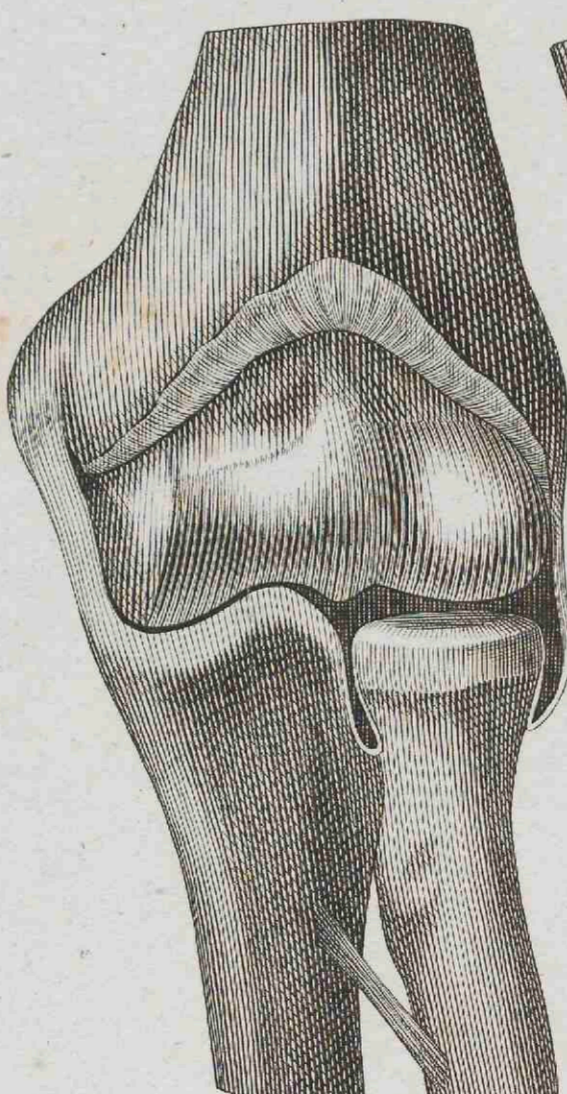
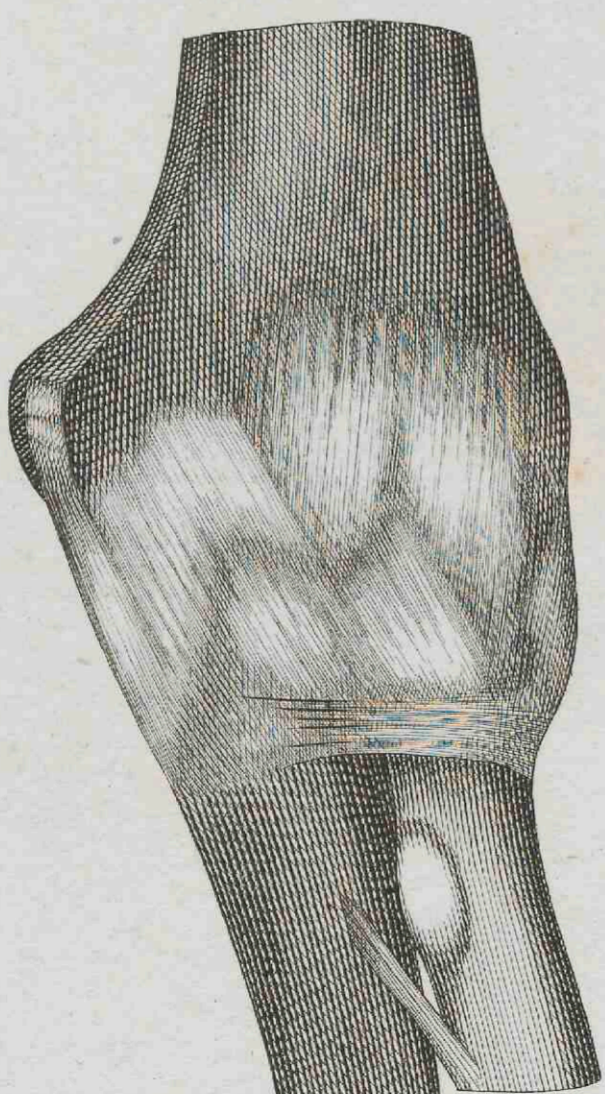
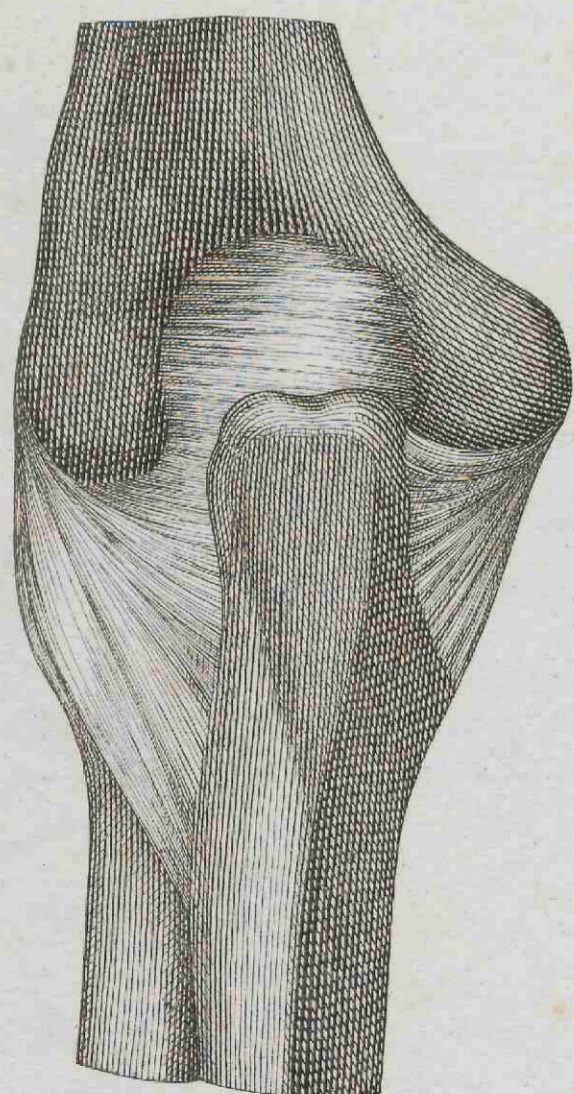
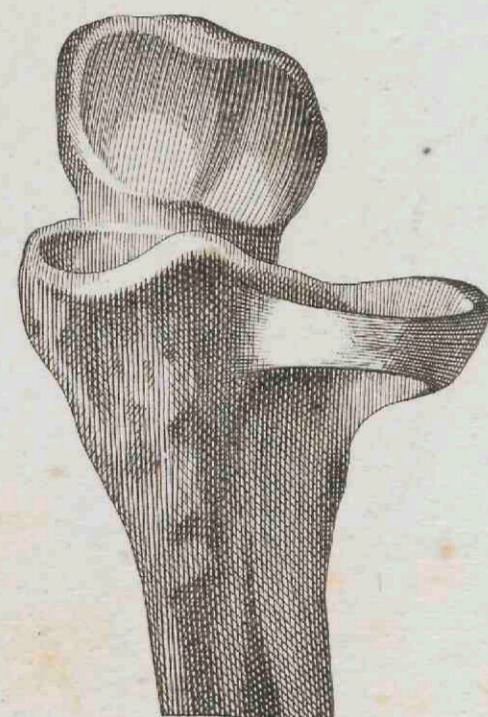
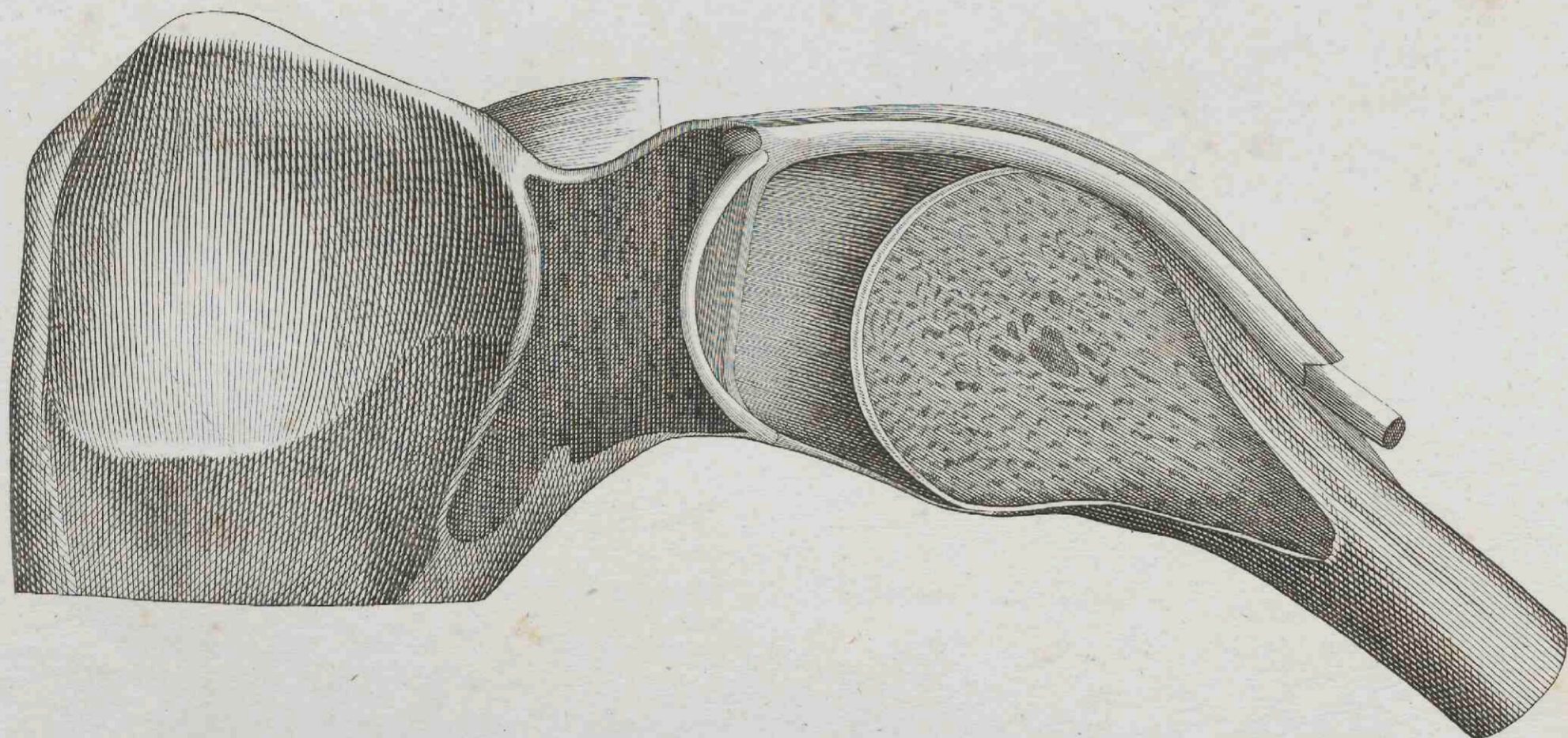
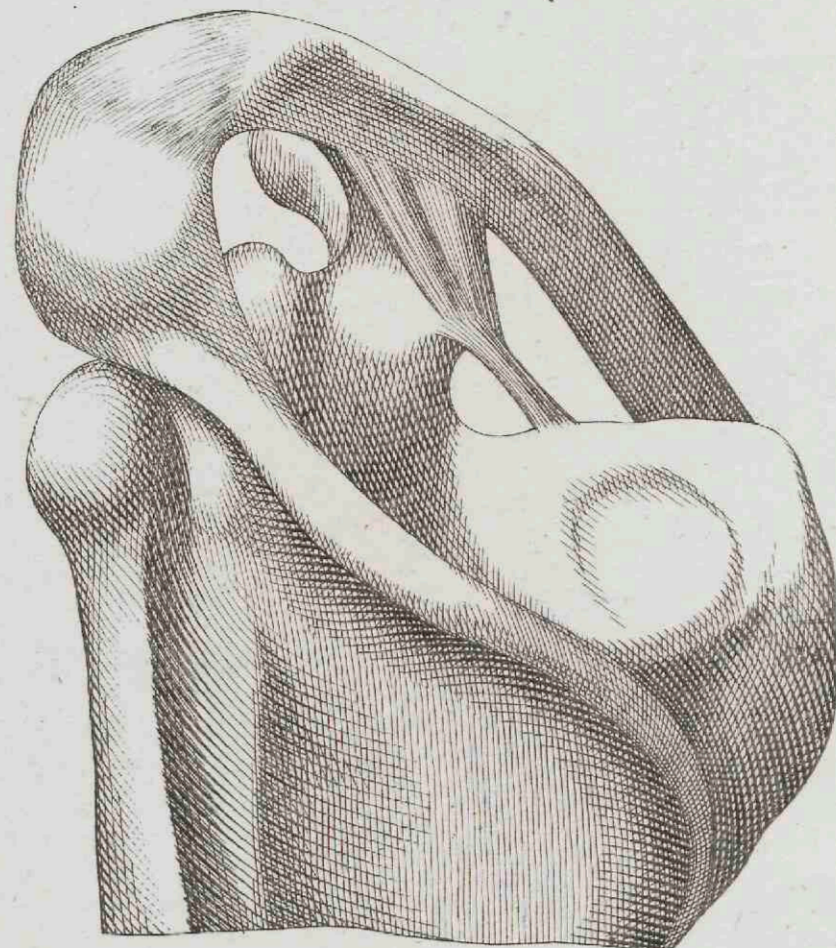
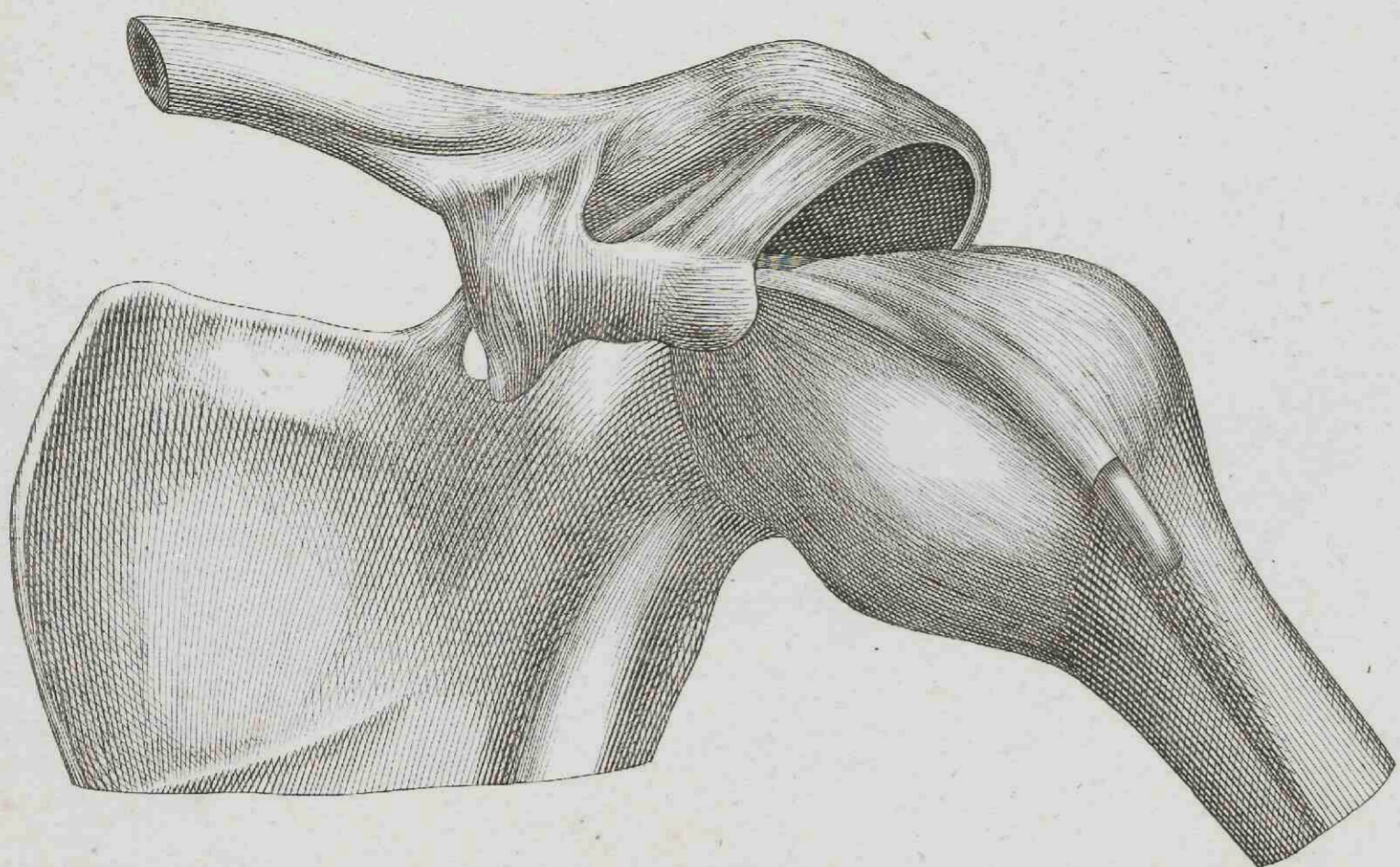
1. mit dem Träger Atlas / vorderes u. hinteres Ausfüll-Band / *Membrana annuli anterioris et posterioris Atlantis* / Gelenk-Kapsel- und Nebenbänder

2. — — Drehor, *Epistropheus* / gerades Band / *l. suspensorium s. rectum dentis* / Seitenbänder / *l. lateralia s. alaria Maucharti*

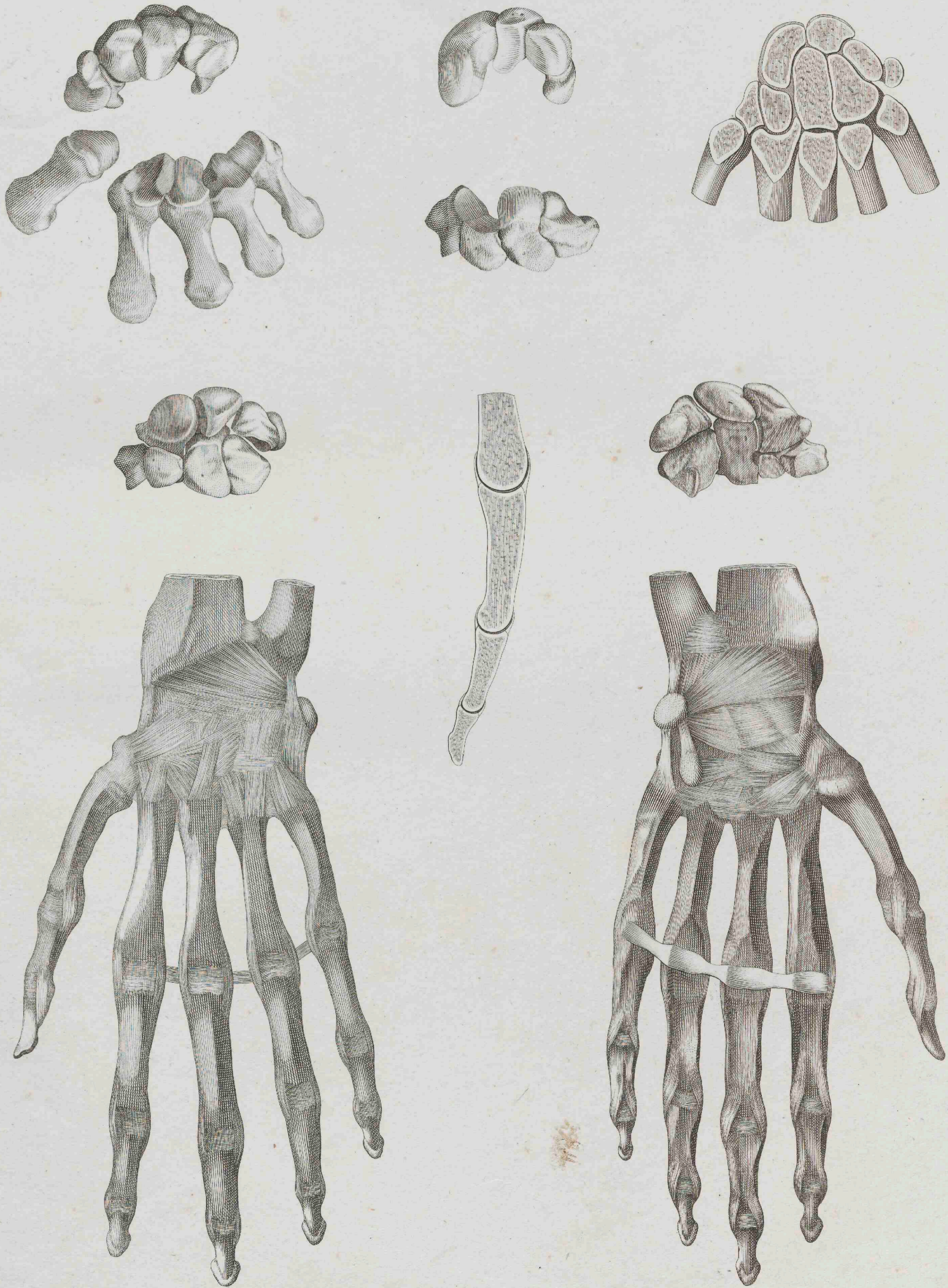
3. — — den Halswirbeln: nach vorne das kreuzförmige Band / *apparatus vertebrarum colli ligamentosus* / nach hinten das Nackenband / *l. nuchae s. cervicis*.



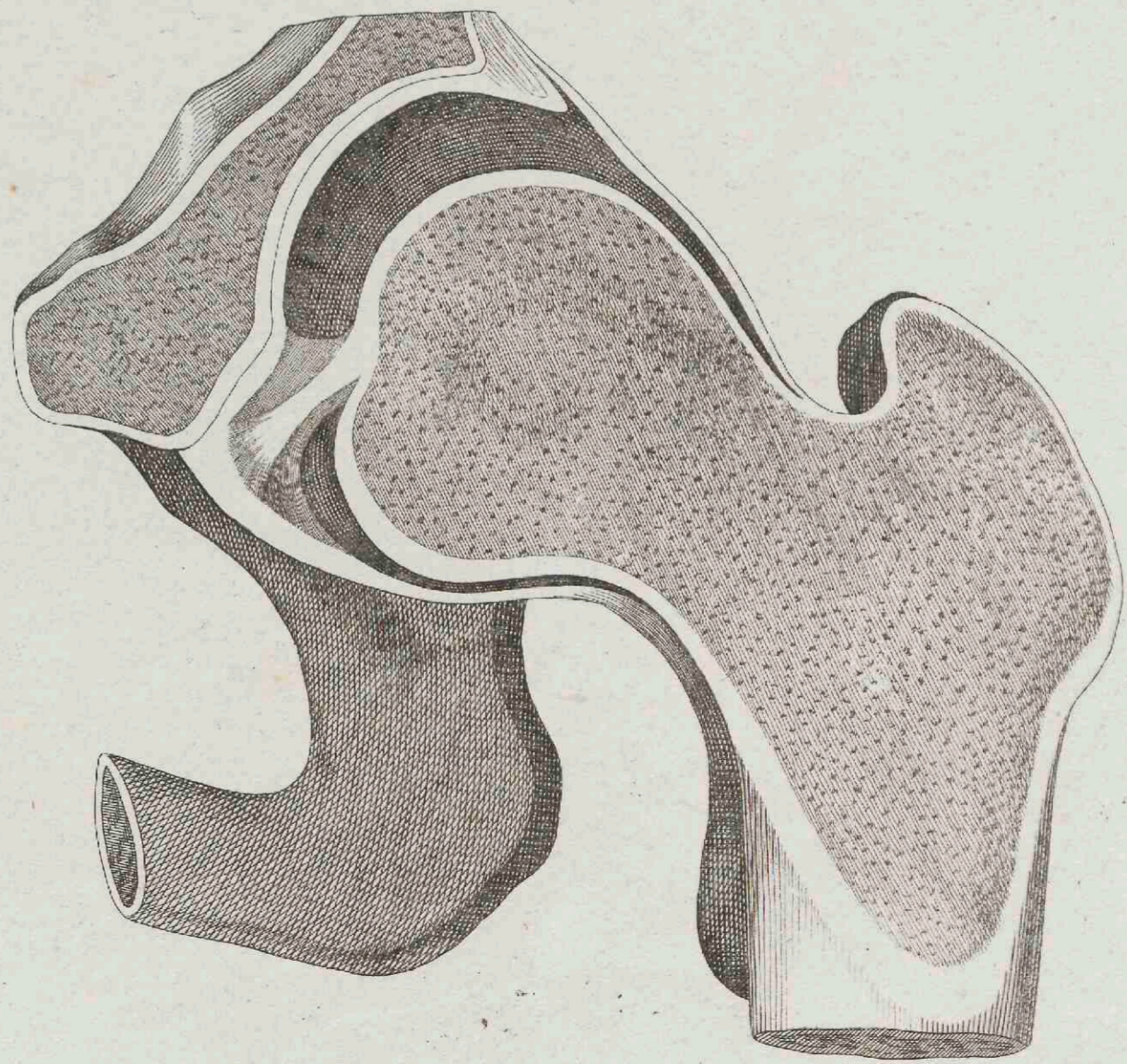
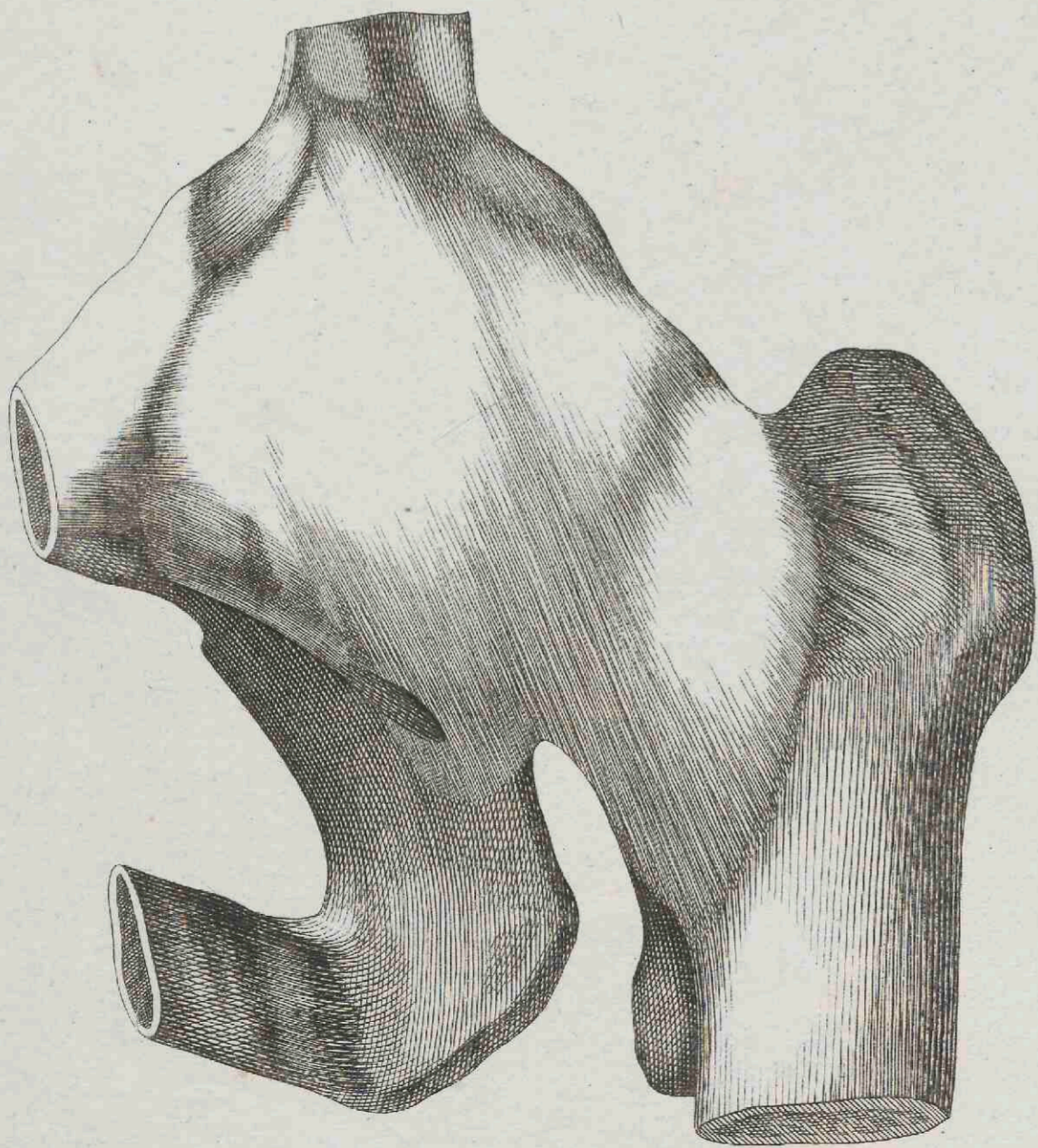
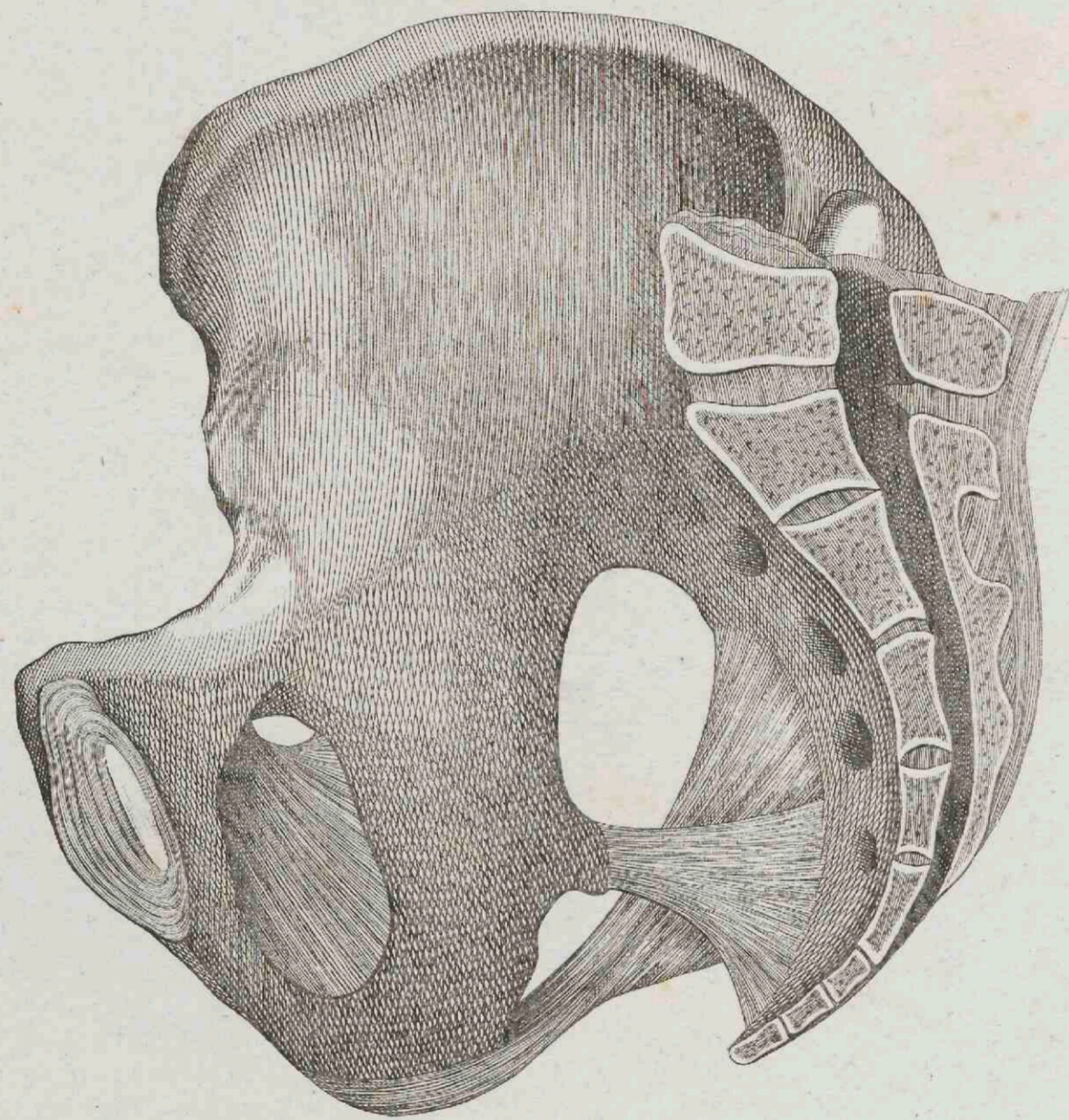
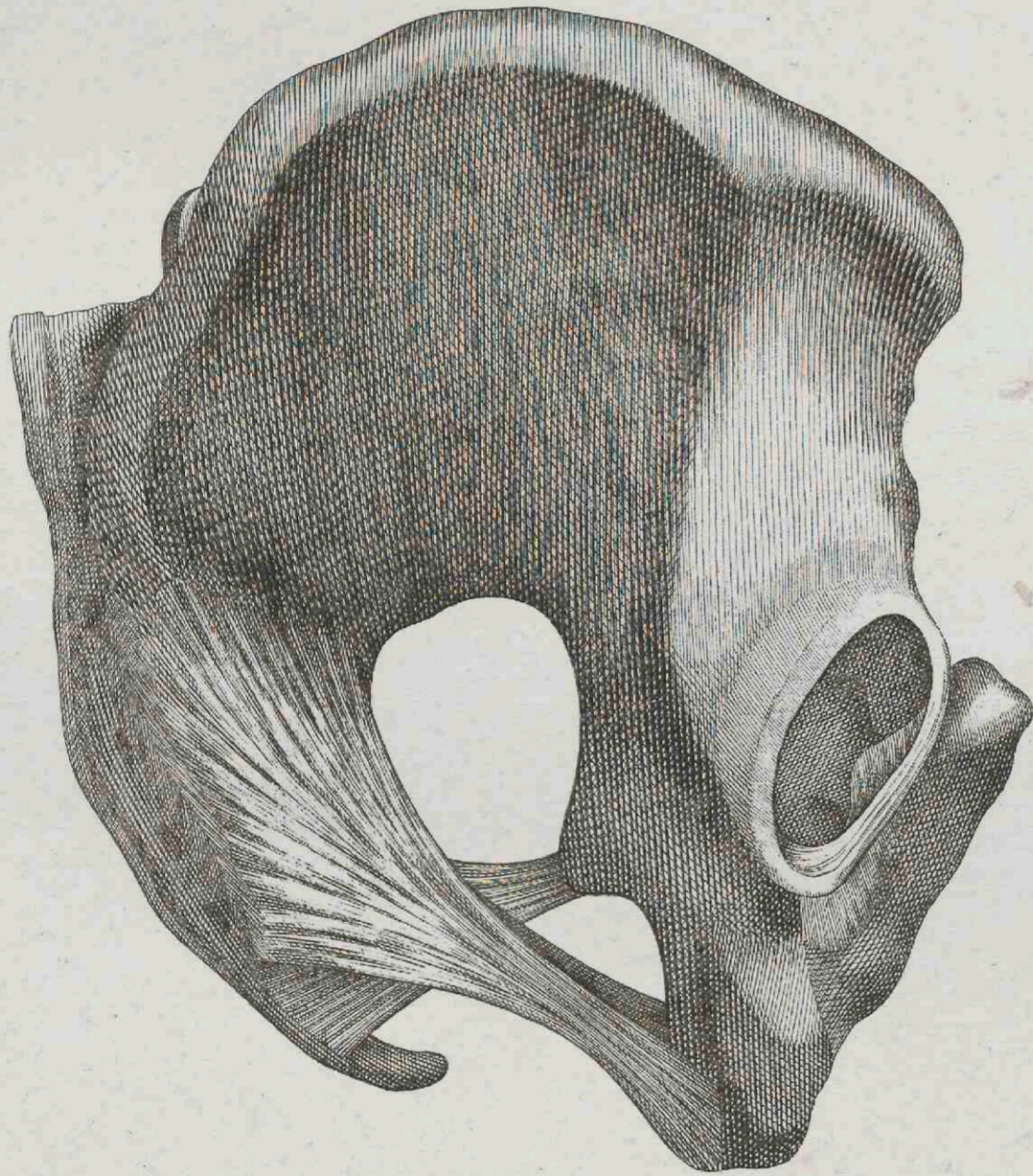
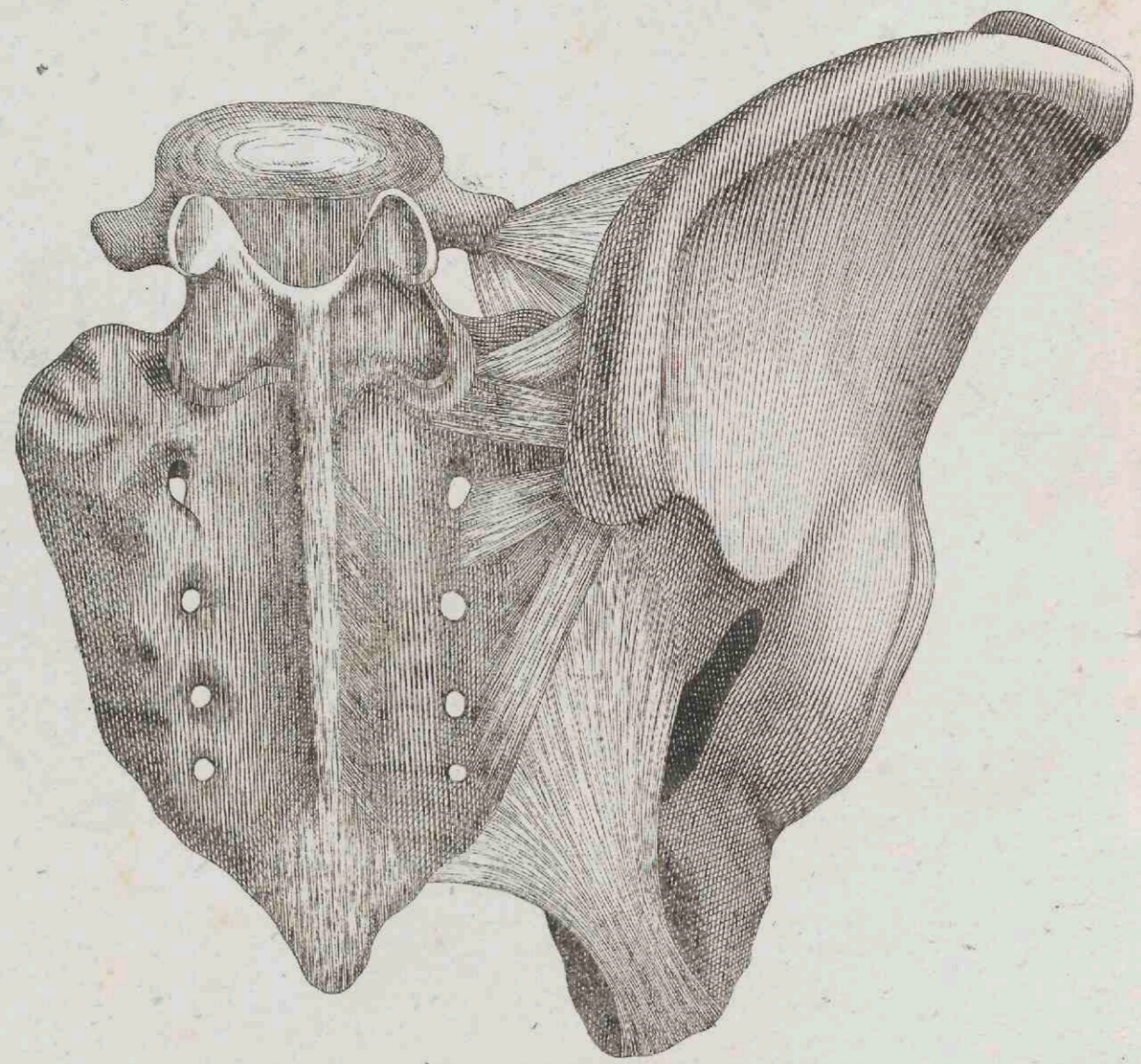
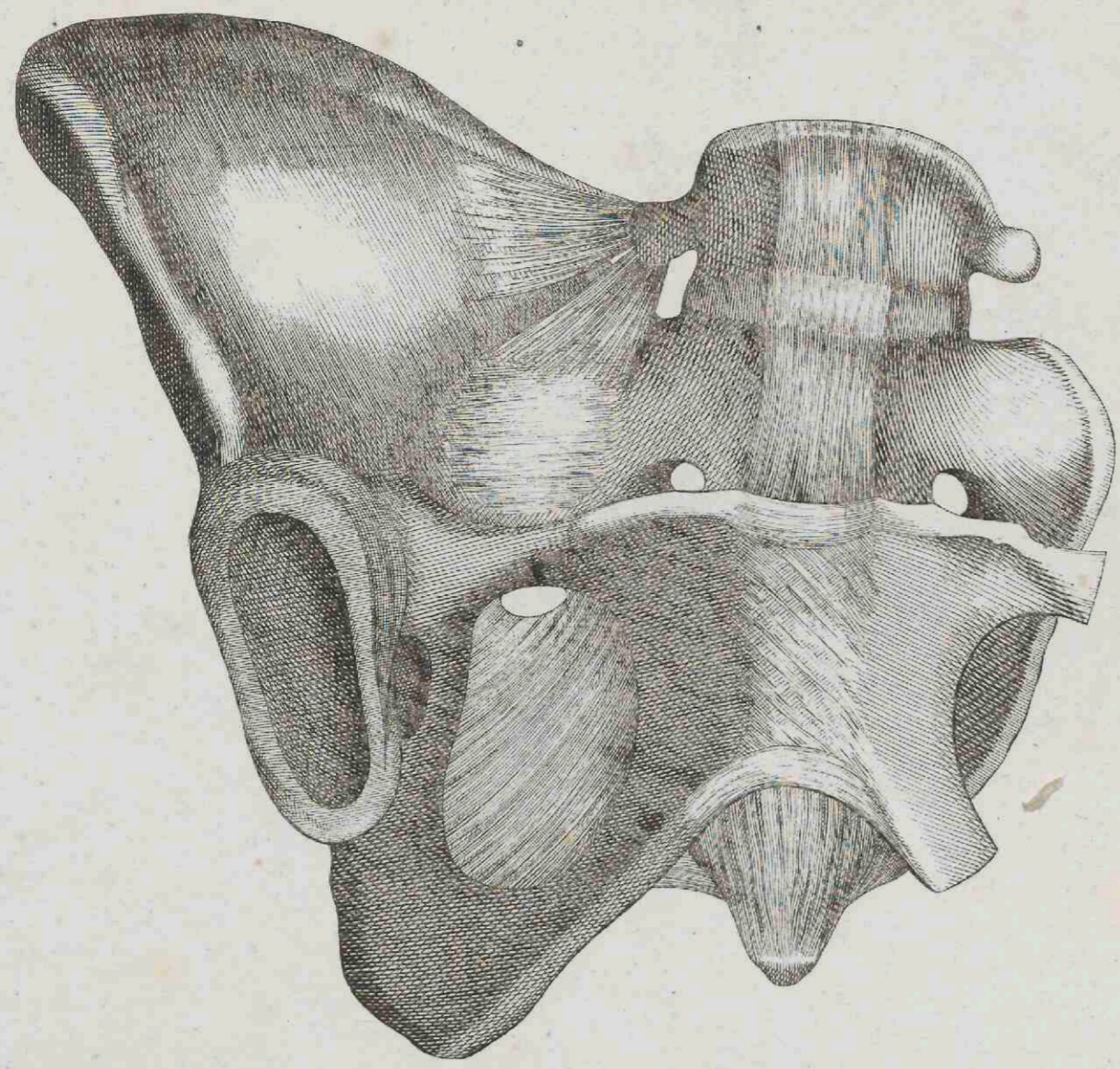
Wirbelbaender: I an den Körpern: Zwischenkörperbaender / *lig. intervertebralia* / vordere Binde / *fascia longitudinalis anterior* / hintere Binde / *f. posterior* /
 II an den Bögen: gelbliche / *subflava* / gerade Querfortsatzb. / *intertransversaria* / Zwischenleerhäute / *interspinalia* / Spitzgeb. / *apicum* / Kapselb. / *capsularia* /
 Rippenbaender: das hintere Stück jeder Rippe verbindet sich mit den Wirbeln durch ein Gelenk / *l. capsulare* / Querband / *transversarium* / inneres / *l. colli costae internum* / und äußeres
 Rippenhalbband, wozu auch wohl noch kleine Nebenbaender kommen; das vordere Stück aber wird durch ein Kapselband an den Rippenknorpel, der Knorpel aber durch das
 Strahlenband / *l. radiatum* / an das Brustbein, oder durch Gelenk- und Faserbaender an die vortretenden Knorpel befestigt.
 Die Stücke des Brustbeins werden durch die Knochenhaut / *membrana propria sterni* / zusammengehalten, der Schwerfortsatz insbesondere aber durch eigene Bänder / *l. proc. xiphoidi* / befestigt.
 Bänder des Schlüsselbeins: Kapselband mit Zwischengelenkknorpel / *meniscus* / Zwischen Schlüsselbeinband / *l. interclaviculare* / rautenförmiges Band / *l. rhomboidium* /



Bänder des Schultergelenkes: I Zwischen Schulterblatt u. Schlüsselbein ist das Gräten Schlüsselband (*l. acromio-claviculare*) u. das Nachgräten Schlüsselband (*coraco-claviculare*), dessen inneren Bündel man auch kegelförmiges, den äußeren aber ungleich vierköpfiges Band nennt. II Eigene Bänder des Schulterblattes sind das Nachgrätenband (*coraco-acromiale*) u. das Nacharmband (*coracoideum s. trigonum*). III Das Clavergelenk hat ein großes Kapselband. — Bänder des Ellenbogengelenkes: Die Synovialkapsel wird durch Faserbündel verstärkt, die man als eigene Bänder betrachtet (*l. brachio-cubitale s. radiale*). Außerdem finden sich an den Vorderarmknochen für die Flexion u. Supination noch das Ringband (*l. annulare*), runde (*l. teres*) u. Zwischenknochenband (*l. interosseum*). —

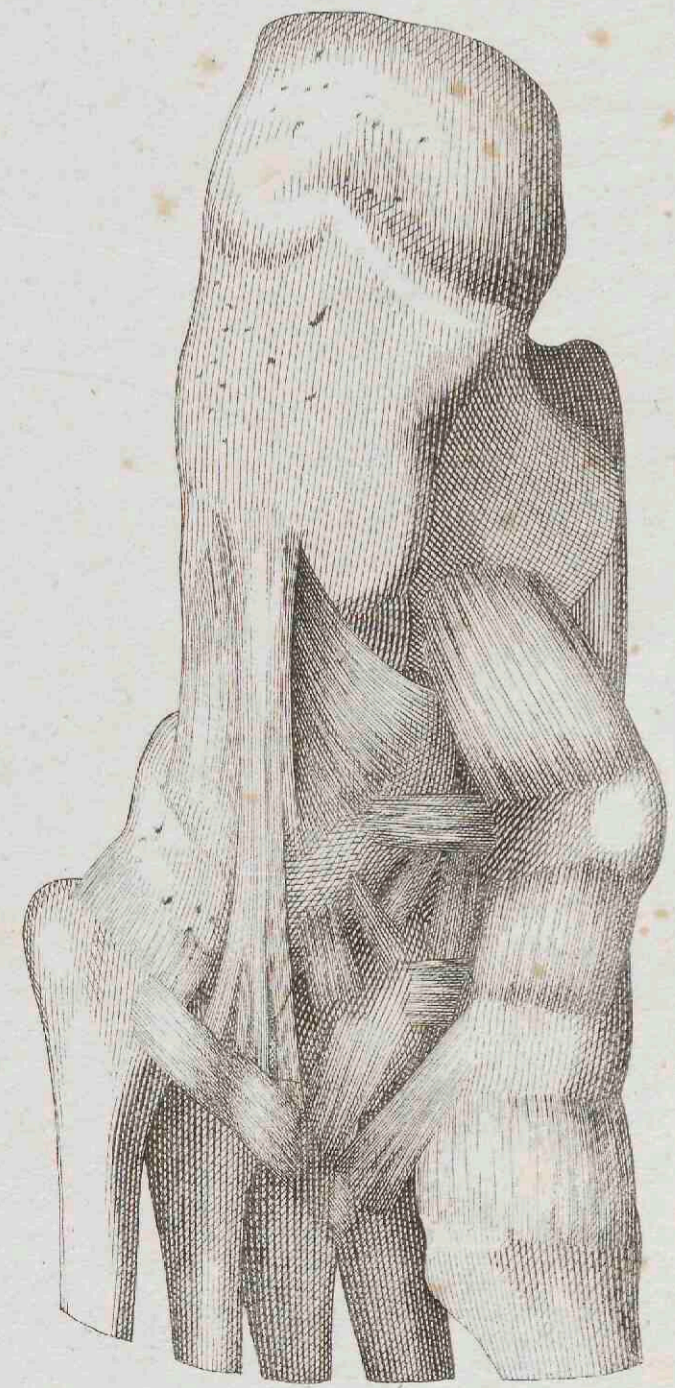
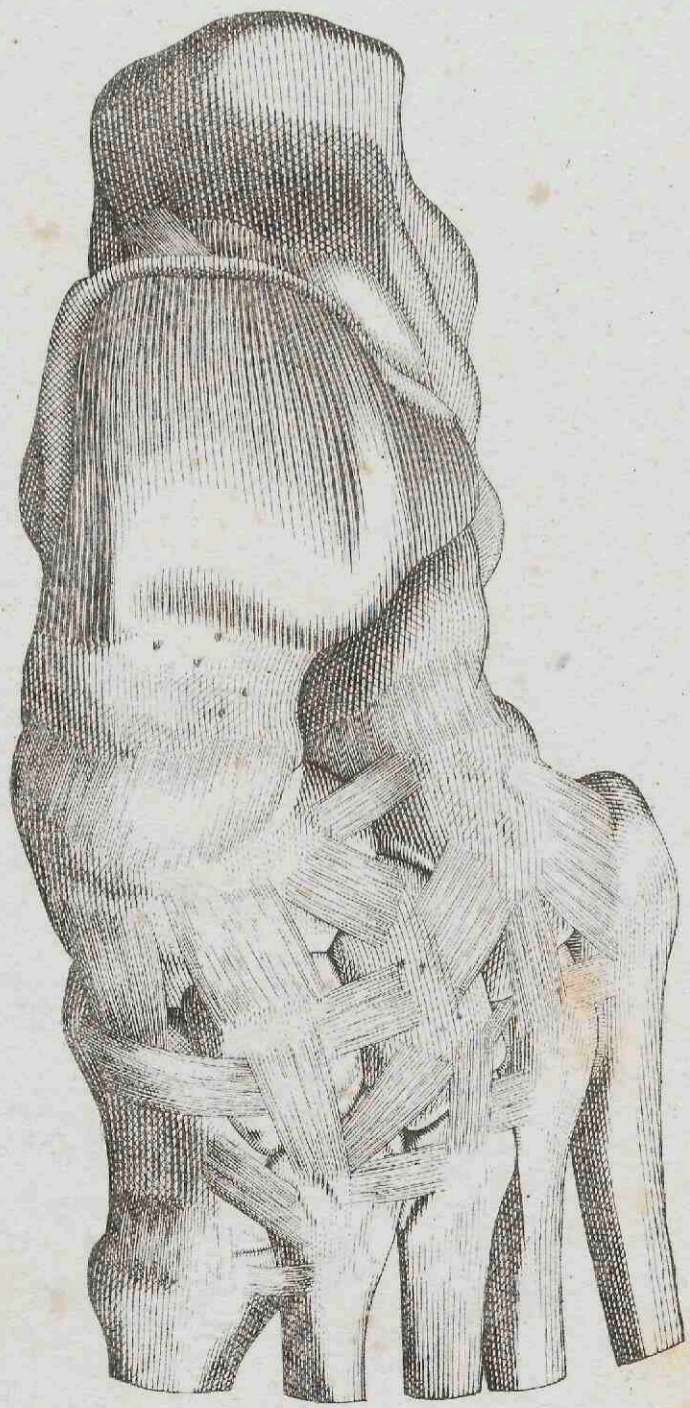
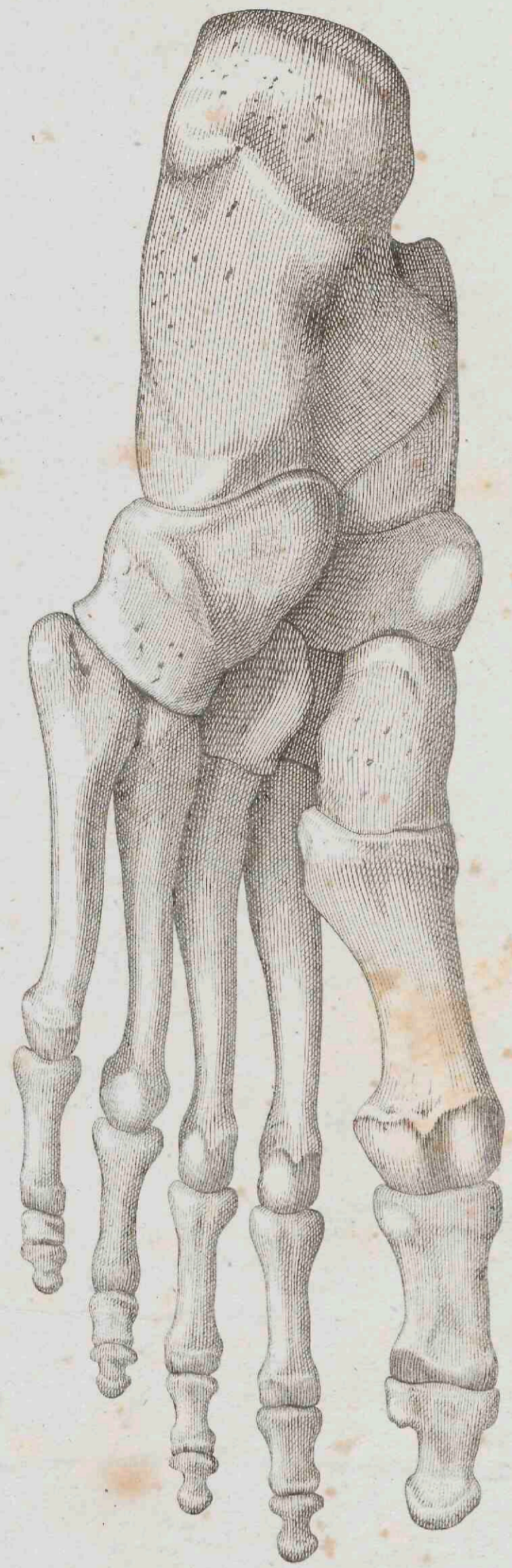
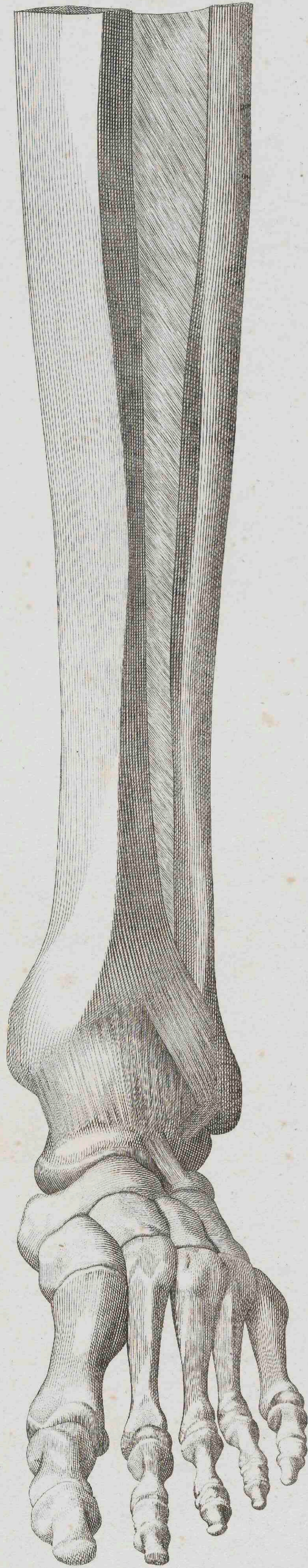
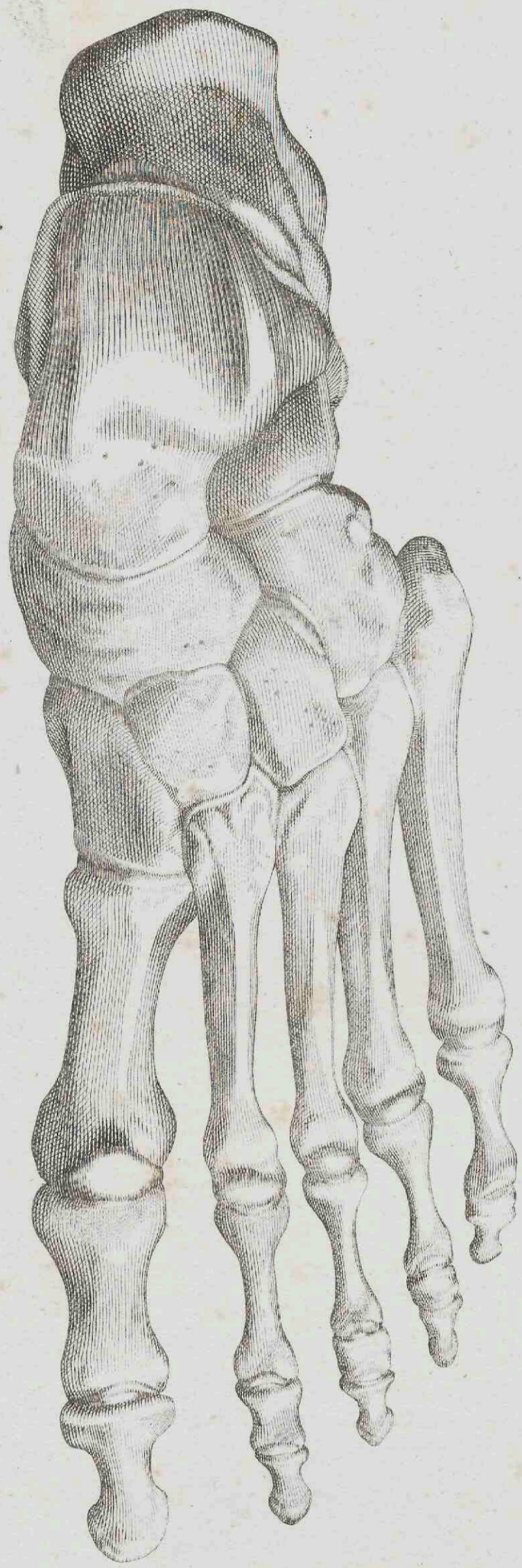


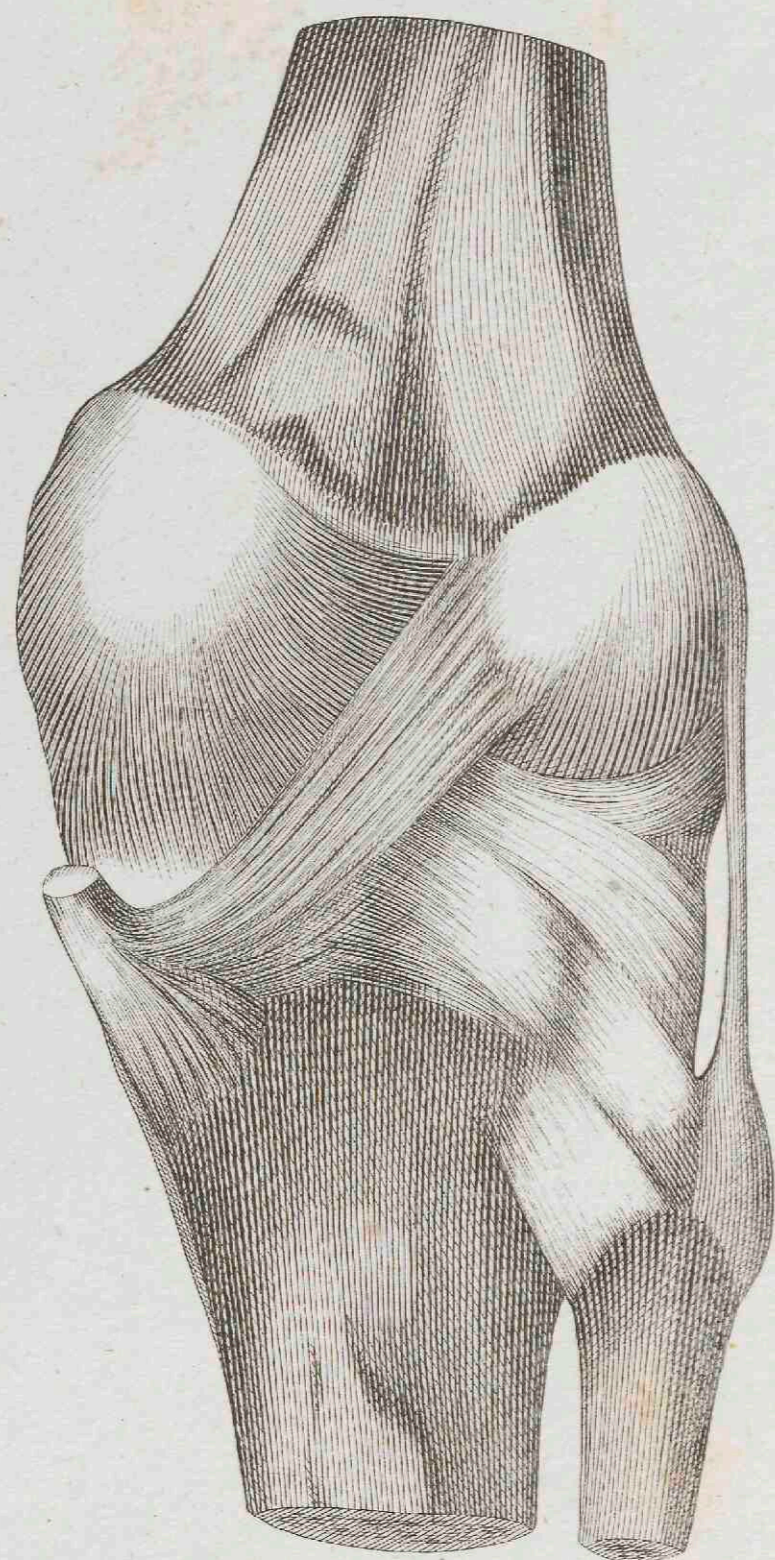
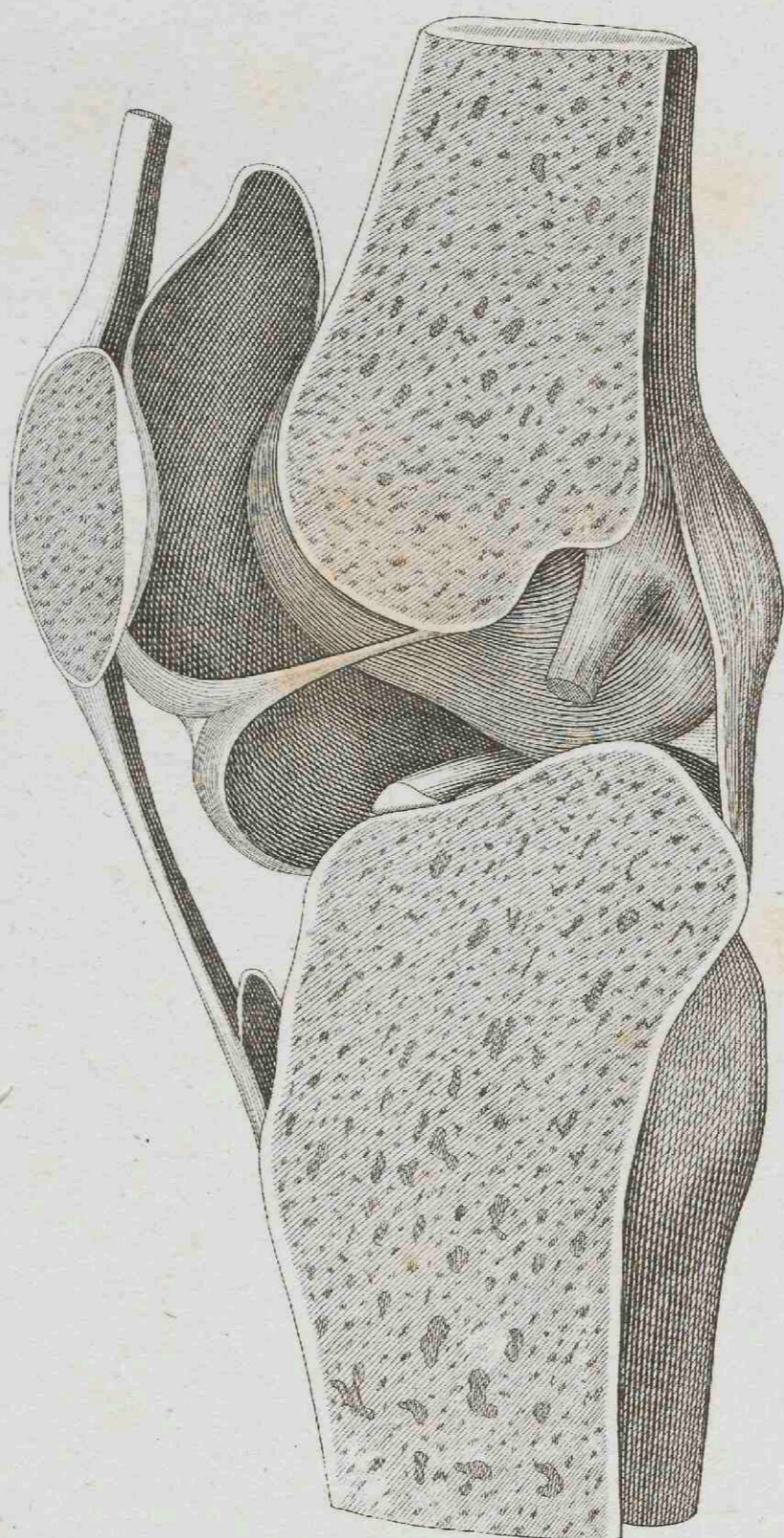
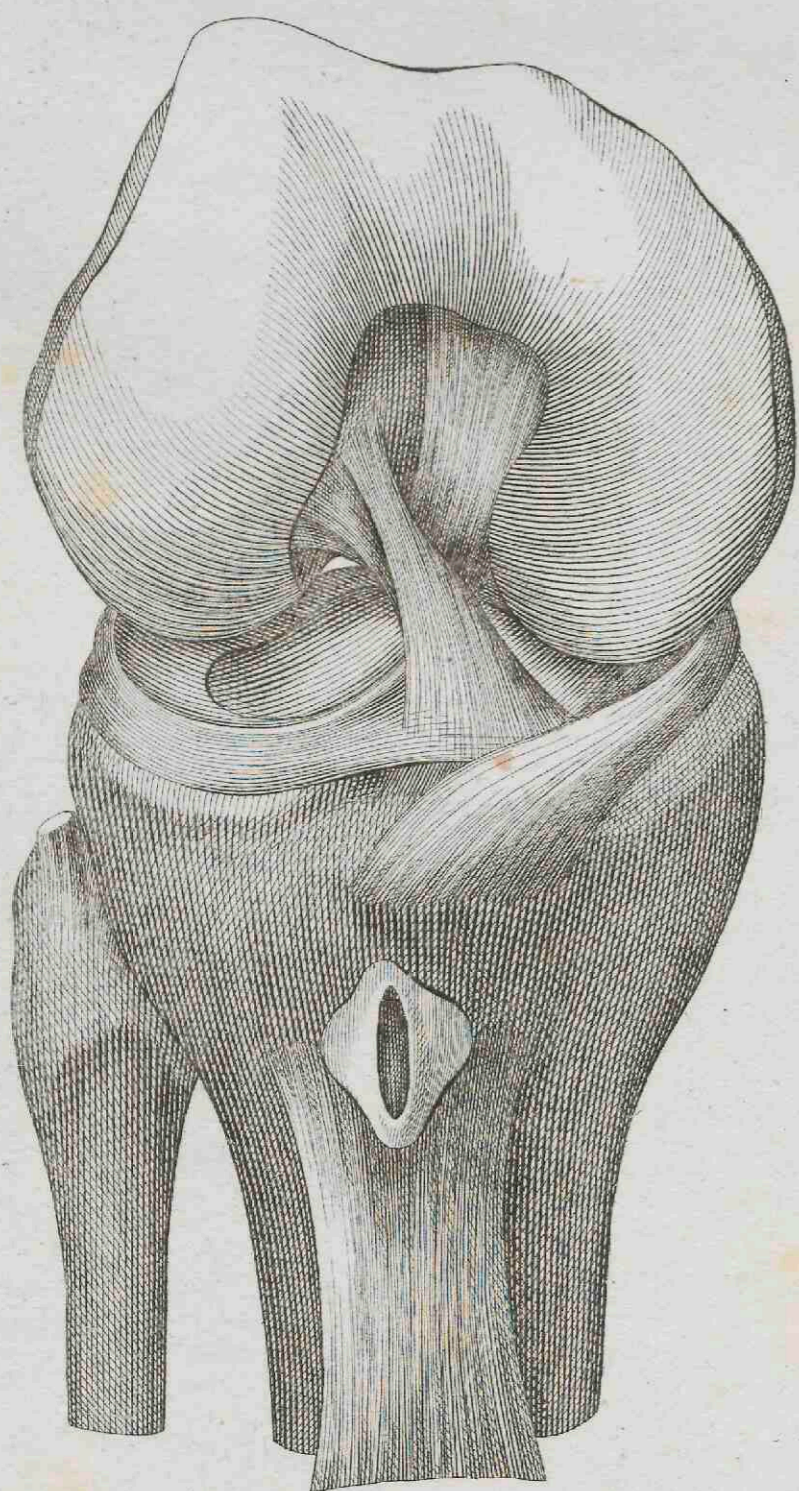
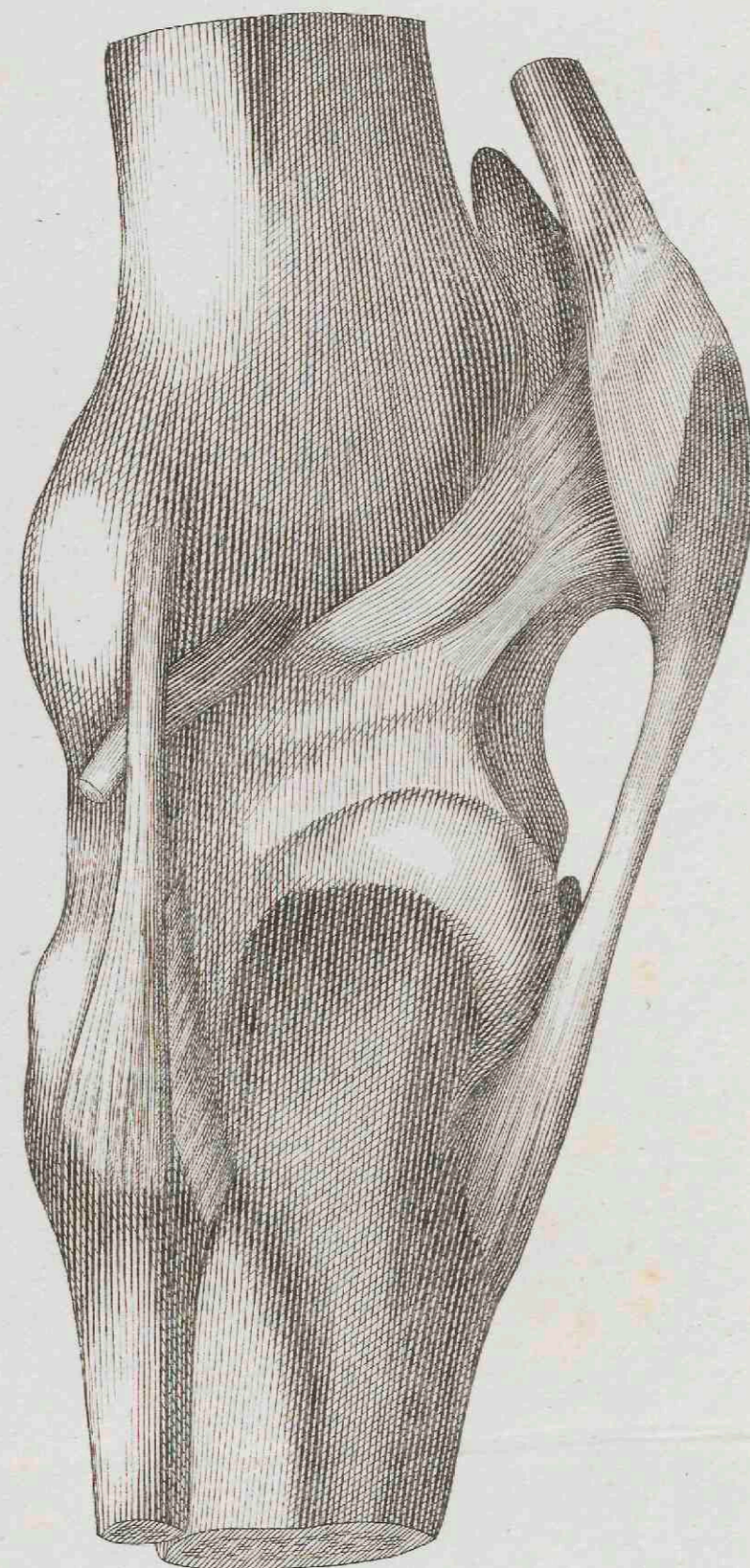
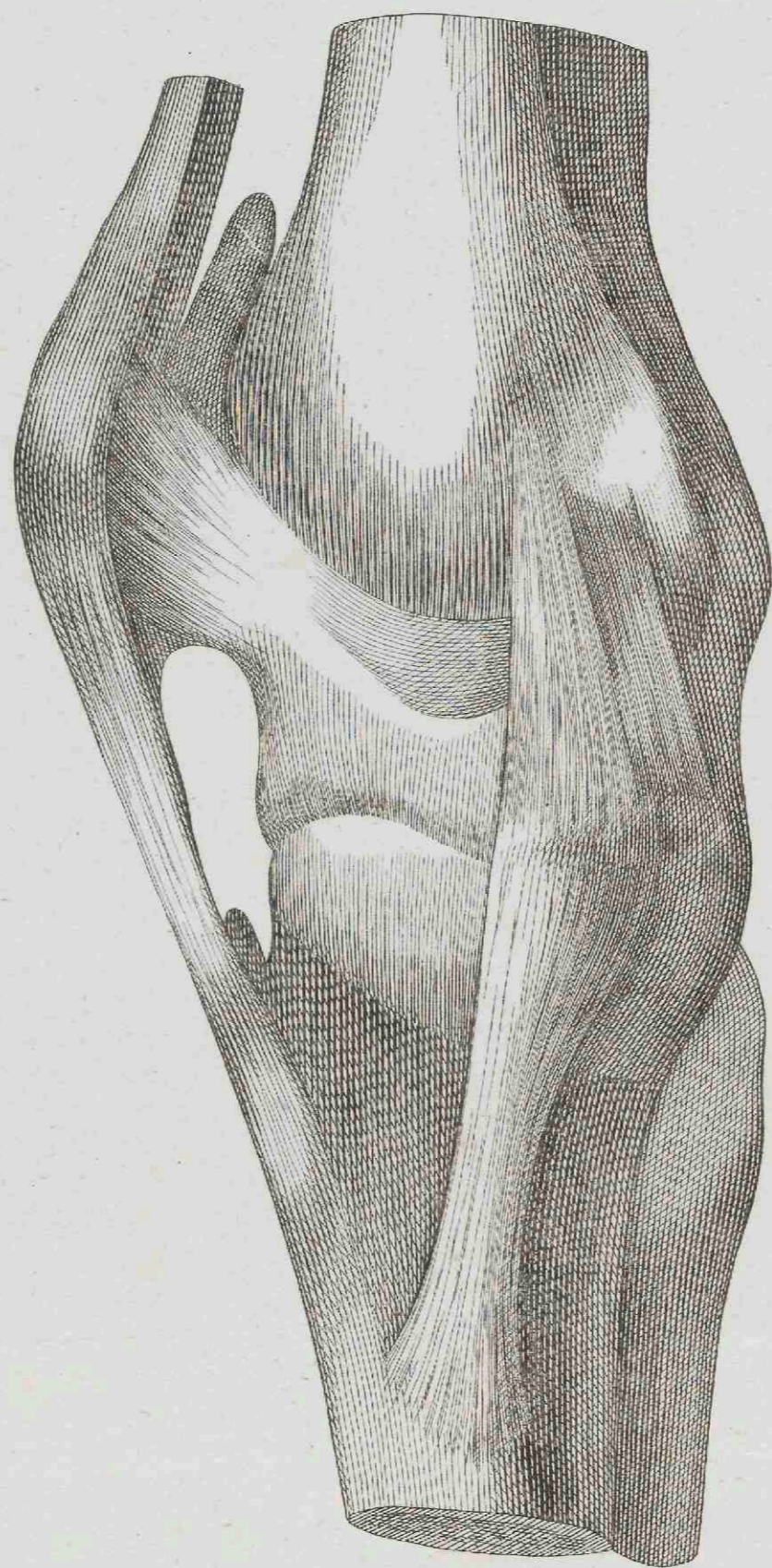
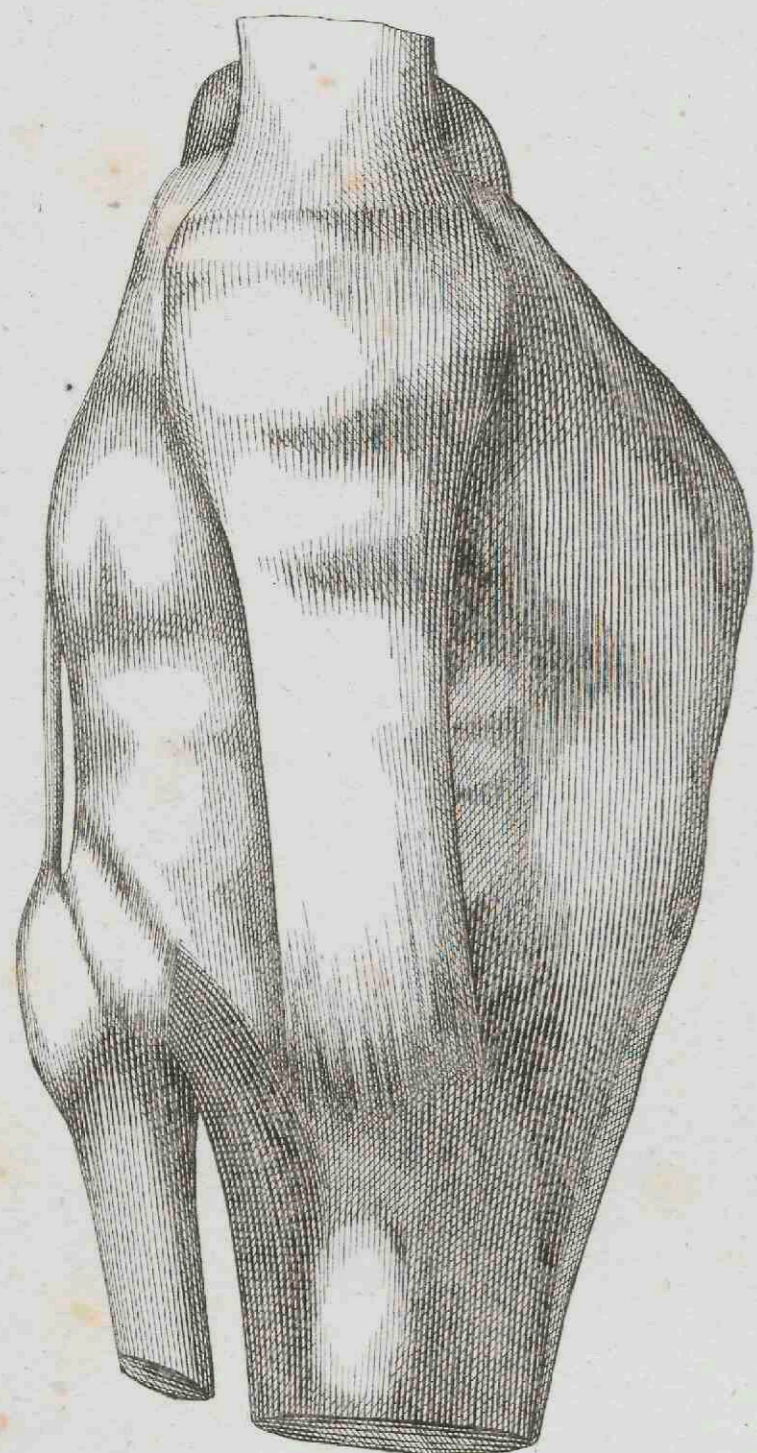
Baender des Beckens.



Verbindung der Beckenknochen: 1. nach vorn die Schambeinfuge u. das lig. arcuatum, 2. nach hinten und oben die Hüft- u. Heiligbeinfuge u. die Seitenbänder, das lig. ileolumbale sup. et inf. und lig. sacrum longum et breve, 3. nach hinten und unten: l. sacrotuberosum et sacrospinosum. Das runde Loch wird durch die membrana obturatoria verschlossen. Am Hüftgelenke findet sich die knorpeliche Lippe (labrum cartilagineum acetabuli), die Synovialhaut und das runde Band (lig. teres).

Bänder des Fußes.





Kniegelenk: 1 sein Kniegelenkband wird durch Falten (Calaris) in zwei Stücke getheilt.
 2. Faserbänder außer der Kniegelenk: inneres, langes und kurzes äußeres Seitenband.
 3. Faserbänder in ihr: hinteres und vorderes Kreuzband. — Halbmondförmige Zwischenknorpel.
Kniegelenk nach oben durch Sehnen, nach unten durch ein Band befestigt.

OESTERREICHER'S

Anatomische Steinstücke.

Dritte Abtheilung

Muskeln

des

Menschlichen Körpers.

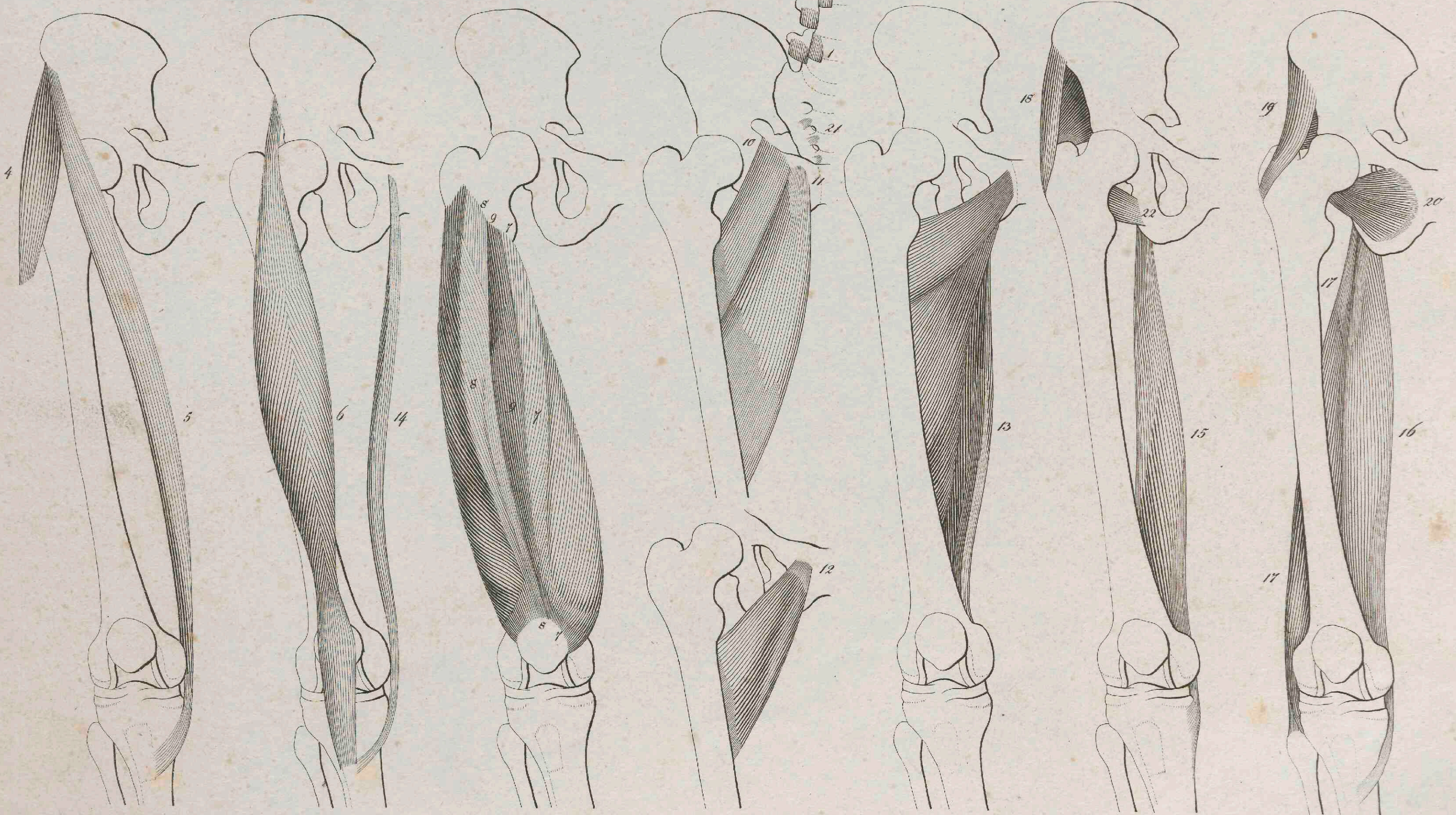
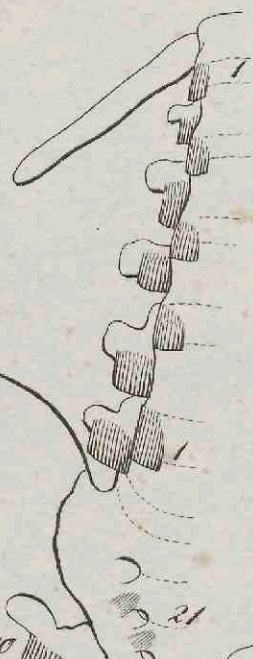
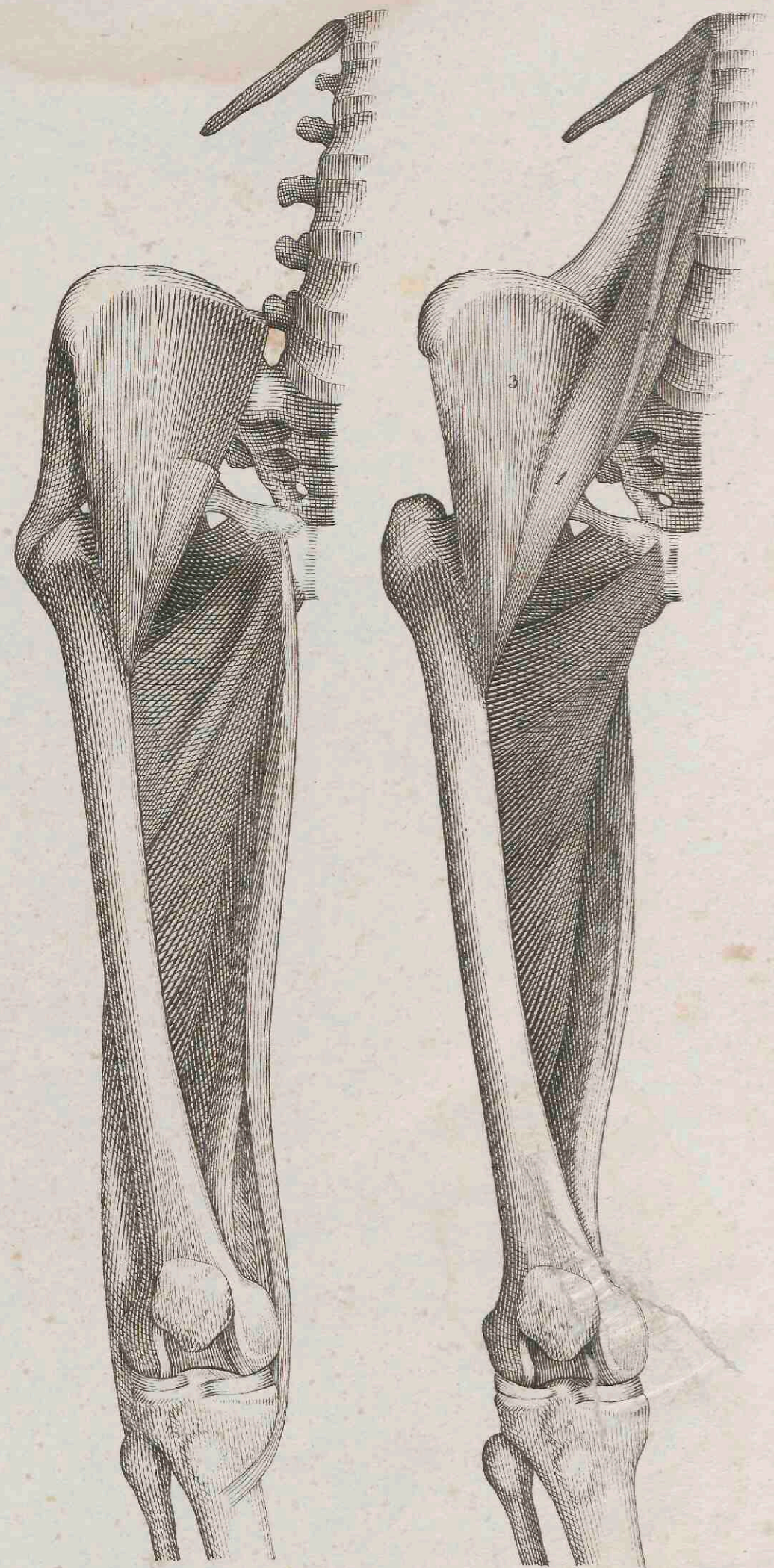
Zweite umgearbeitete Ausgabe

München

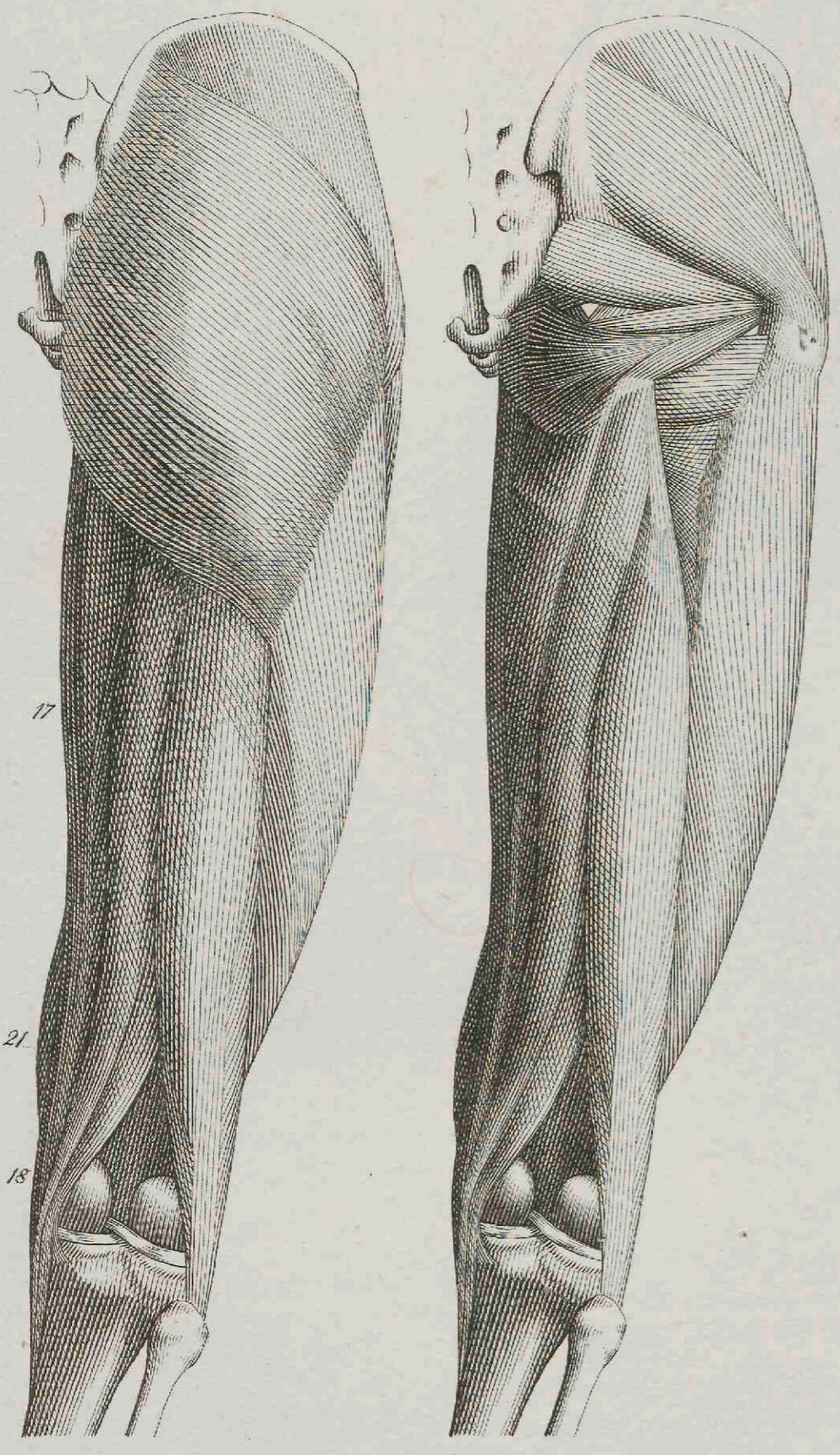
1829

MUSKELN des Oberschenkels.

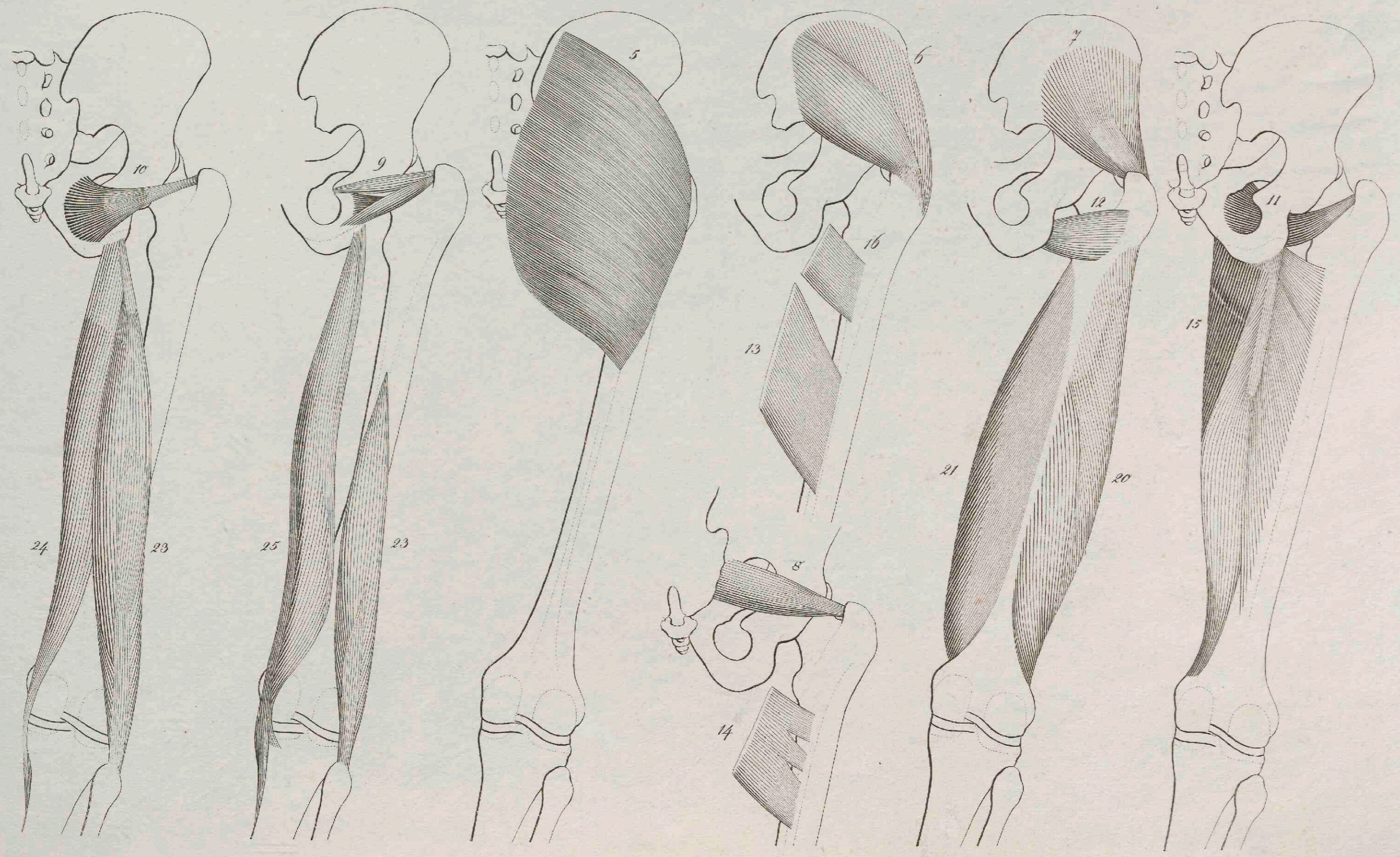
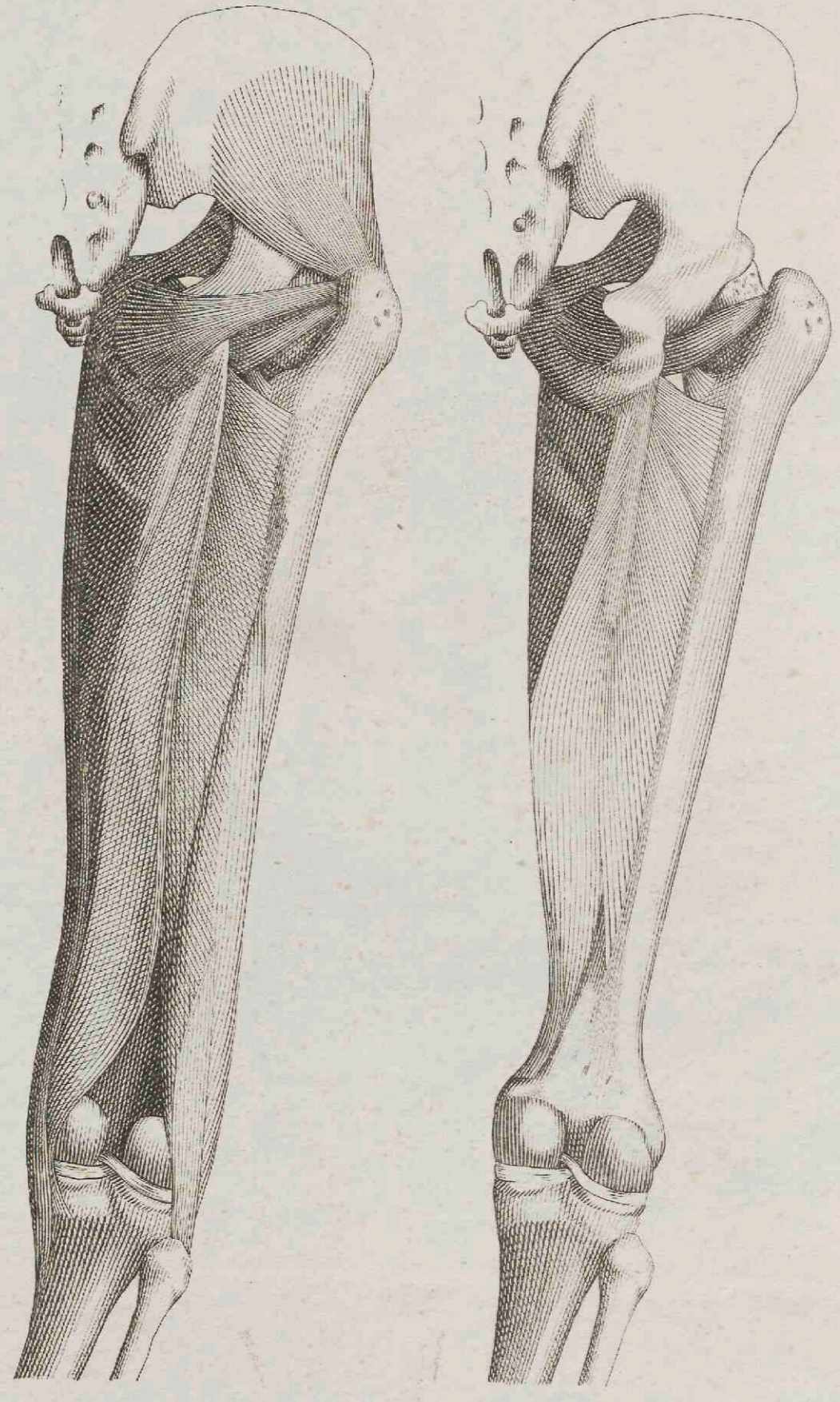
- 1 *Psoas major*
- 2 — *minor*
- 3 *iliacus internus*
- 4 *tensor fasciae latae*
- 5 *sartorius*
- 6 *rectus*
- 7 *vastus internus*
- 8 — *externus*
- 9 *cruralis*
- 10 *pectineus*
- 11 *adductor longus*
- 12 — *brevis*
- 13 — *magnus*
- 14 *gracilis*
- 15 *semimembranosus*
- 16 *semitendinosus*
- 17 *biceps*
- 18 *gluteus medius*
- 19 — *minimus*
- 20 *obturator externus*
- 21 *pyramidalis*
- 22 *quadratus femoris.*

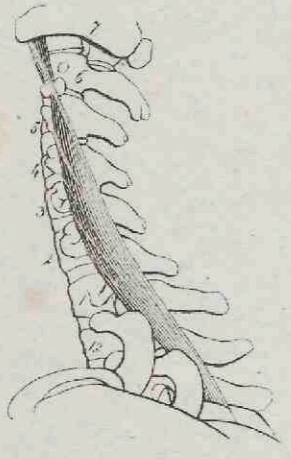


MUSKELN DES OBERSCHENKELS.

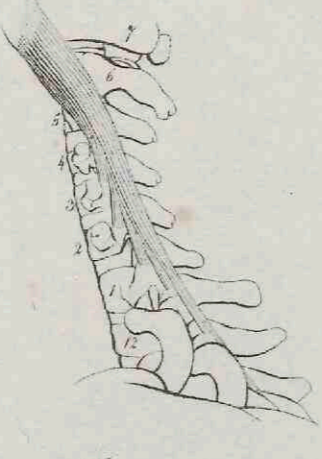


- 1. Tensor fasciae latae,
- 2. psoas magnus,
- 3. — psoas parvus,
- 4. iliacus internus,
- 5. gluteus maximus,
- 6. — medius,
- 7. — minimus,
- 8. pyrriformis,
- 9. gemelli,
- 10. obturator internus,
- 11. — externus,
- 12. quadratus,
- 13. adductor longus,
- triceps { 14. — brevis,
- 15. — magnus,
- 16. pectineus,
- 17. gracilis,
- 18. sartorius,
- 19. rectus,
- 20. vastus externus,
- 21. — internus,
- 22. cruralis,
- 23. biceps,
- 24. semitendinosus,
- 25. semimembranosus.

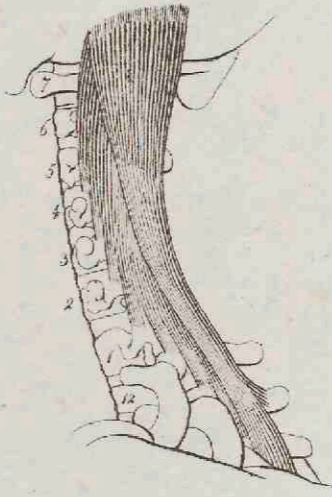




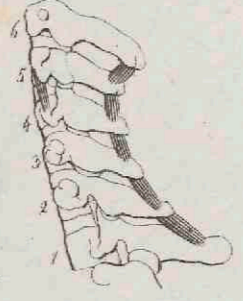
Transversalis cervicis cum insertis.
versare sexto posteriore.



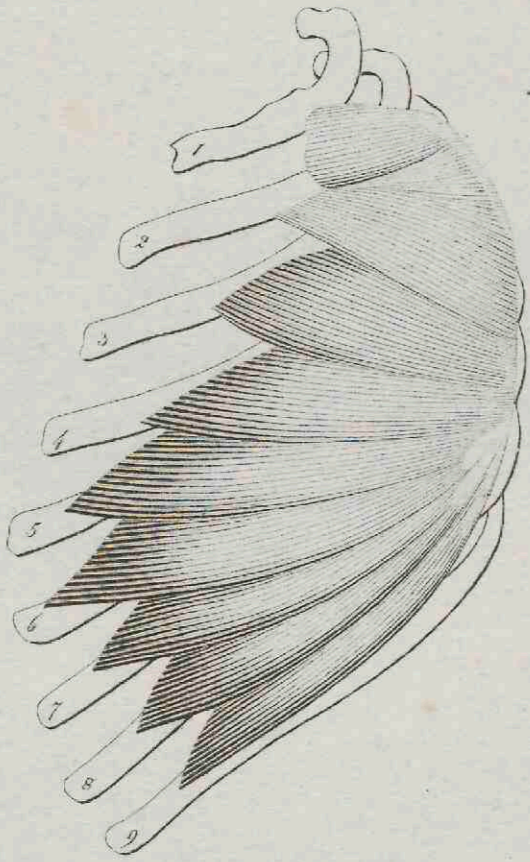
Trapezius.




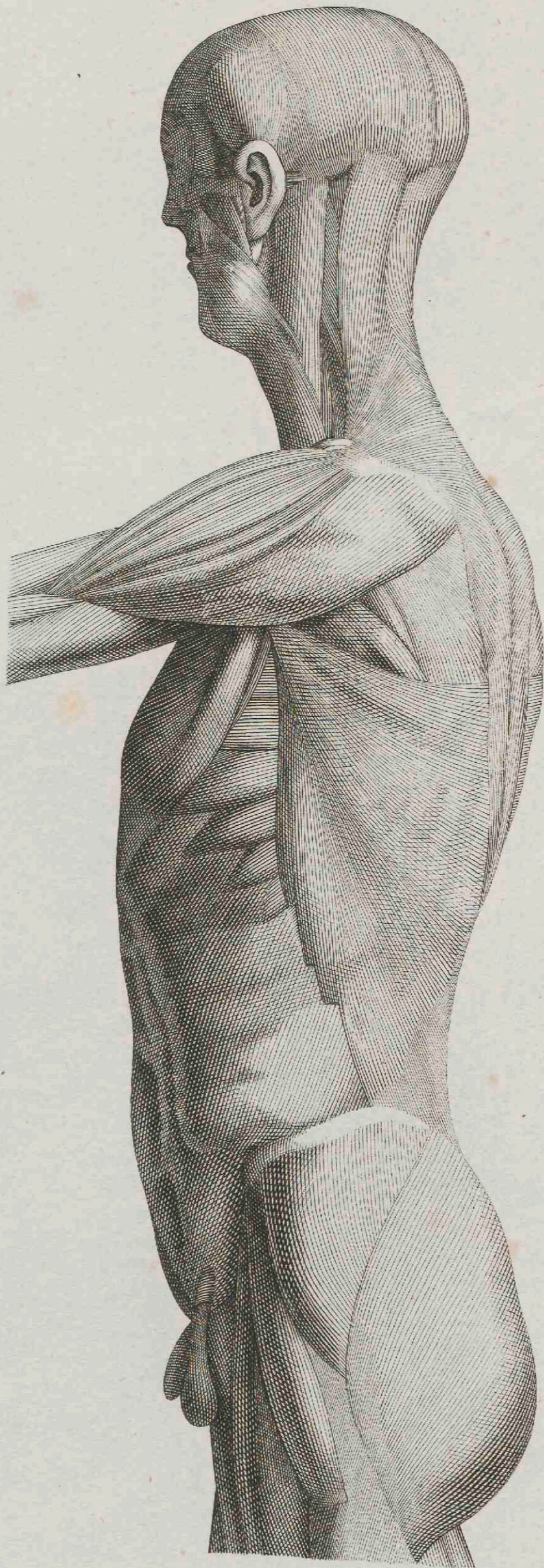
Biceps cum complexo.



Interspinalis cervicis, cum insertis.
versare priora quarto colli.

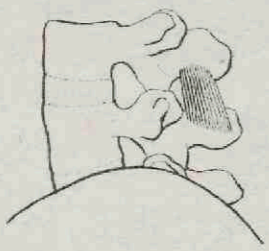

Serratus magnus.

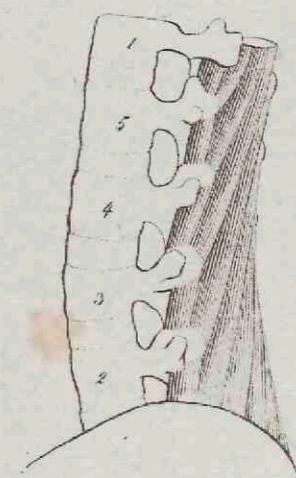


Intercostalis internus unus.

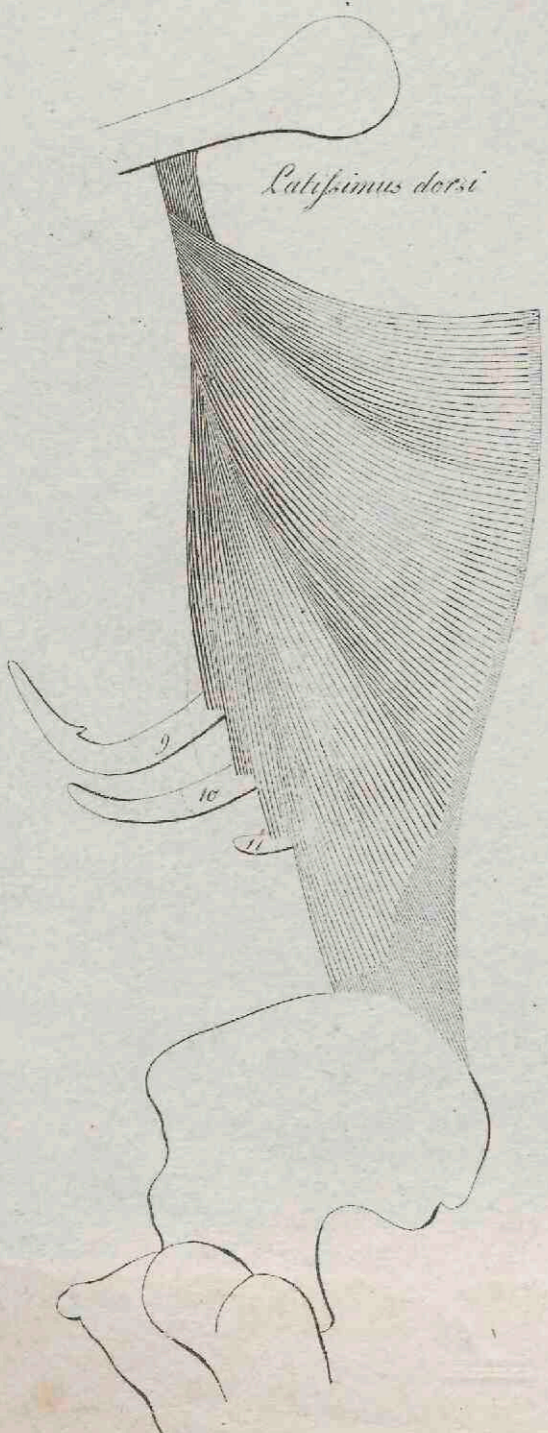
Intercostalis externus unus.



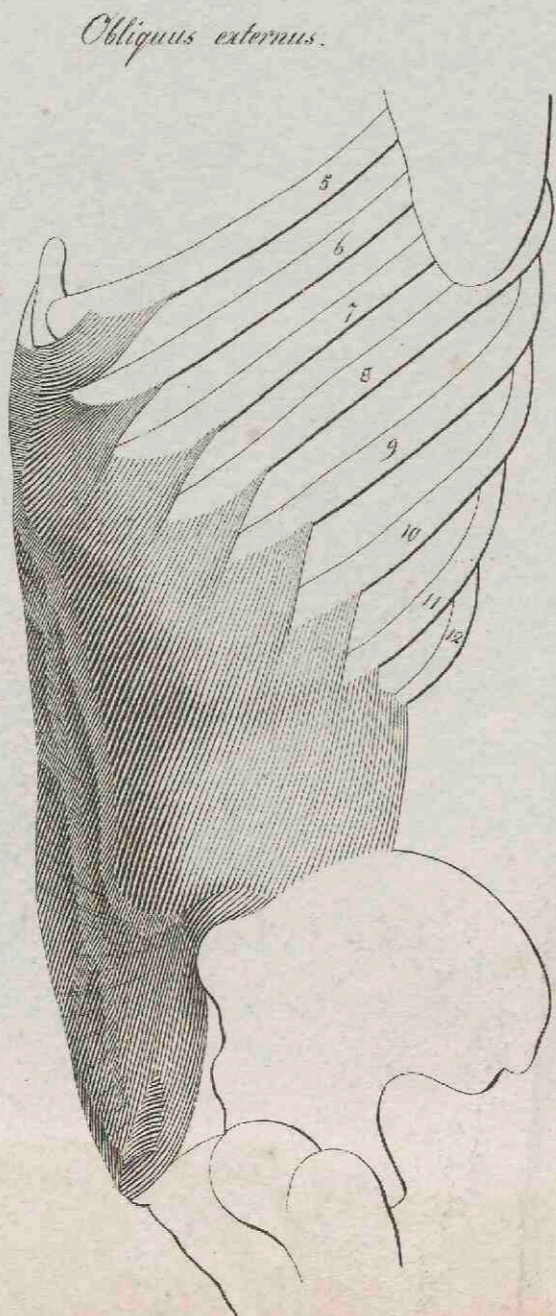
Interspinalis lumborum.



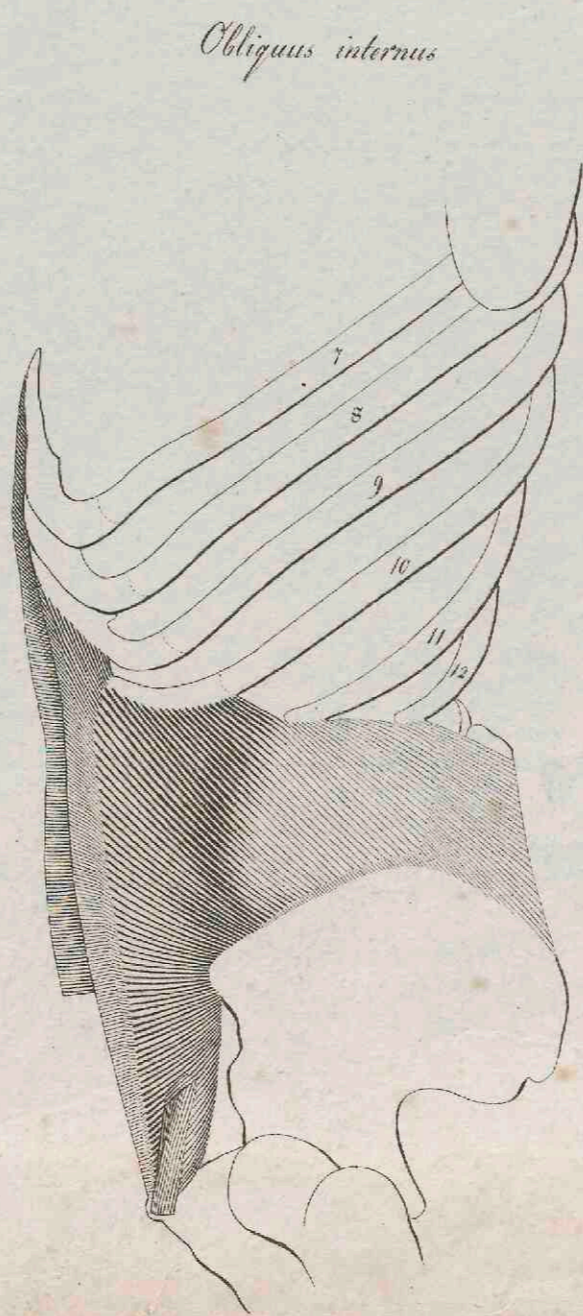
Multifidi spinae.



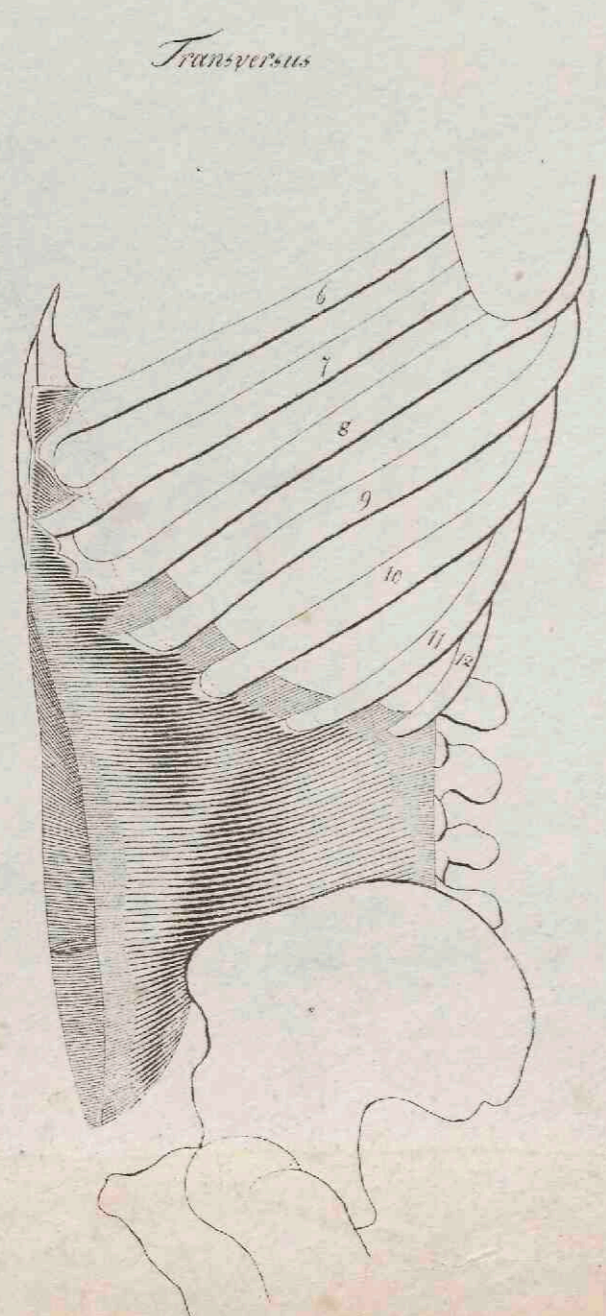
Latissimus dorsi.



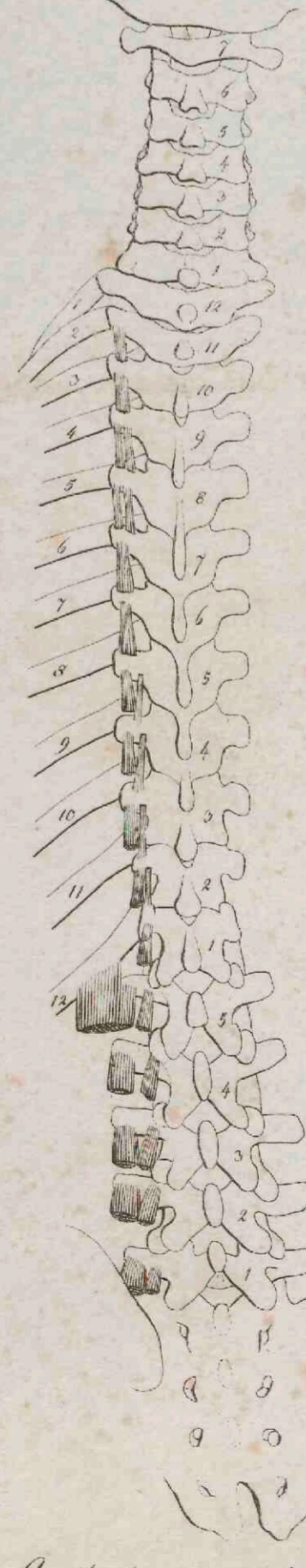
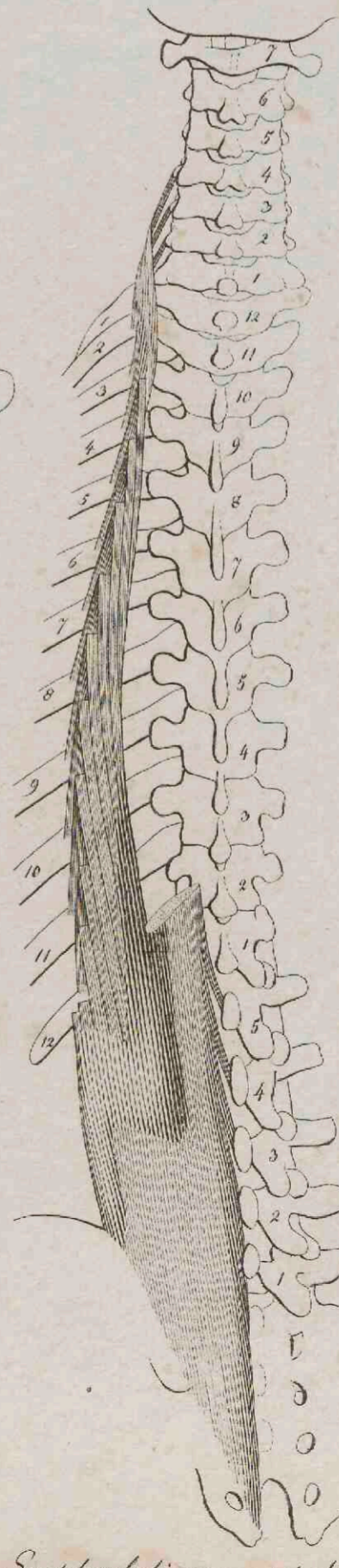
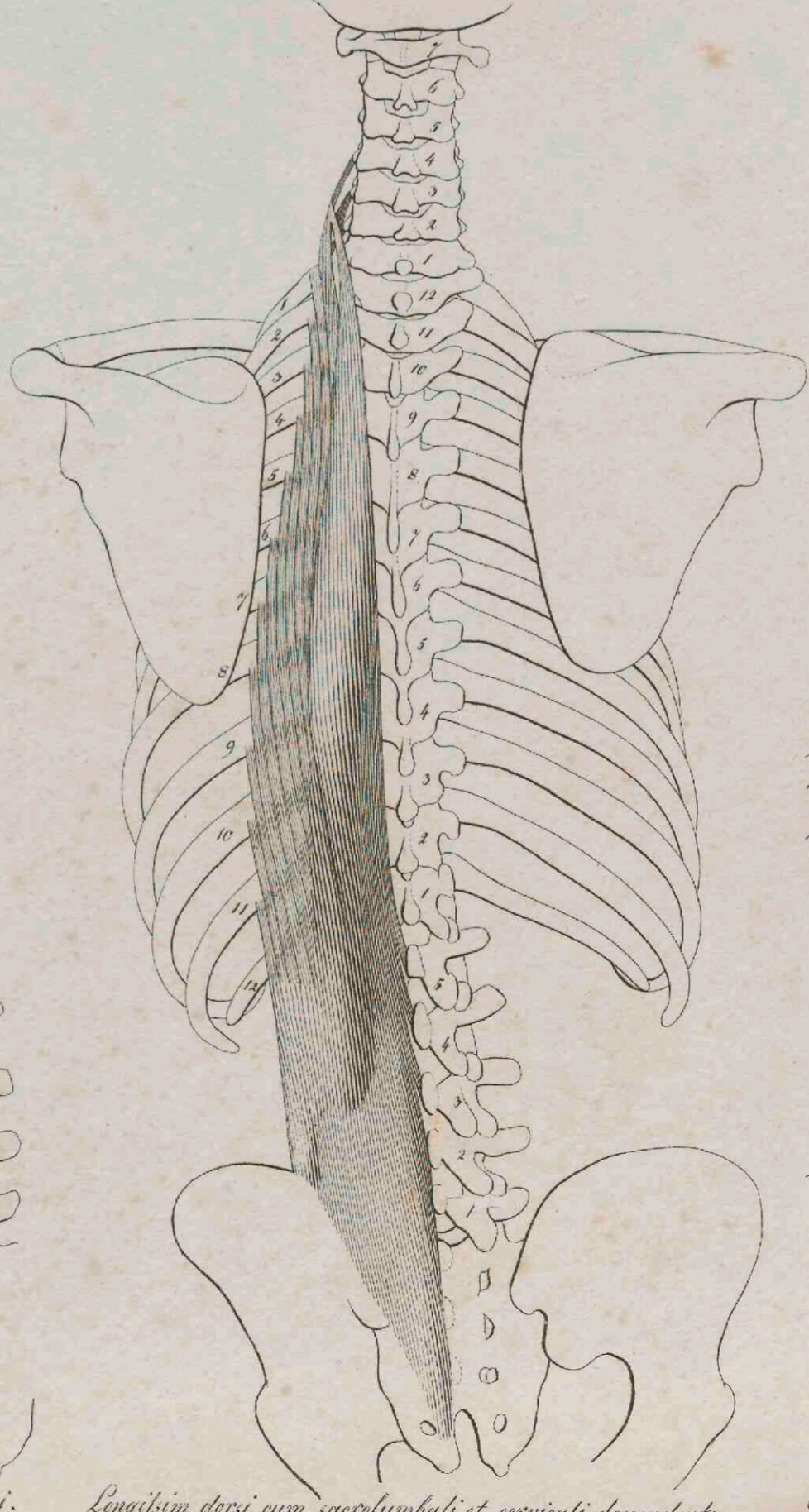
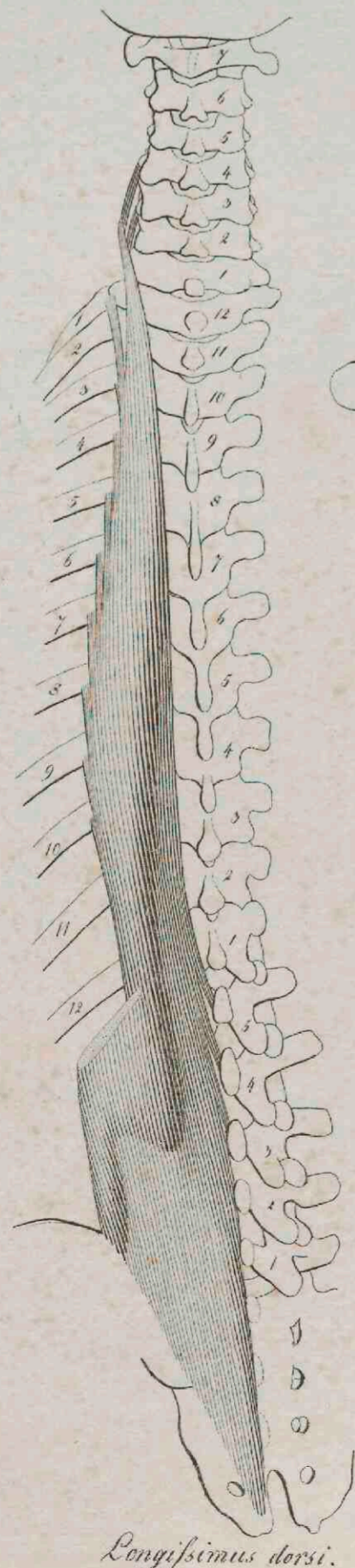



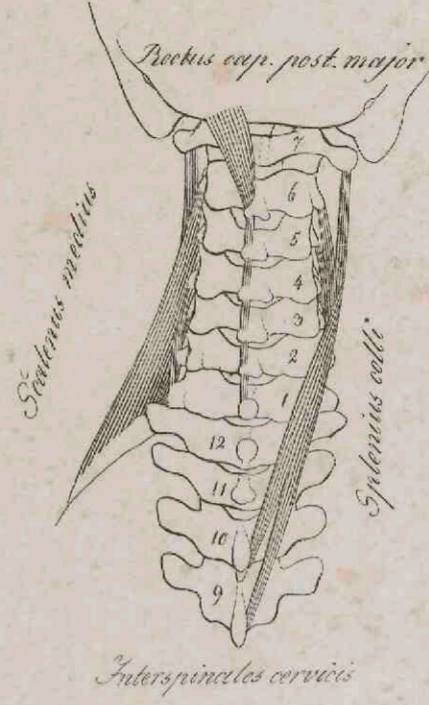
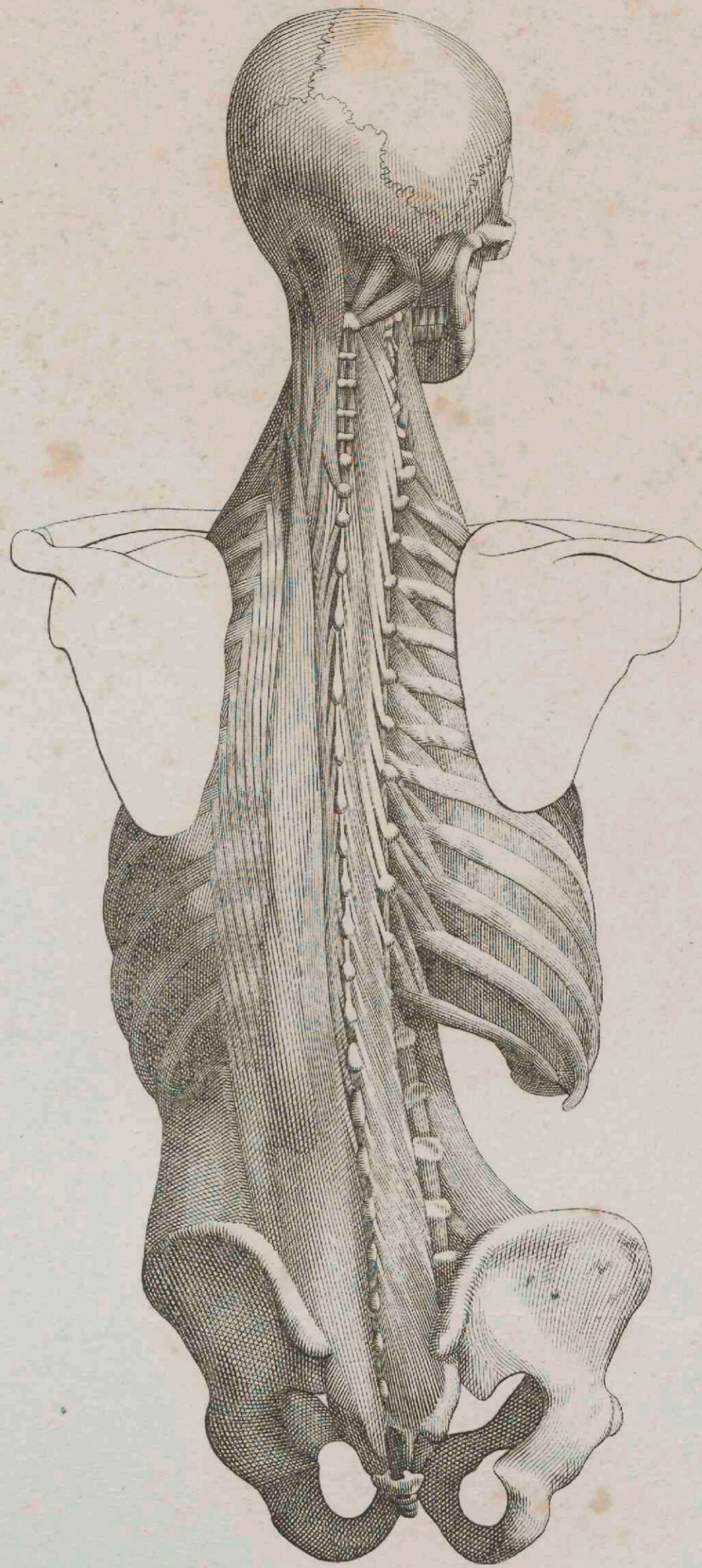
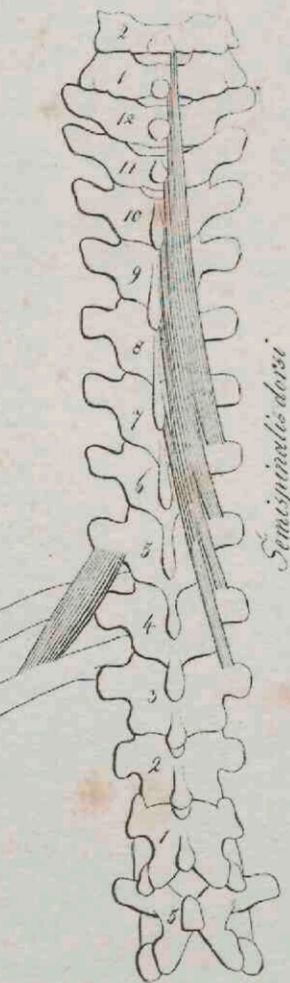
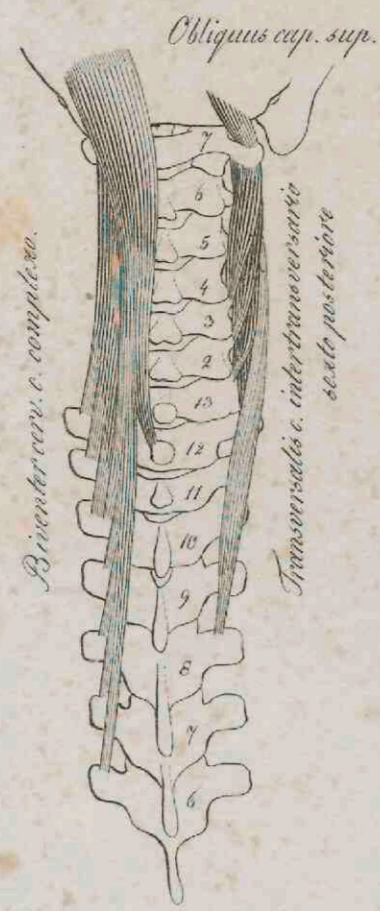

Obliquus externus.



Obliquus internus.



Transversus.



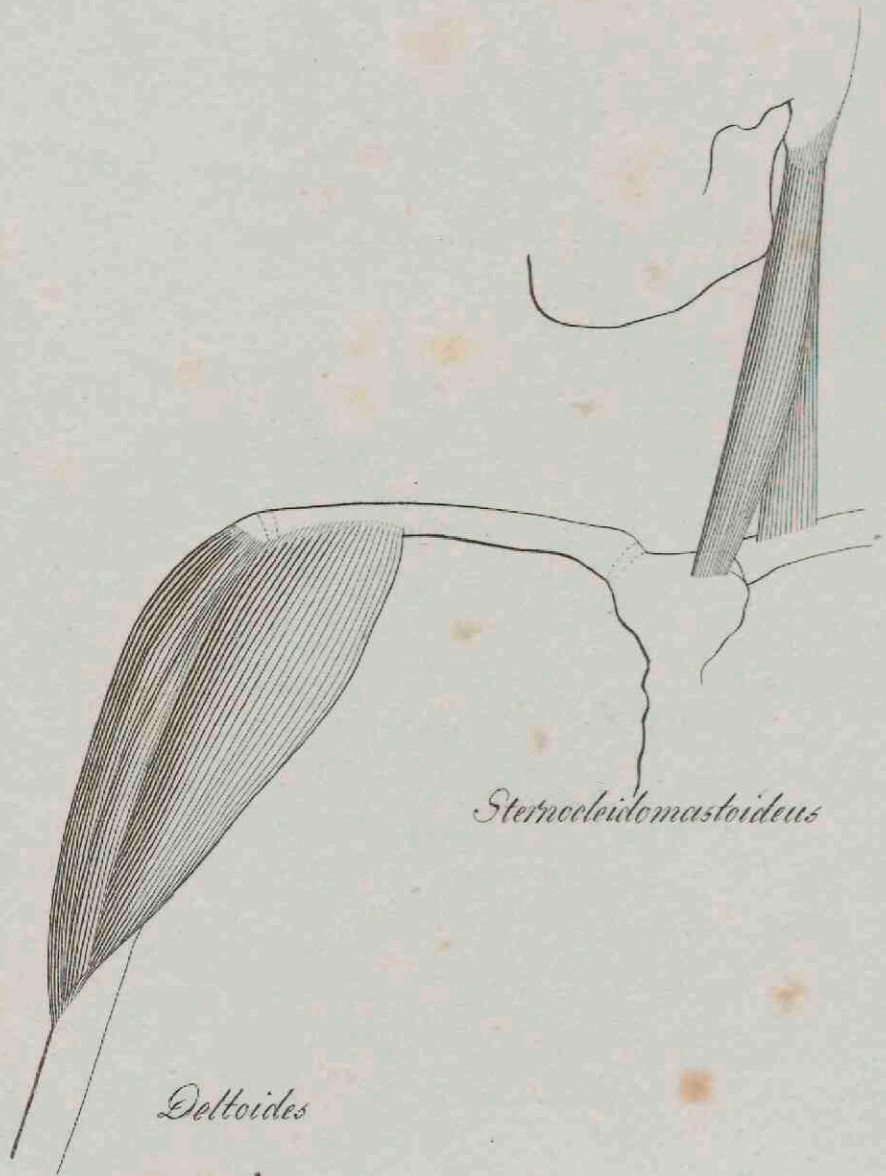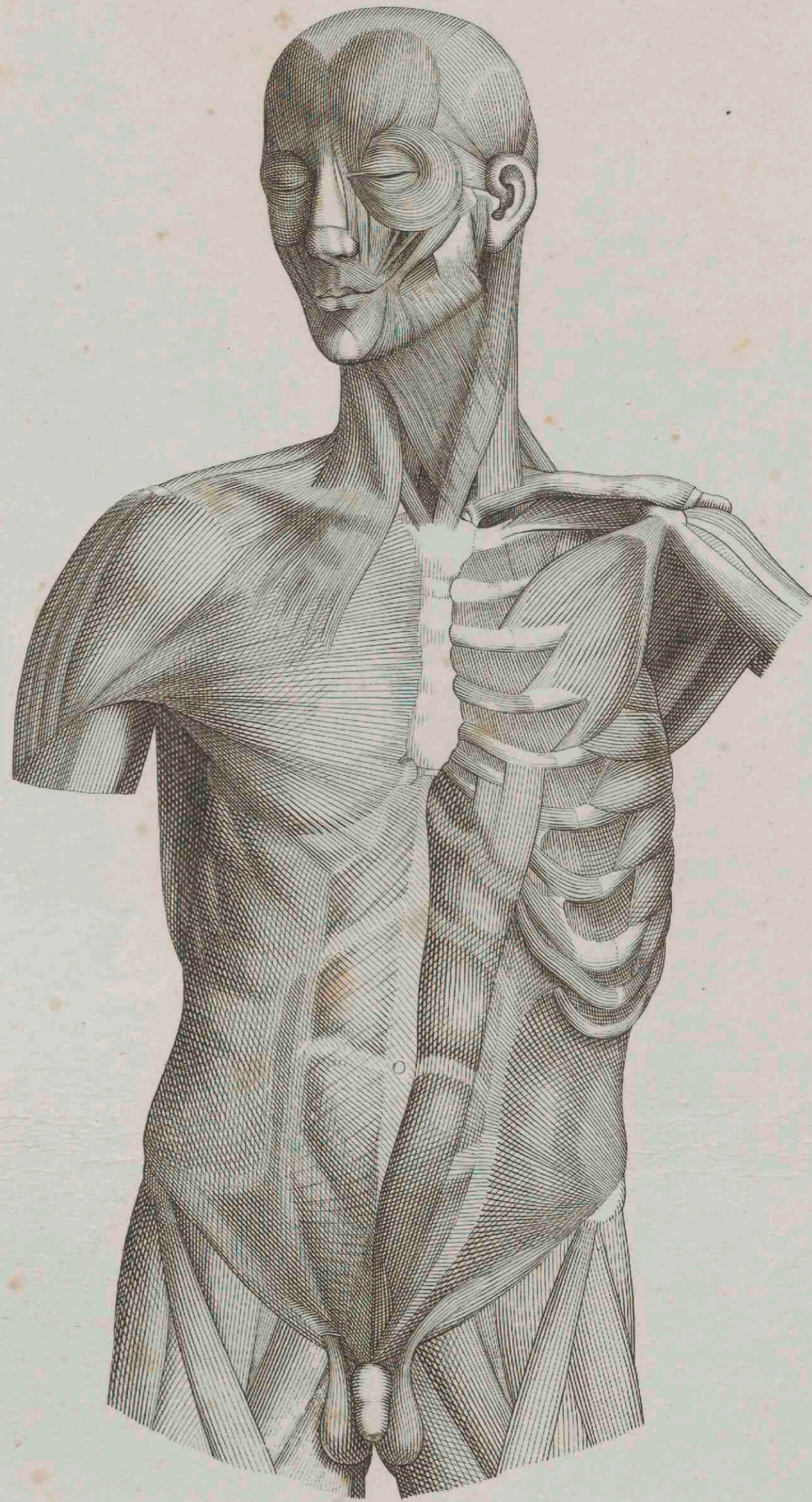
Multitudo spinosae.

Longissimus dorsi.

Longissimus dorsi cum sacrolumbalis et cervicis descendente.


Sacrolumbalis cum cervicis desc.

Longiss. dorsi et sacrolumbalis.




Sternocleidomastoideus

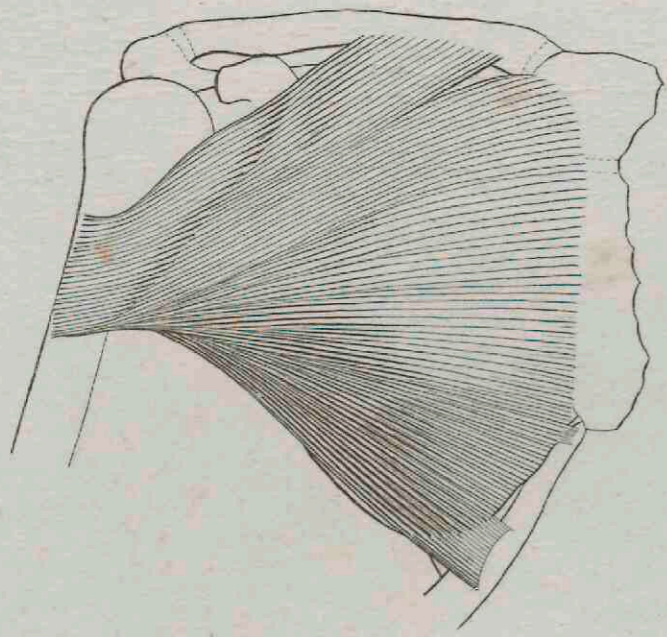
Deltoides



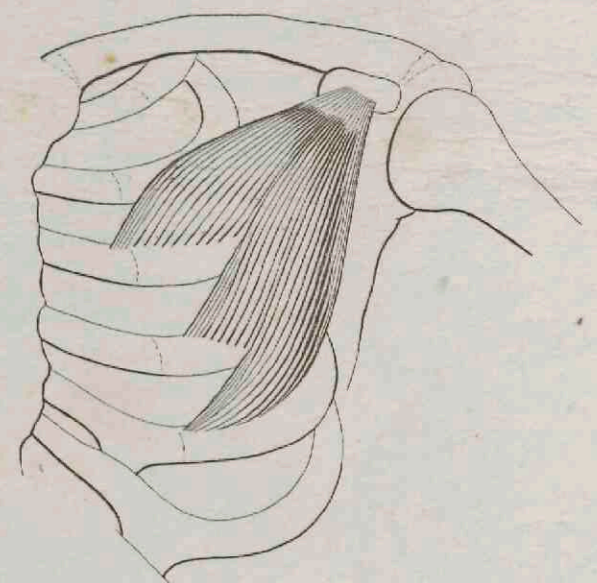
Latissimus colli



Subclavius



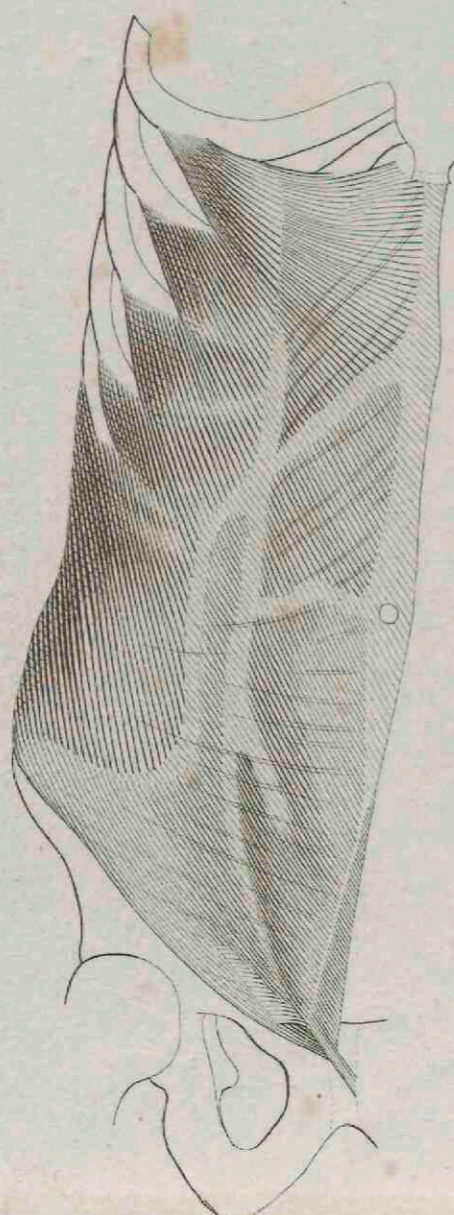
Pectoralis



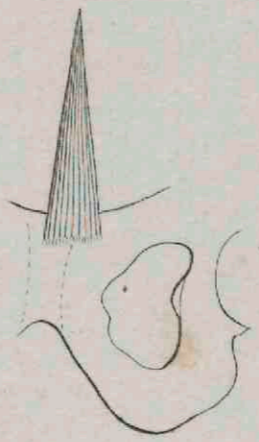
Serratus anticus



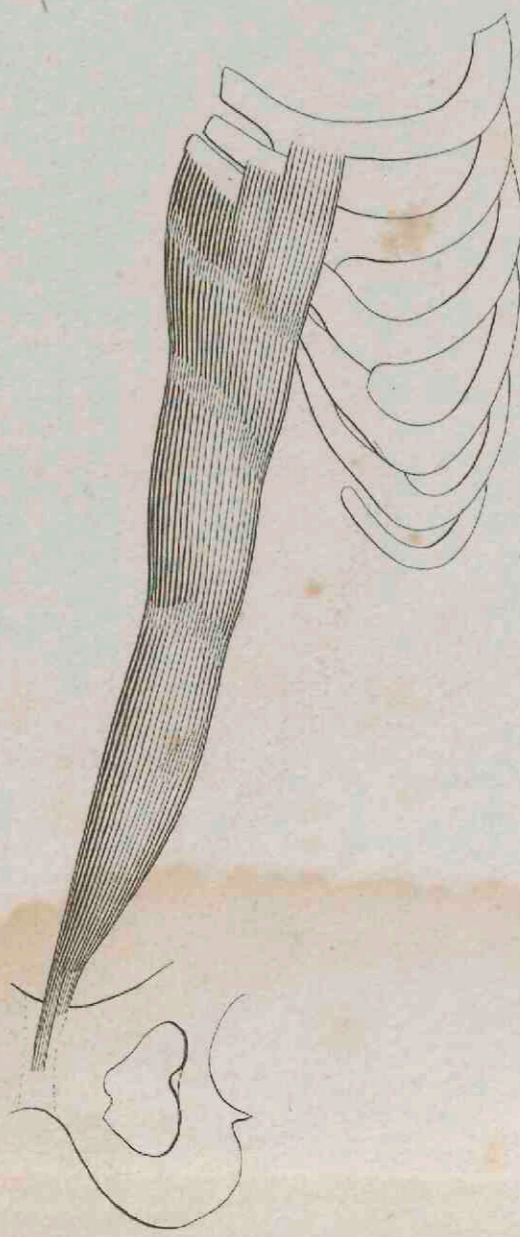
Transversus o. triangulari sterni.



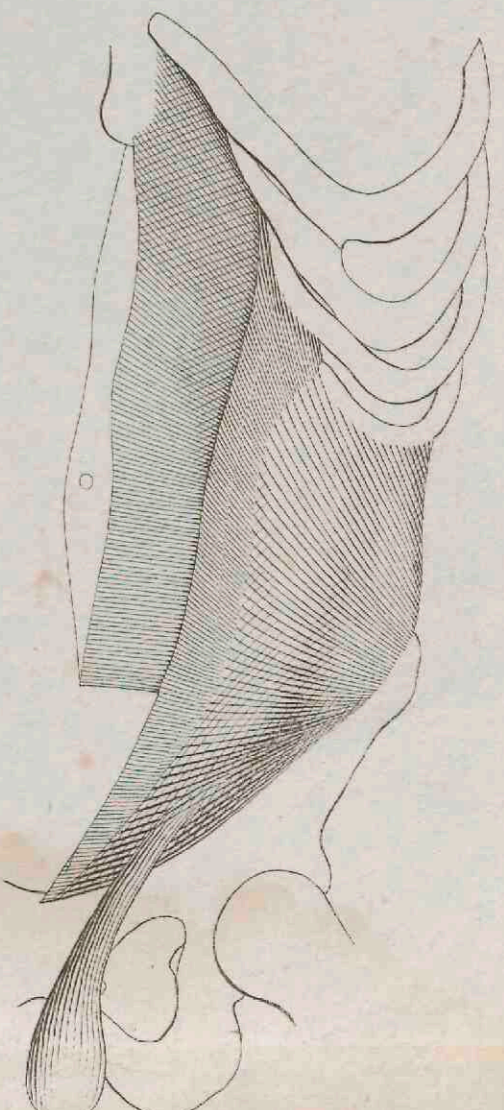
Obliquus externus



Pyramidalis

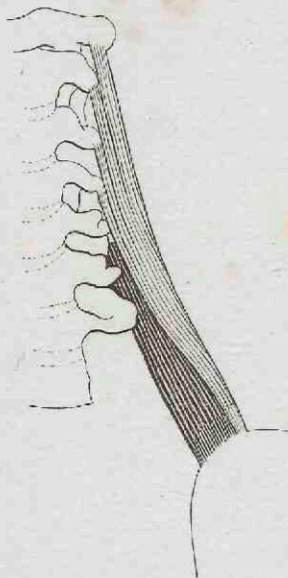


Rectus

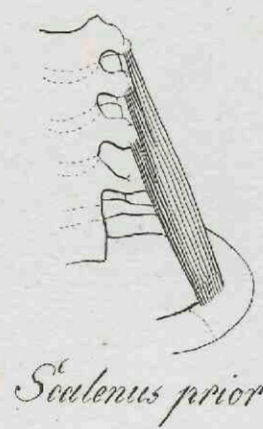
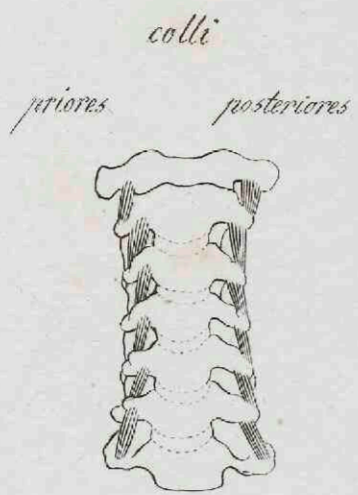


Obliquus internus.

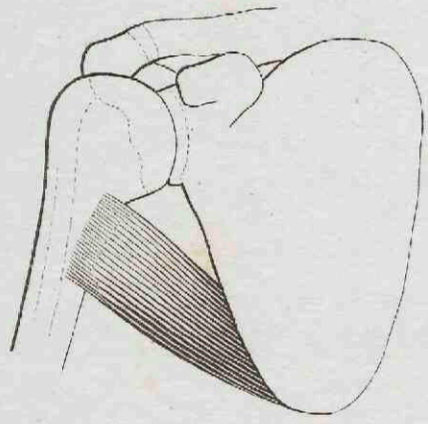
Levator scapulae



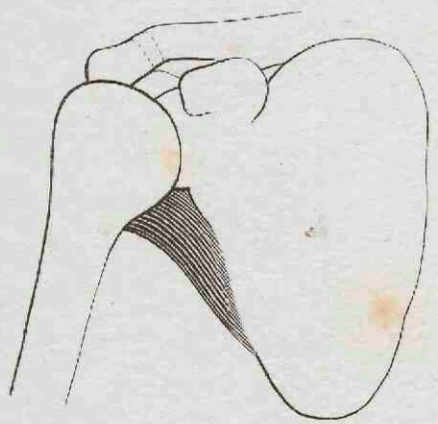
Intertransversarii



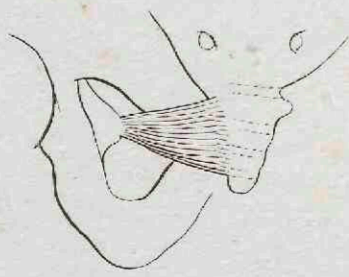
Scalenus prior



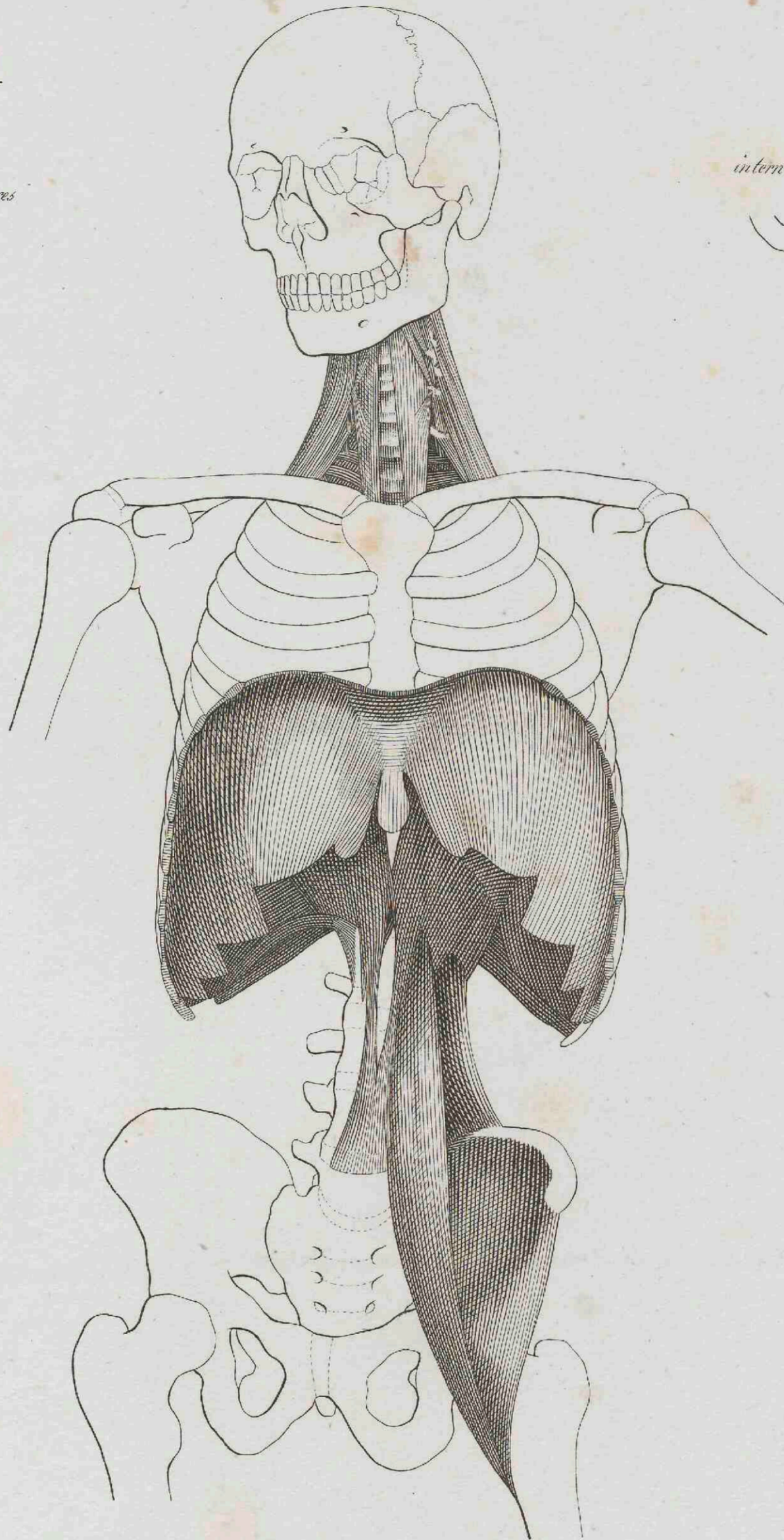
Teres major



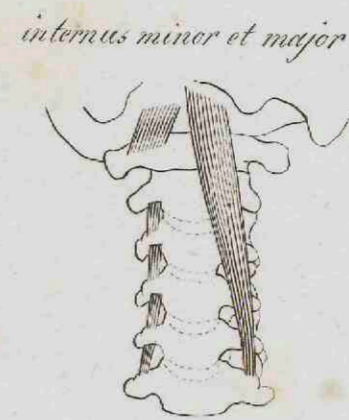
Teres minor



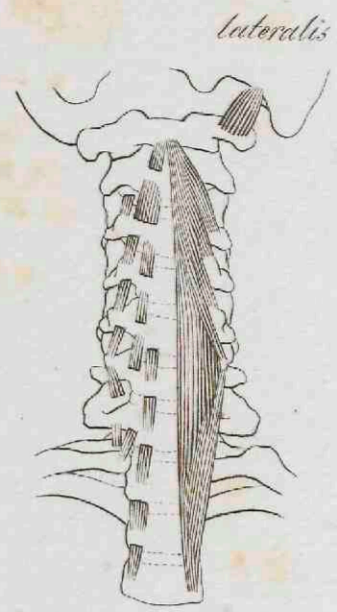
Coccygeus



Recti capitis

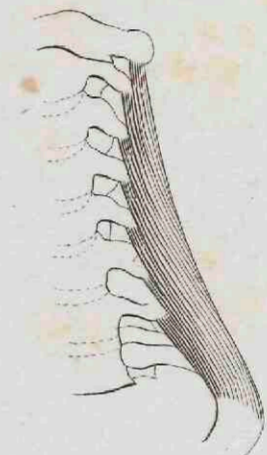


inferius minor et major

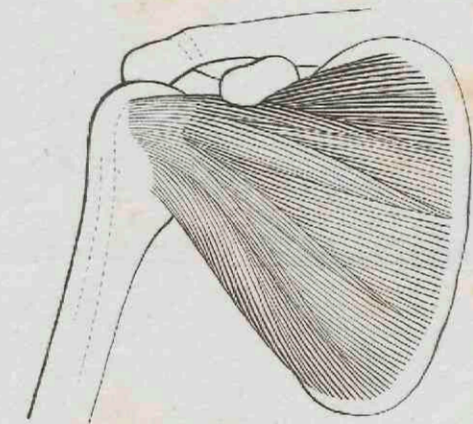


lateralis

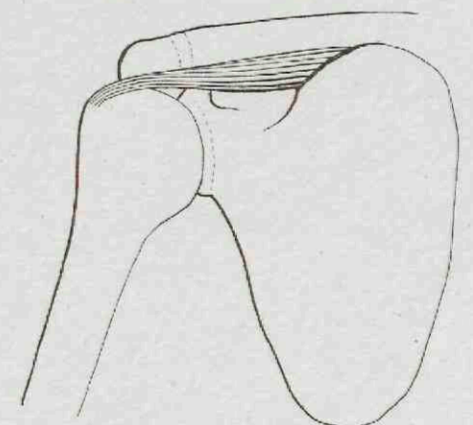
Longus colli



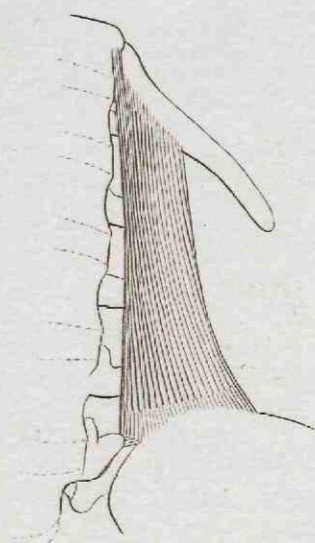
Scalenus medius



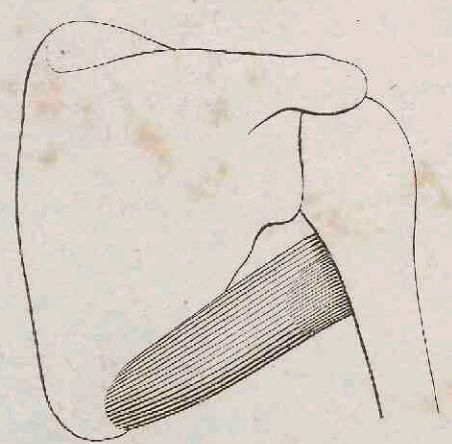
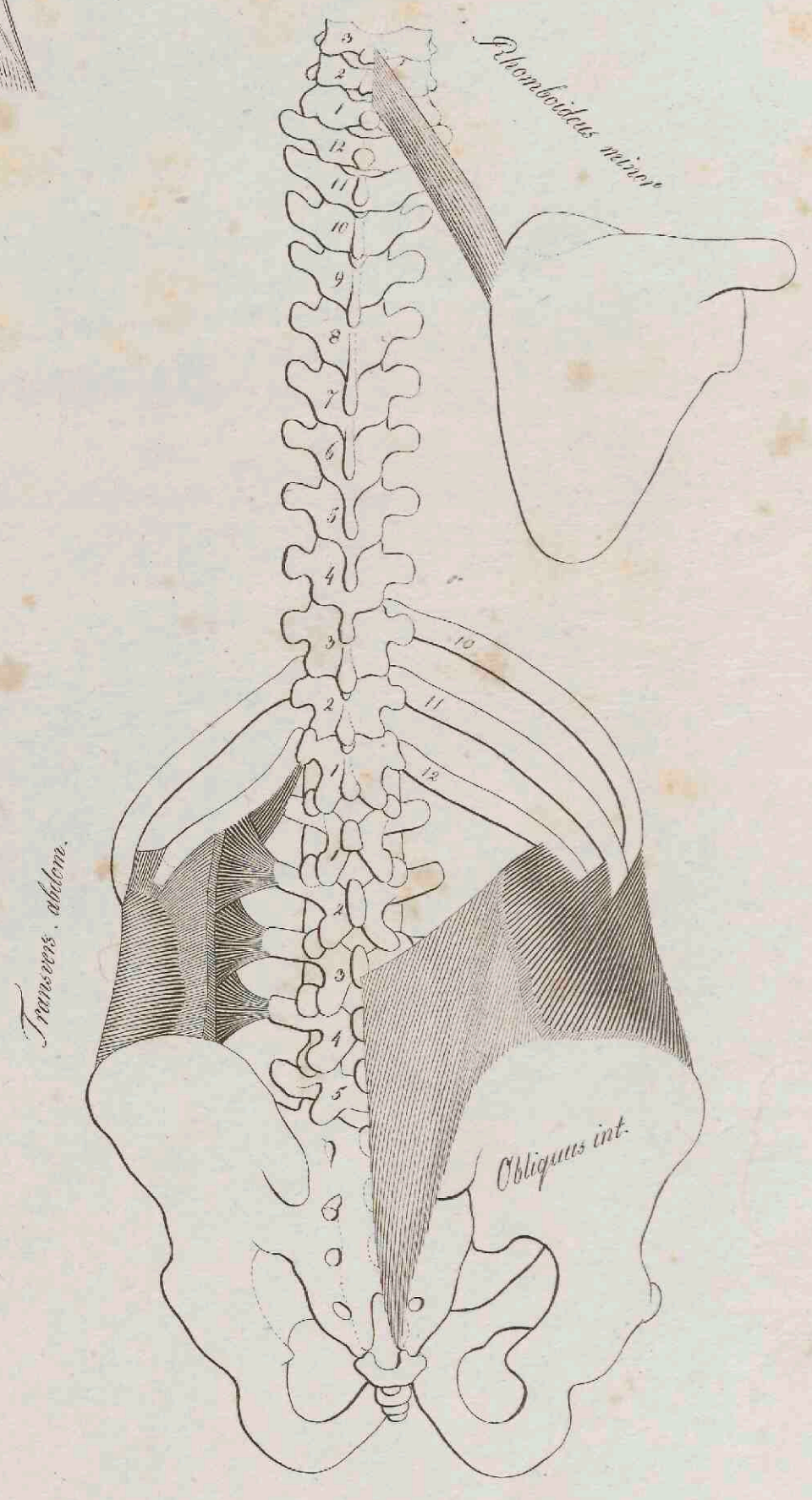
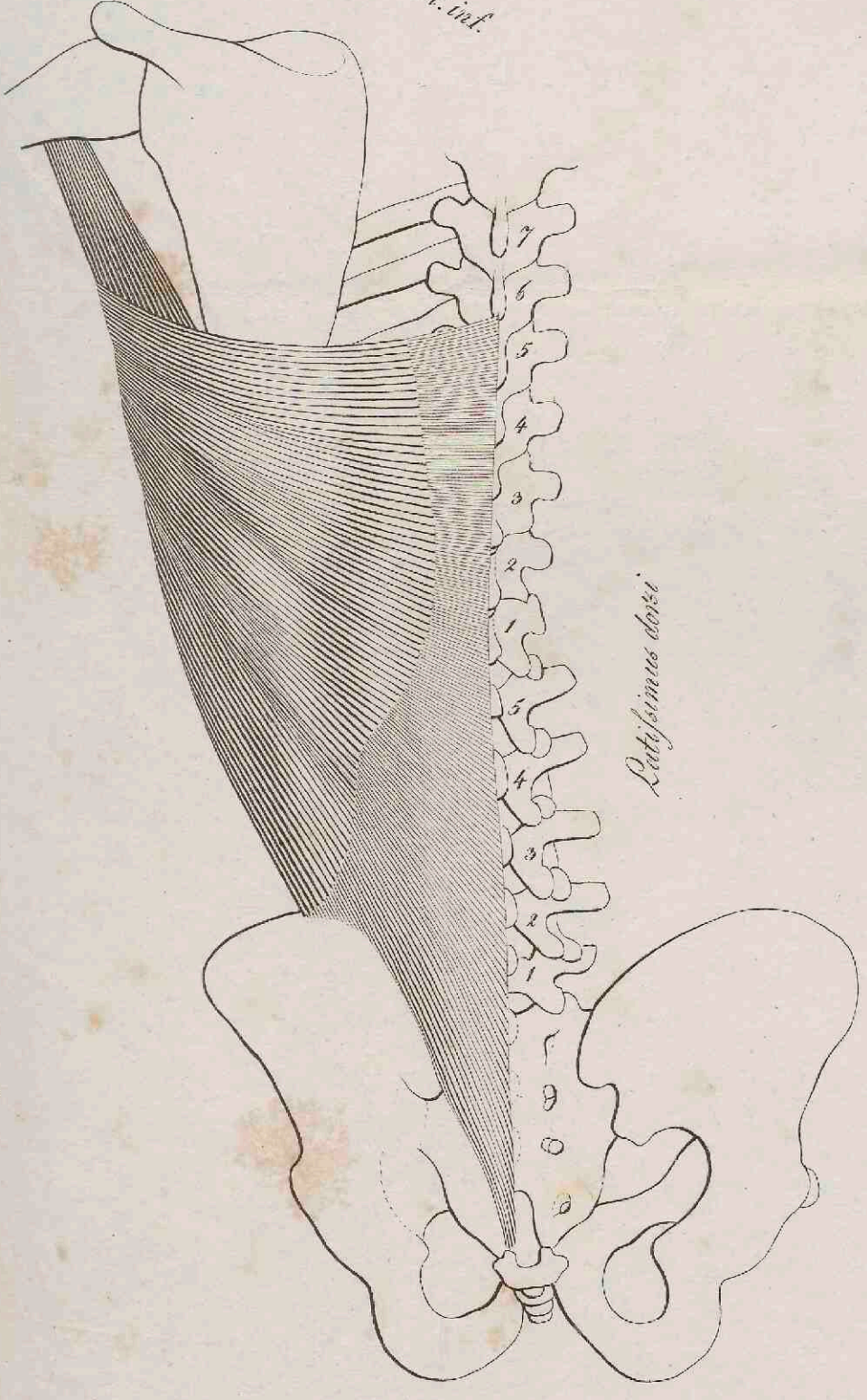
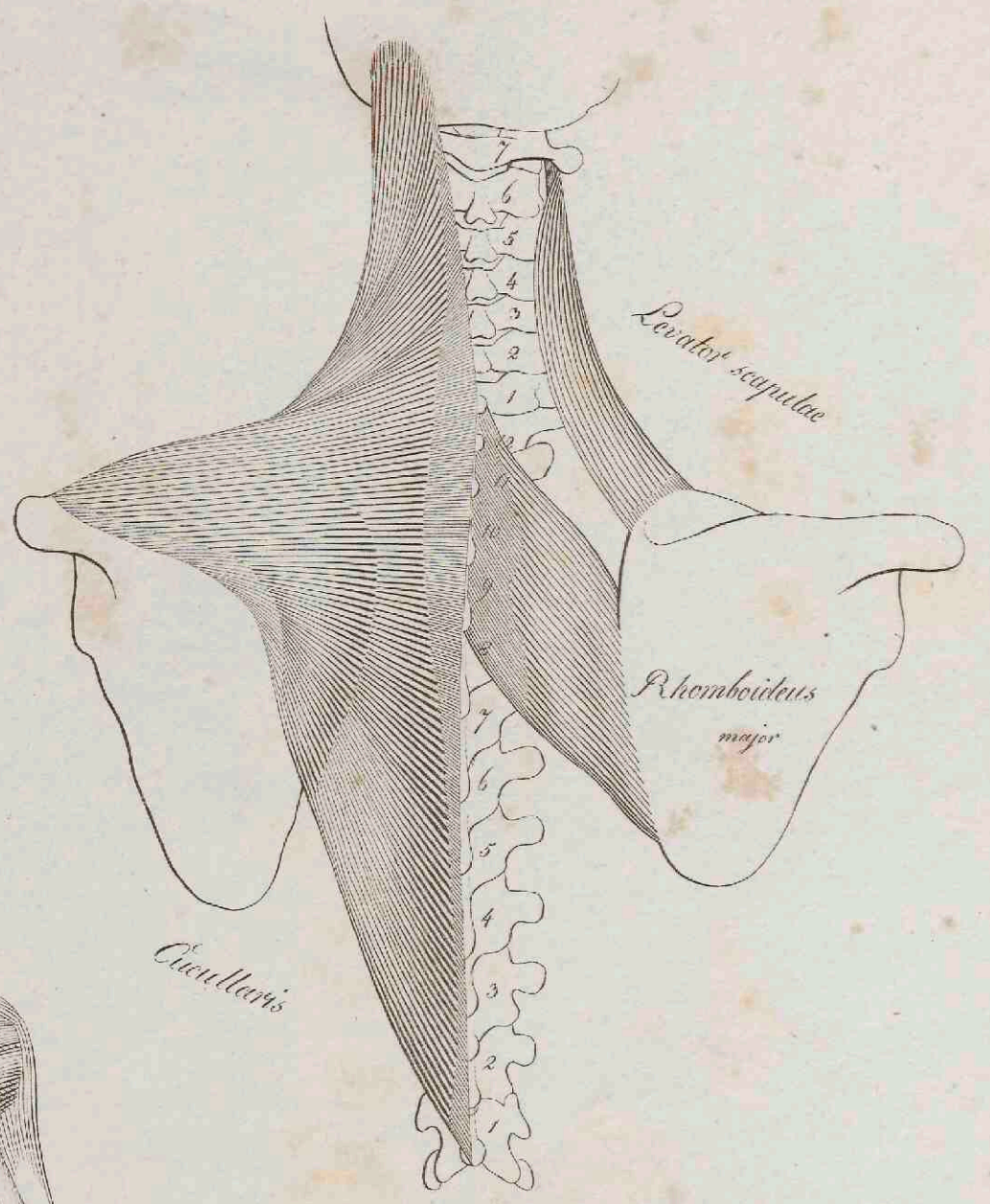
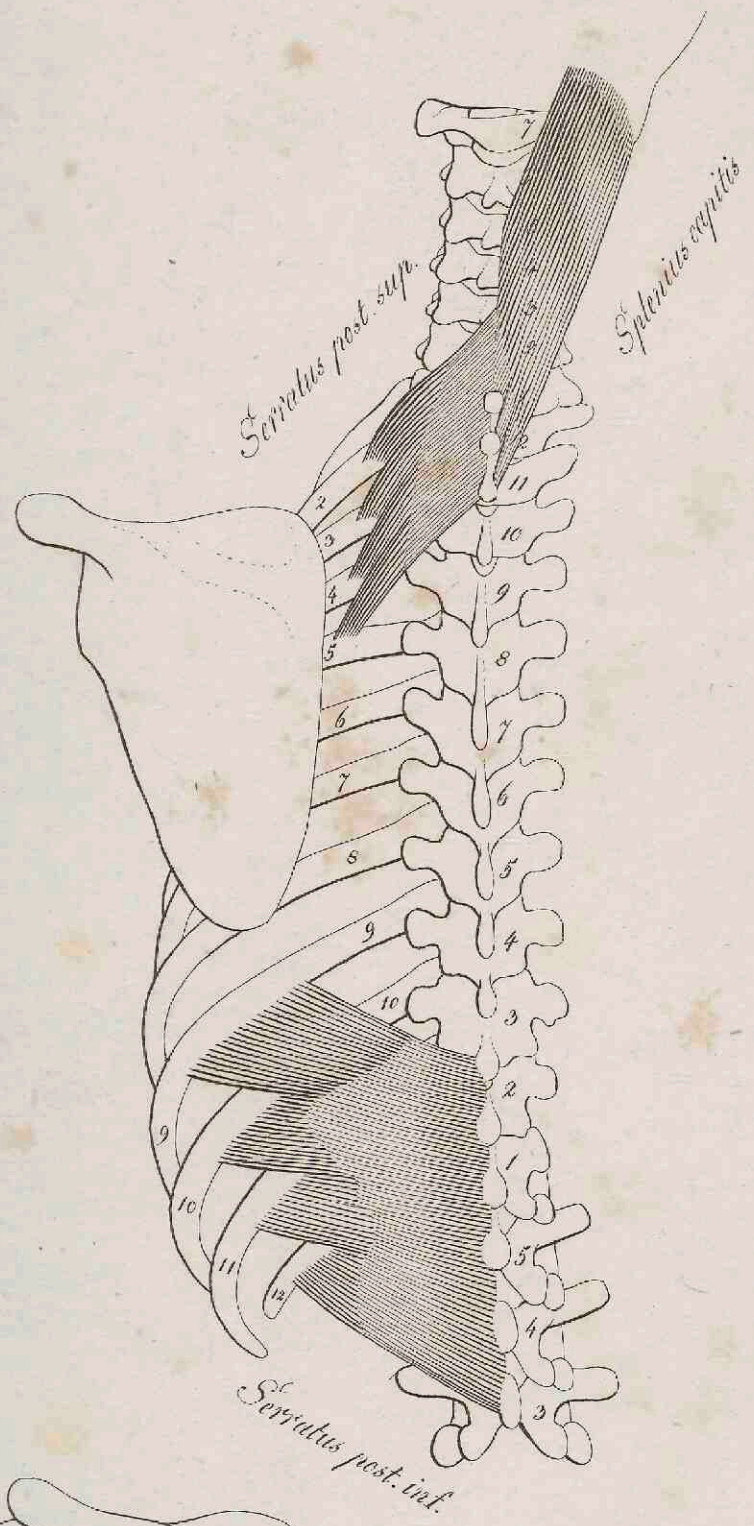
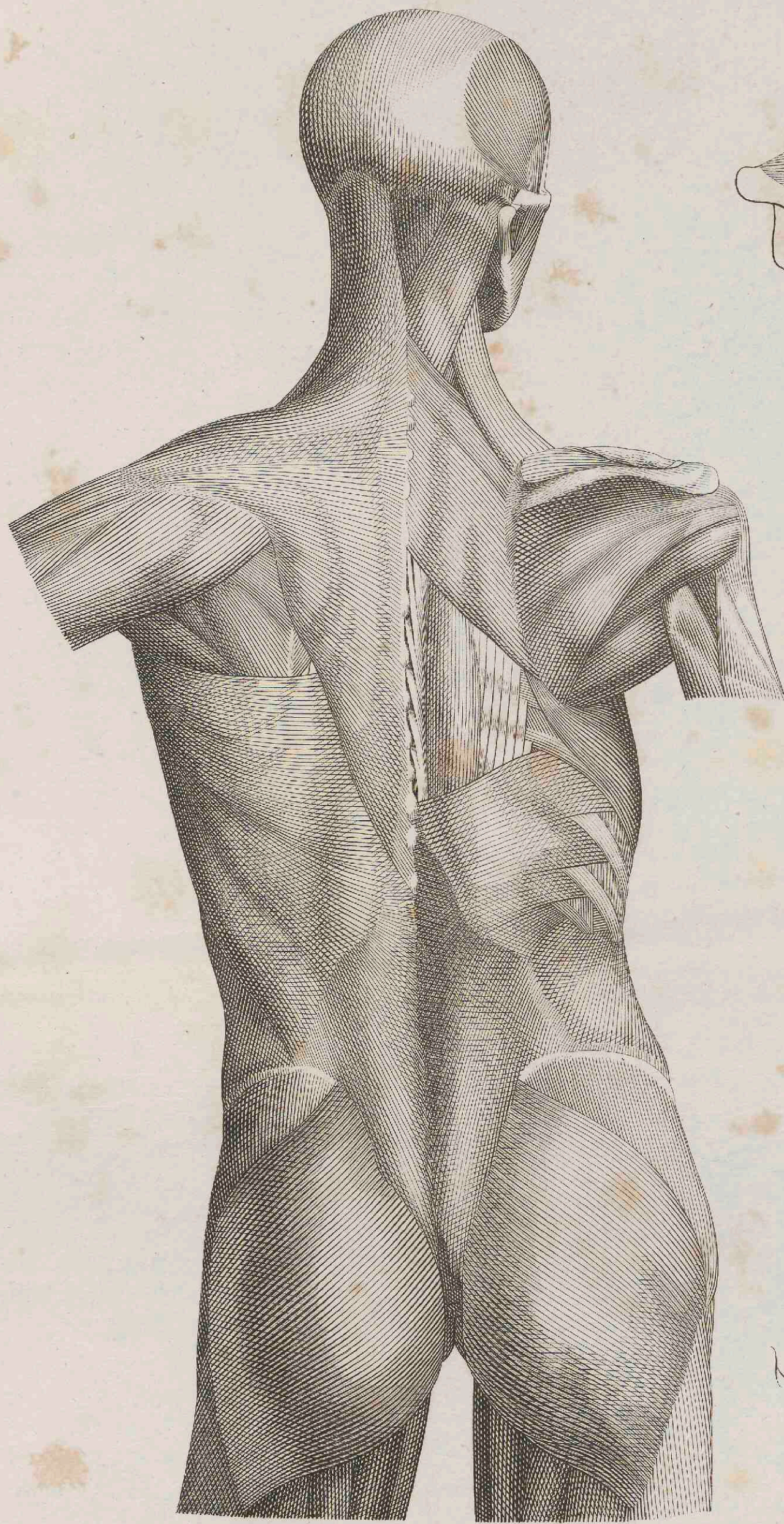
Subscapularis



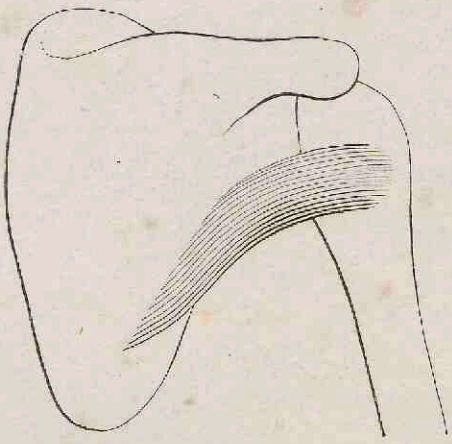
Supraspinatus



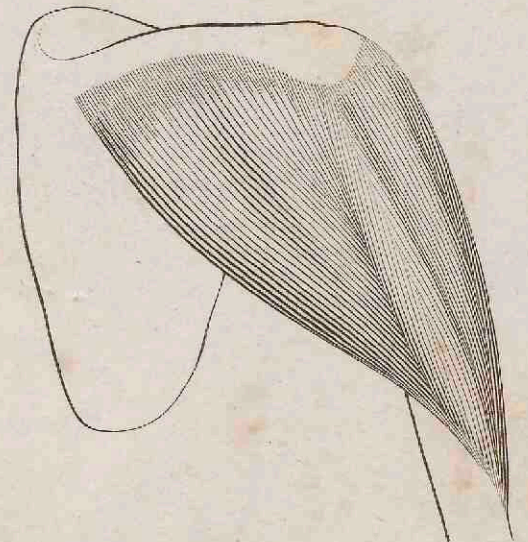
Quadratus lumborum



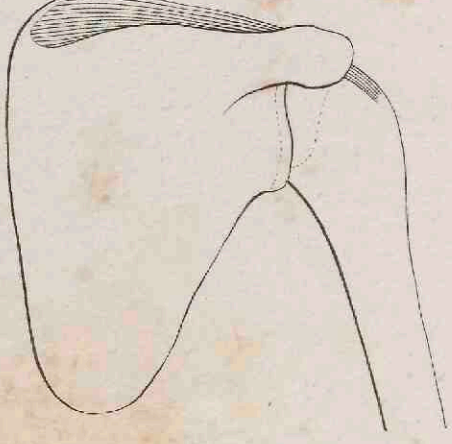
Teres major



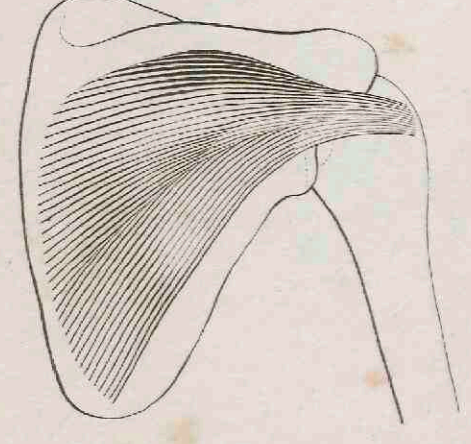
Teres minor



Deltoides

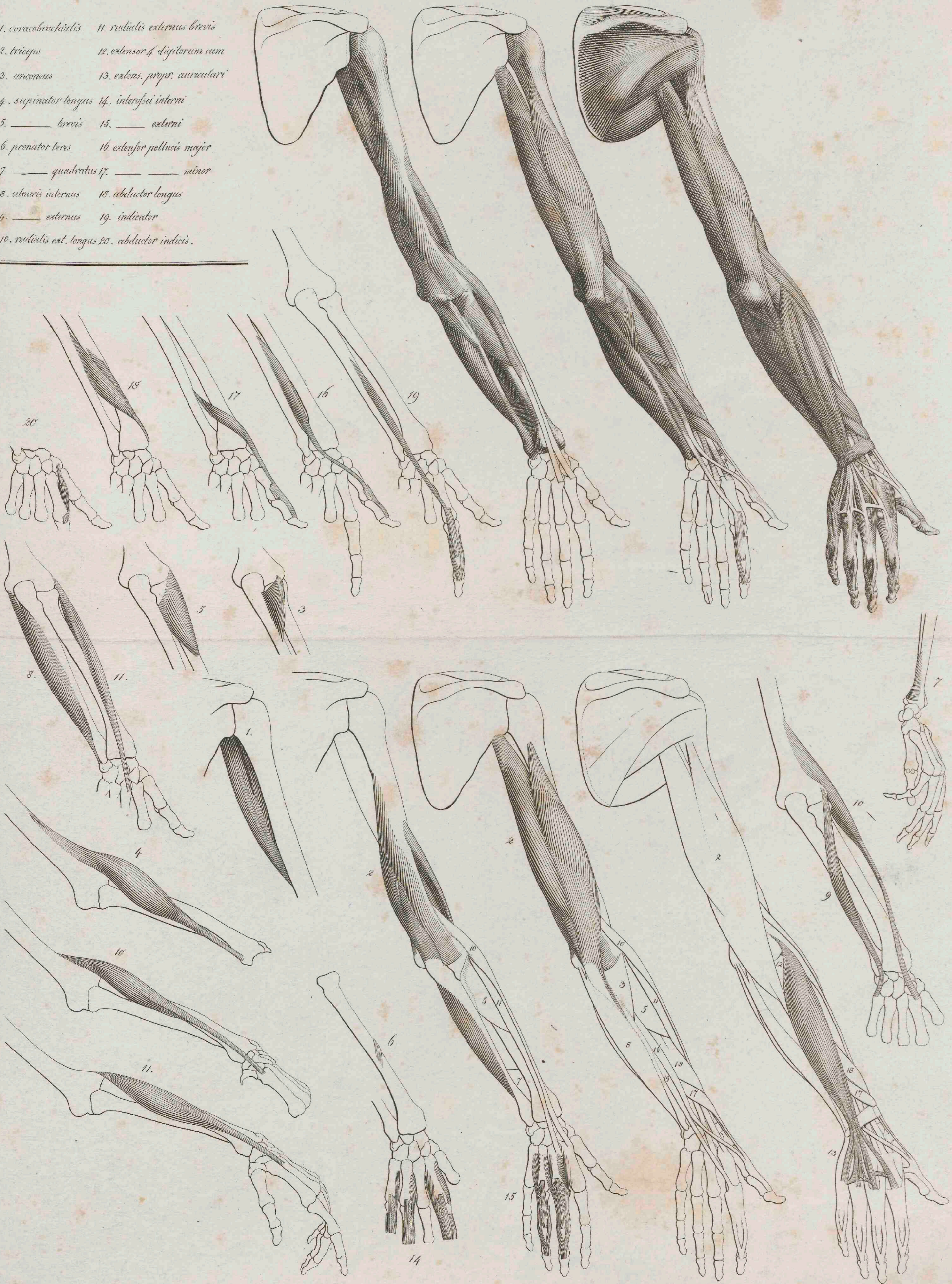


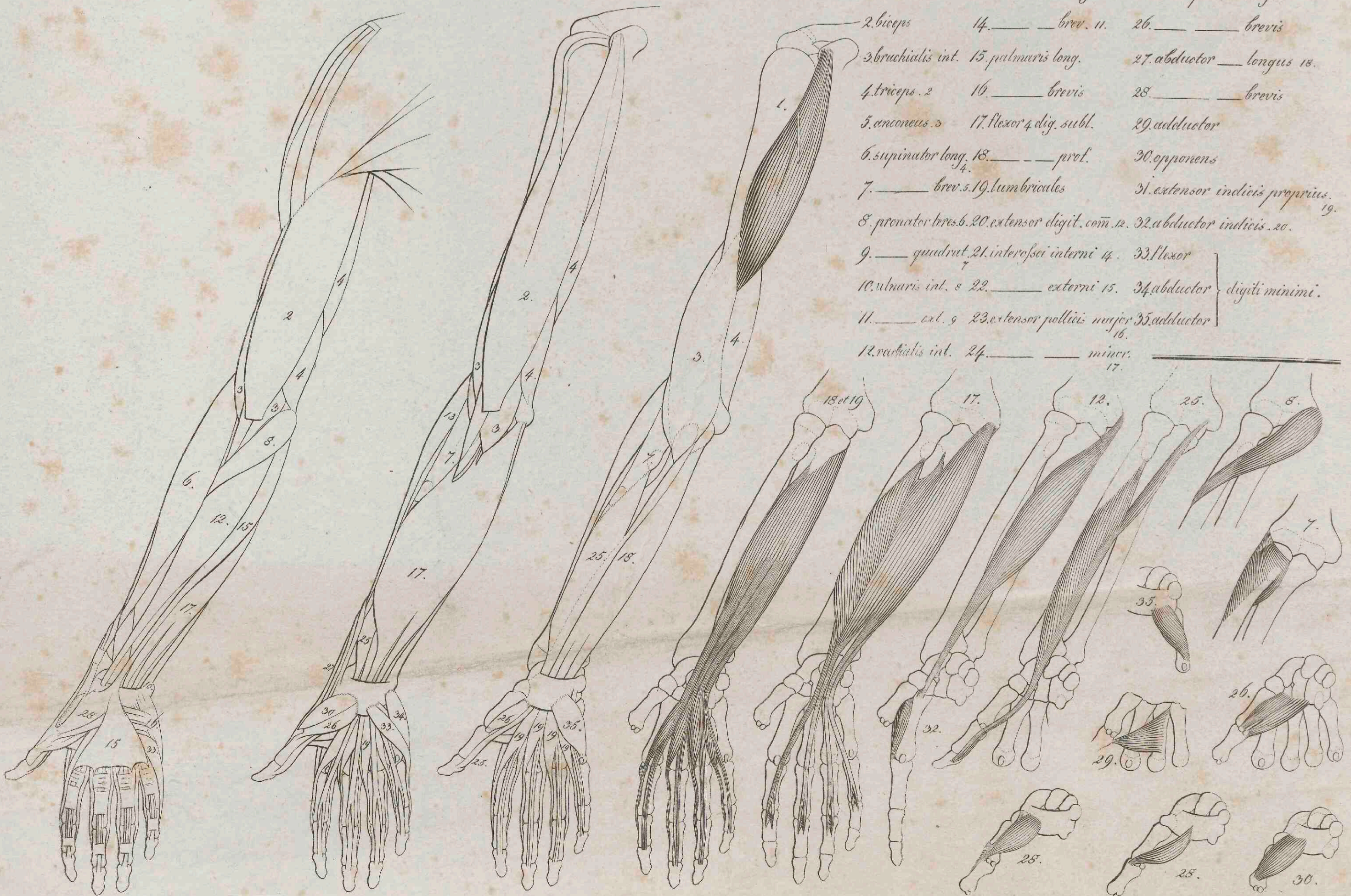
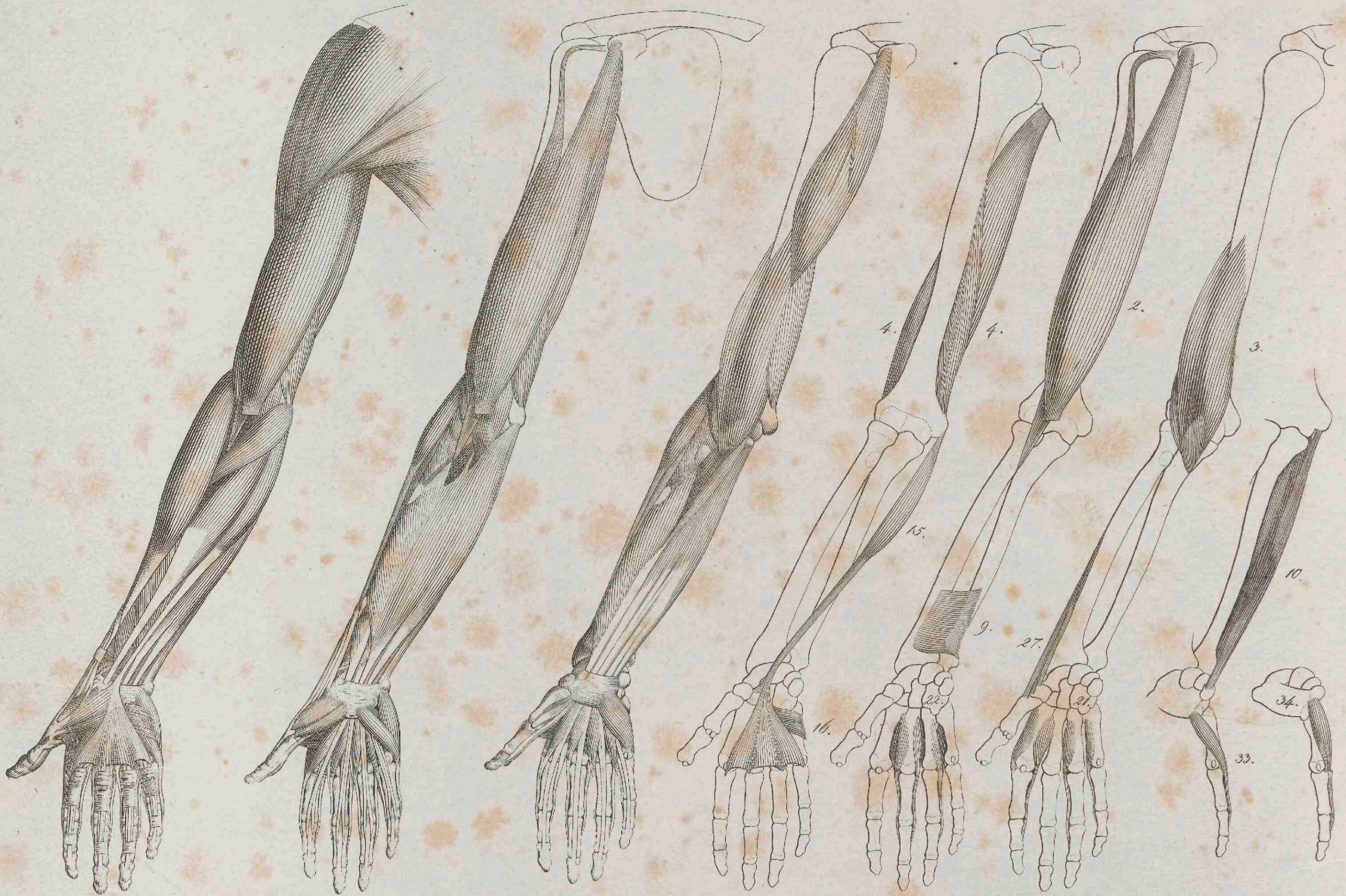
Supraspinatus



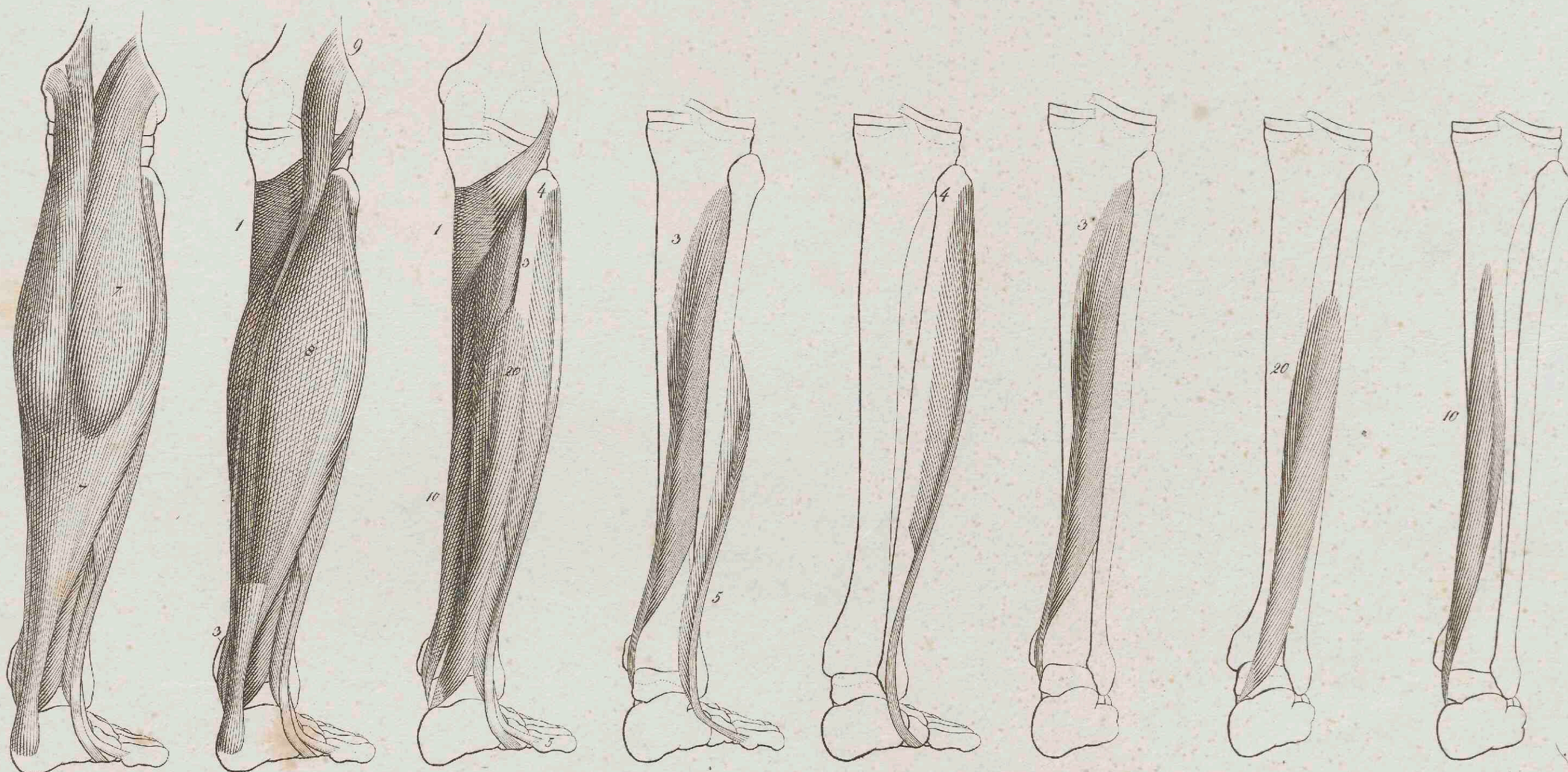
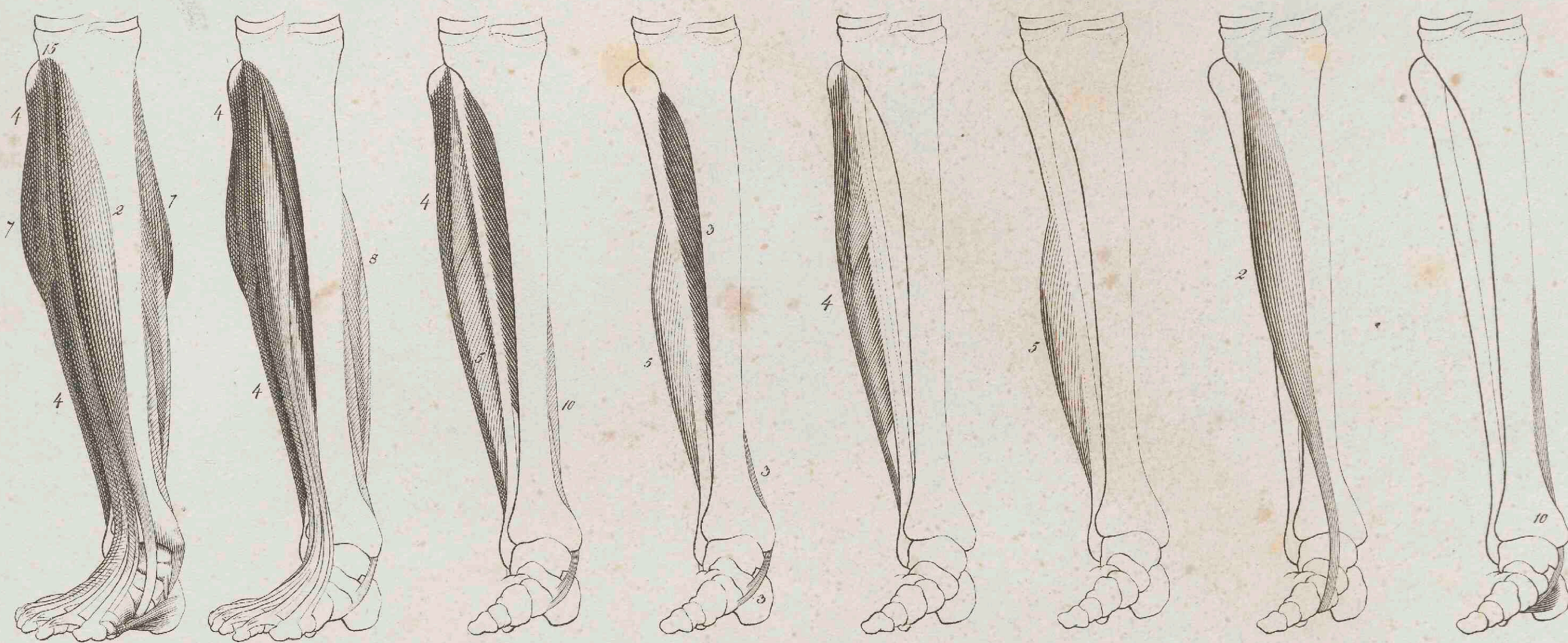
Infraspinatus

- 1. coracobrachialis
- 2. biceps
- 3. anconaeus
- 4. supinator longus
- 5. ——— brevis
- 6. pronator levis
- 7. ——— quadratus
- 8. ulnaris internus
- 9. ——— externus
- 10. radialis ext. longus
- 11. radialis externus brevis
- 12. extensor 4. digitorum cum
- 13. extens. propr. auriculari
- 14. interossei interni
- 15. ——— externi
- 16. extensor pollicis major
- 17. ——— minor
- 18. abductor longus
- 19. indicator
- 20. abductor indicis.



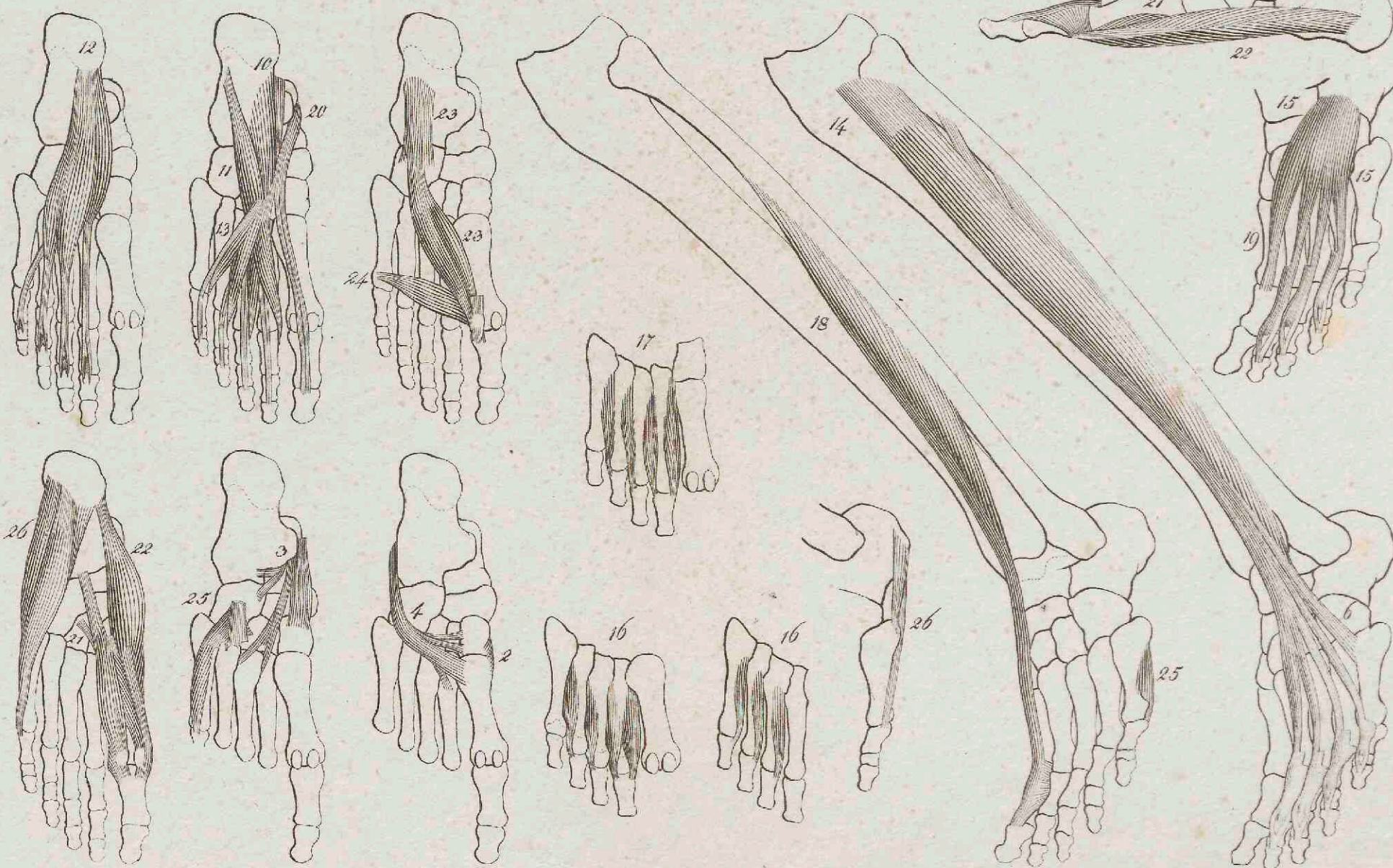


- | | | |
|--|---------------------------------|-----------------------------------|
| 1. coracobrachialis) 2. radial. ext. long. | 10. | 25. flexor pollicis longus |
| 2. biceps | 14. — — brev. 11. | 26. — — brevis |
| 3. brachialis int. | 15. palmaris long. | 27. abductor — longus 18. |
| 4. triceps 2 | 16. — — brevis | 28. — — brevis |
| 5. anconaeus 3 | 17. flexor 4 dig. subl. | 29. adductor |
| 6. supinator long. | 18. — — prol. | 30. opponens |
| 7. — — brev. 5. 19. lumbricales | | 31. extensor indicis proprius 19. |
| 8. pronator teres 6. | 20. extensor digit. com. 12. | 32. abductor indicis 20. |
| 9. — — quadrat. | 21. interossei interni 14. | 33. flexor |
| 10. ulnaris int. 8 | 22. — — externi 15. | 34. abductor digiti minimi. |
| 11. — — ext. 9 | 23. extensor pollicis major 16. | 35. adductor |
| 12. rectus int. | 24. — — minor 17. | |



Erläuterung.

- | | |
|------------------------------|----------------------------------|
| 1. popliteus | 14. extensor 4. digitorum longus |
| 2. tibialis anticus | 15. _____ brevis |
| 3. _____ posticus | 16. interossei interni |
| 4. peroneus 1. minor | 17. _____ externi |
| 5. _____ 2. major | 18. extensor hallucis longus |
| 6. _____ 3. lateralis | 19. _____ brevis |
| 7. gemelli | 20. flexor _____ longus |
| 8. solus | 21. _____ brevis |
| 9. plantaris | 22. abductor _____ |
| 10. flexor 4. digiti longus. | 23. adductor _____ |
| 11. (caro accessoria) | 24. transversus pedis |
| 12. flexor brevis | 25. flexor digiti minimi |
| 13. lumbricales | 26. abductor. |



OESTERREICHER'S

Anatomische Steinstücke.

Vierte Abtheilung

Organe

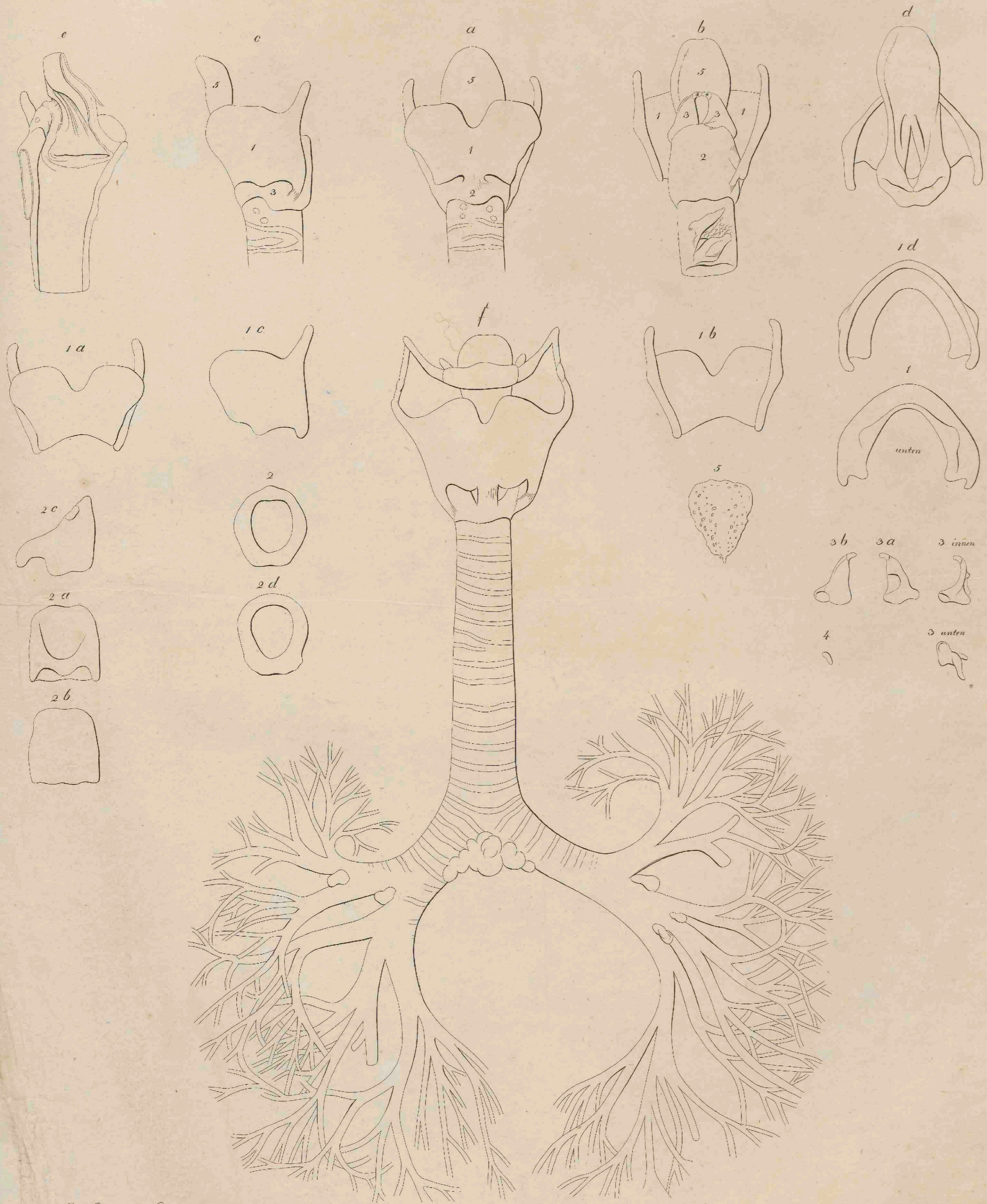
des
Menschlichen Körpers.

München

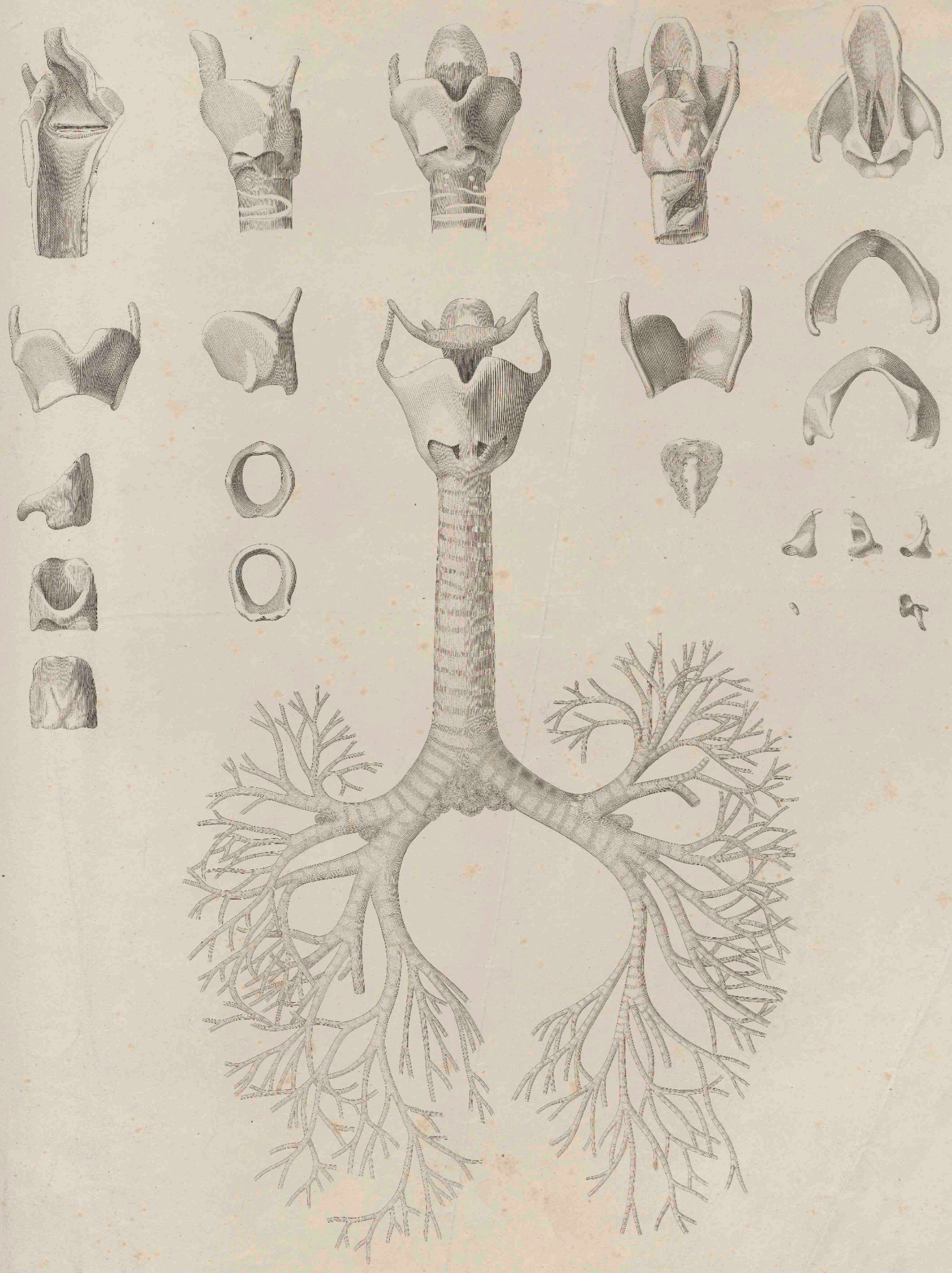
1829

Kehlkopf und Luftröhre

nach Soemmerring



Die Knorpeln des Kehlkopfes in ihrer Verbindung, und zwar a von vorne, b von hinten, c von der Seite, d von oben, so dass man die Stimmritze sieht, e im Durchschnitte und f in Verbindung mit dem Zungbeine und der Luftröhre betrachtet.
 Die einzelnen Knorpeln und zwar 1 der Schildknorpel / cartilago thyroidea / 2 der Ringknorpel / c cricoidea s. annularis / 3 die gipfbüchsenförmigen / c aryepiglotticae s. guttales / 4 die Santorinischen Knorpel / c. Santorinianae / und 5 der Nadelknorpel / Epiglottis /



Zunge und Kehlkopf

nach Sandifort.

- a, a, a, a. integumenta
- b, b, b, b. conceptaculum cerebri
- c, c. canalis pro medulla spinali
- d. crista galli
- e. sella turcica cum gland. pituitaria
- f. septum sinus frontales distinguens
- g. septum inter sinus sphenoidales medianum
- h. processus anterior ossis occipitis
- i. basis ossis multiformis
- k. arcus anterior atlantis
- l. arcus posterior
- m. dens epistrophei
- n, n, n, n. corpora epistrophei et quatuor vertebrarum
- o, o, o, o. processus spinosi
- p, q, r. lacunae narium
- s, t. fundus narium
- u. processus filiaceus ossium maxillarum
- v. alveolus dentis incisivi sinistri medii
- w. dens incisivi medius dexter
- x. idem maxillae inferioris.
- y. pars anterior mandibulae
- z. os hyoides
- 1. septum narium
- 2. lingua
- 3. ejus frenulum
- 4. musculus genio-glossus
- 5, 5. substantia linguae
- 6. interior pars palati
- 7. palatum molle
- 8. uvula
- 9. pars amygdalae dextrae
- 10. apertura posterior naris dextrae
- 11. tubae Eustachianae orificium
- 12. pars posterior et superior pharyngis
- 13. cellulosa
- 14. pharyngis pars, cui constrictores accumbunt.
- 15. oesophagus
- 16. superficies interior epiglottidis
- 17. cellulosa pingui repleta
- 18. cartilago thyroidea
- 19. cricoidea pars anterior
- 20. pars posterior
- 21. cart. arytenoidea dextra
- 22. ventriculus dexter laryngis
- 23. aspera arteria
- 24. glandula thyroidea
- 25. musculus geniohyoideus
- 26. m. digastricus
- 27. sternohyoideus et thyroideus.

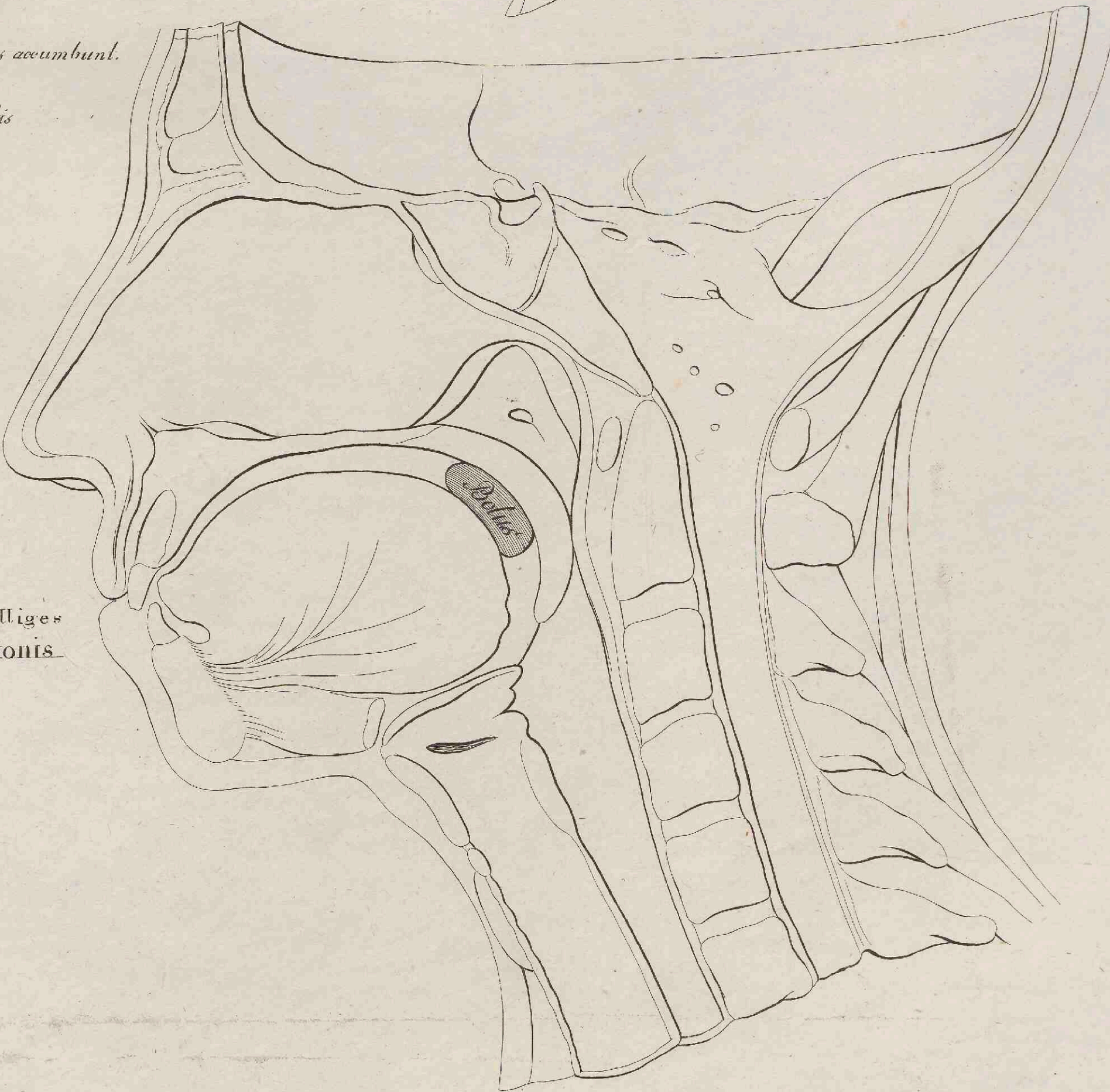
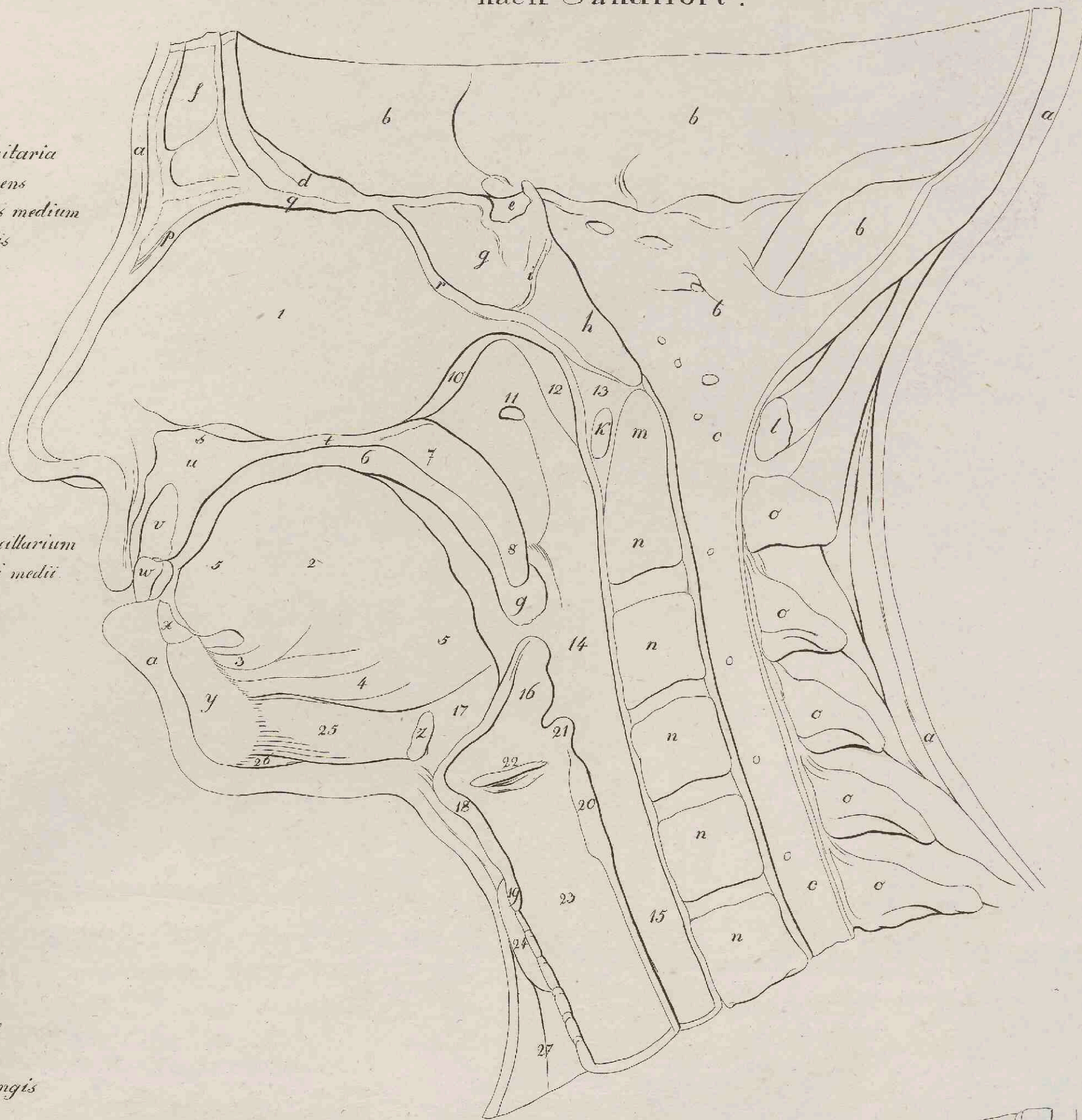
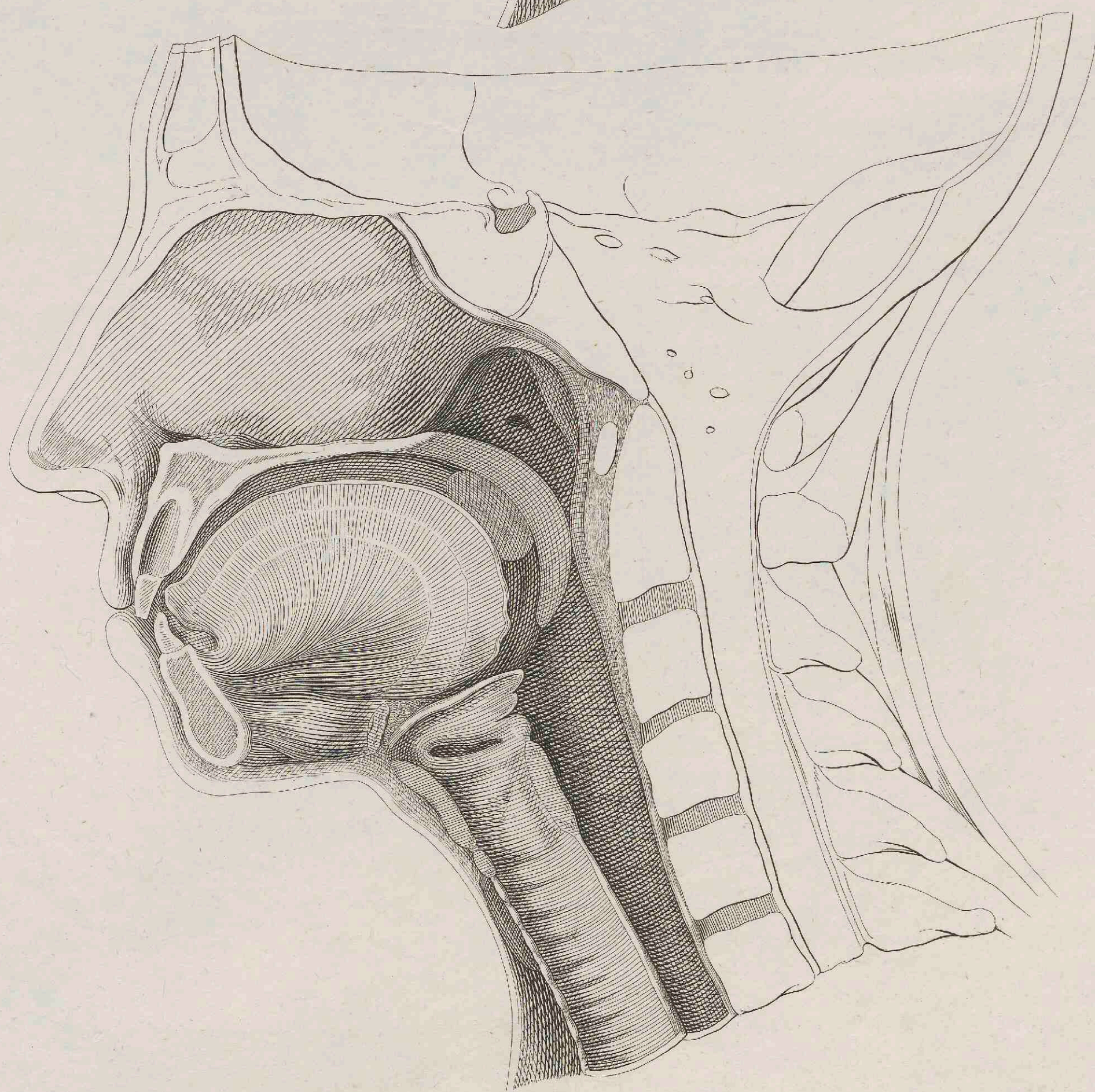
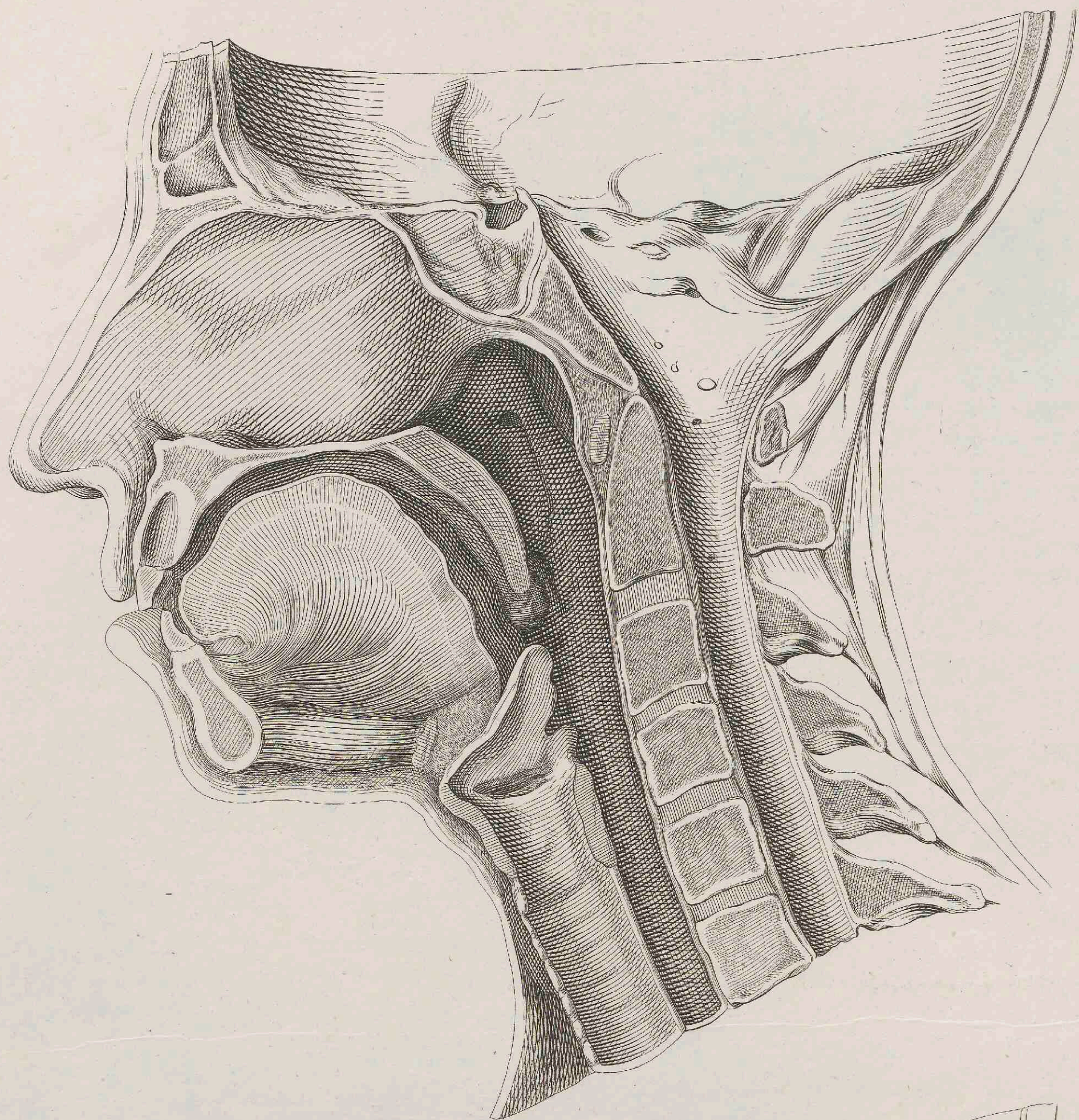
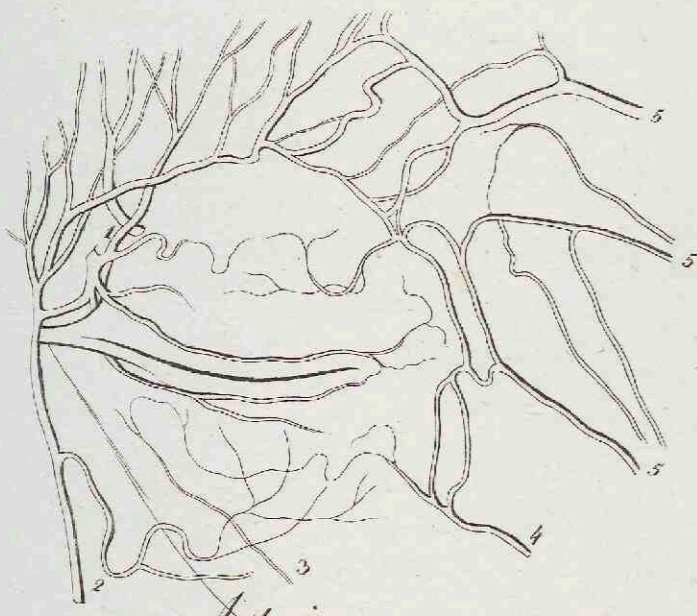


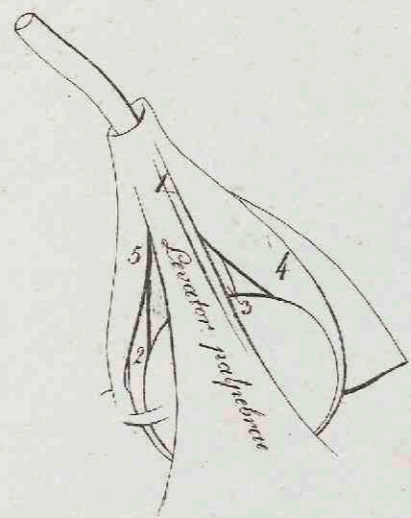
Fig. 2. depingit partes in deglutitionis nexu.

Compara sedulo et intelliges mechanismum deglutitionis.

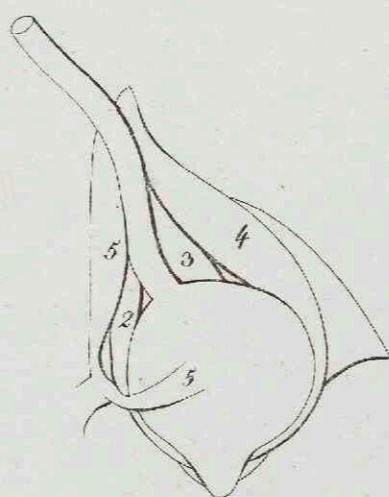





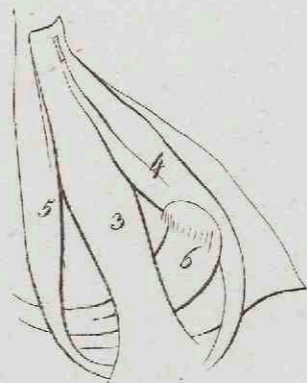
Arterien
1. Aste der Augenarterie (ophthalmica).
2. Asten der Arterien der Iris.
3. Ast der Arterien der Chorioidea.
4. Ast der Arterien der Netzhaut.
5. Ast der Schläfenarterie.




Gerade, Recti:
1. oberer, obliquus.
2. innerer, adducens.
3. unterer, depressus.
4. äußerer, abducens.



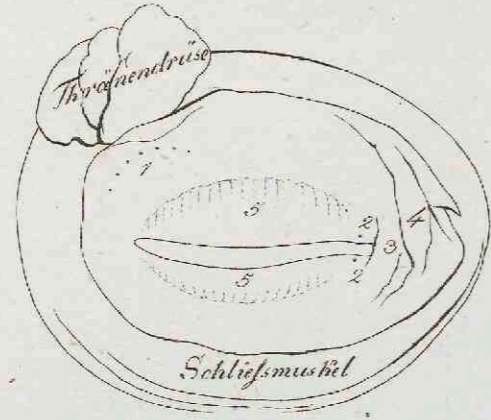
Muskeln
Schieb, Obliqui:
5. oberer, trochlearis.
6. unterer.




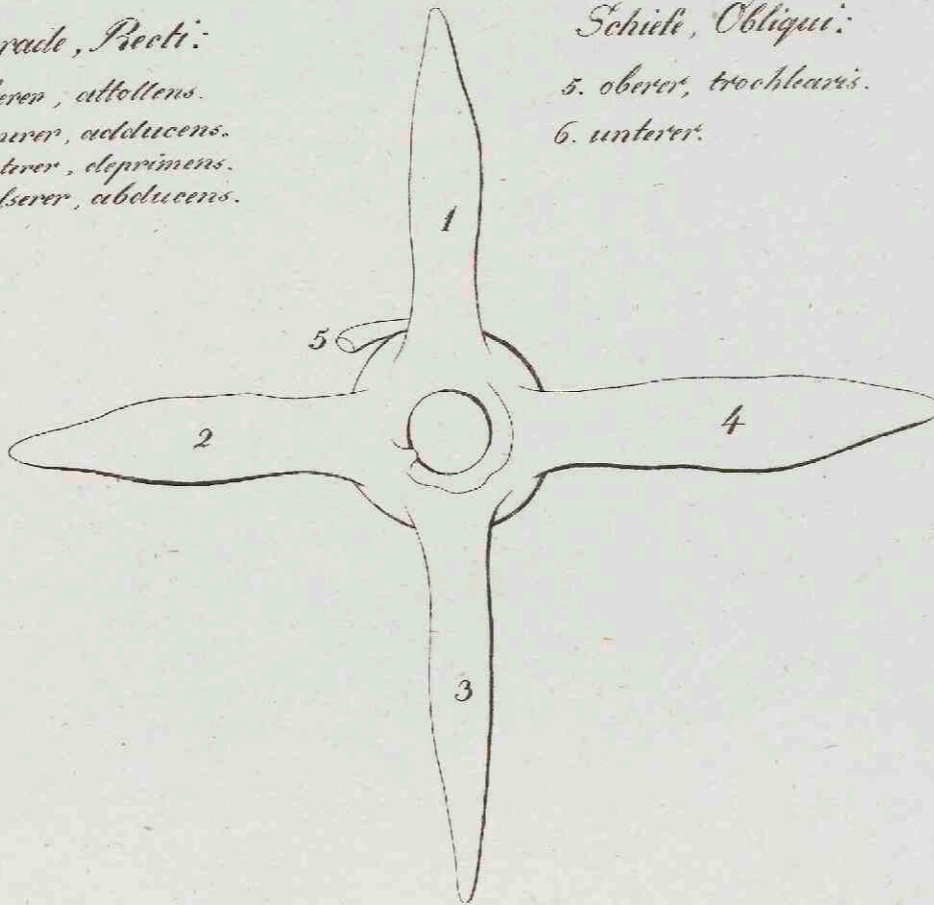
Nerven des Auges aus dem ersten und zweiten Aste des V. Nerven.



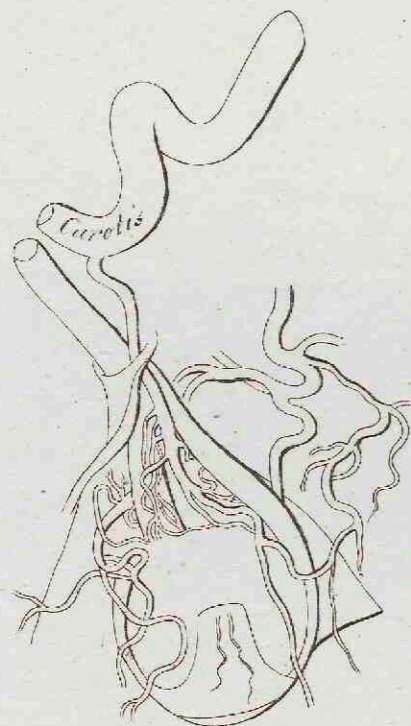
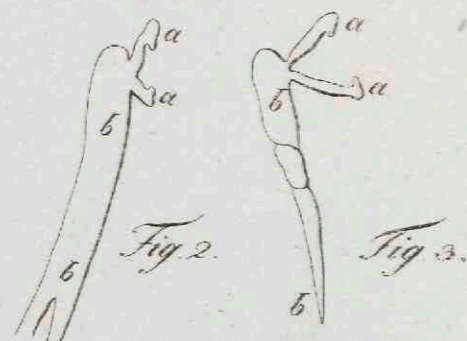
Augenbraunenhaare,
Augenwimperhaare,
viermal vergrößert.



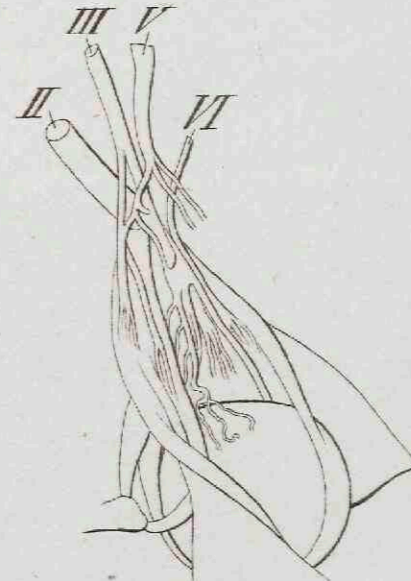
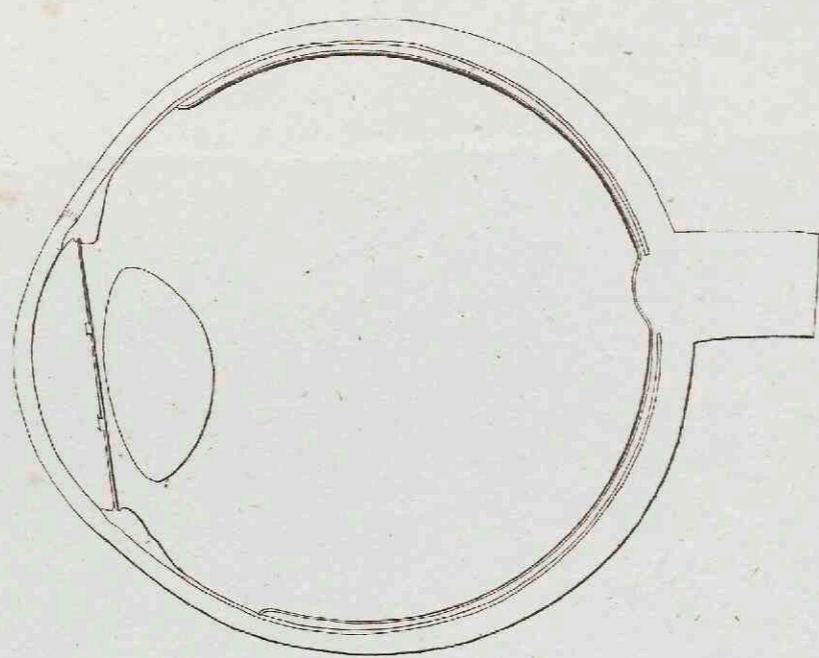
Augenlider von hinten angesehen.
1. Mündungen der Ausführungsgänge der Drüse.
2. 2. Thränenpunkte.
3. Thränenröhre.
4. Hornförmiges Hautläppchen.
5. Schmalzdrüsen.



Thränenableiter.
und zwar a die Thränenhäutchen, b der Thränenwall.
T 1 von vorne, 2 v. der Nasenhöhlenseite, 3. von innen.



Augenarterie. Arteria ophthalmica.



Augenhochblennerven. V. Sehnerven.

A. Vorderer Kammer

B. Hintere

++ Mittlere

C. Linse

D. Sehnerve

1. Hornhaut

2. Regenbogenhaut

3. Harthaut

4. Schleimschicht, welche nach vorne sehr verdickt

5. das Strahlenband bildet

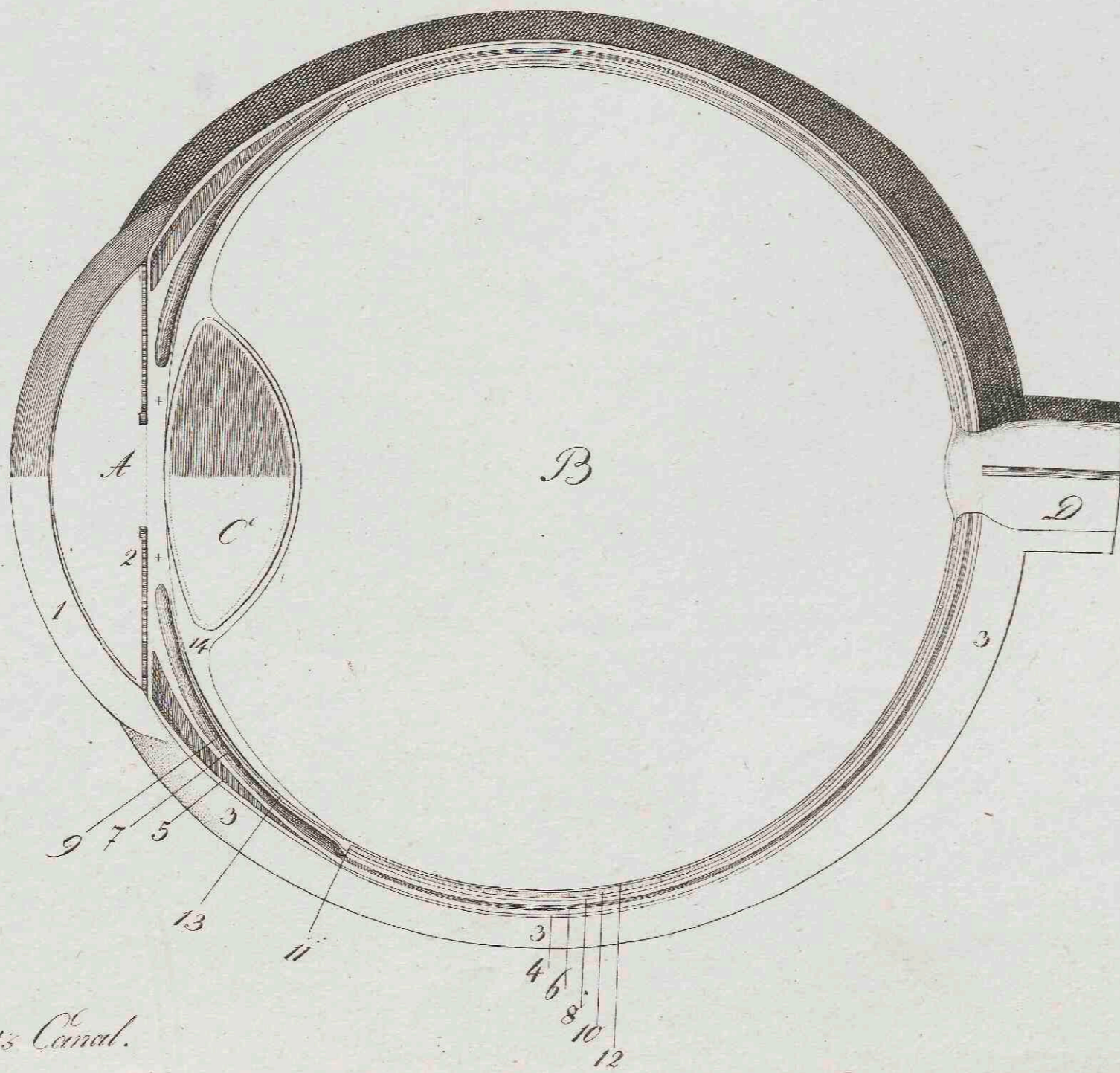
6. Gefäßhaut

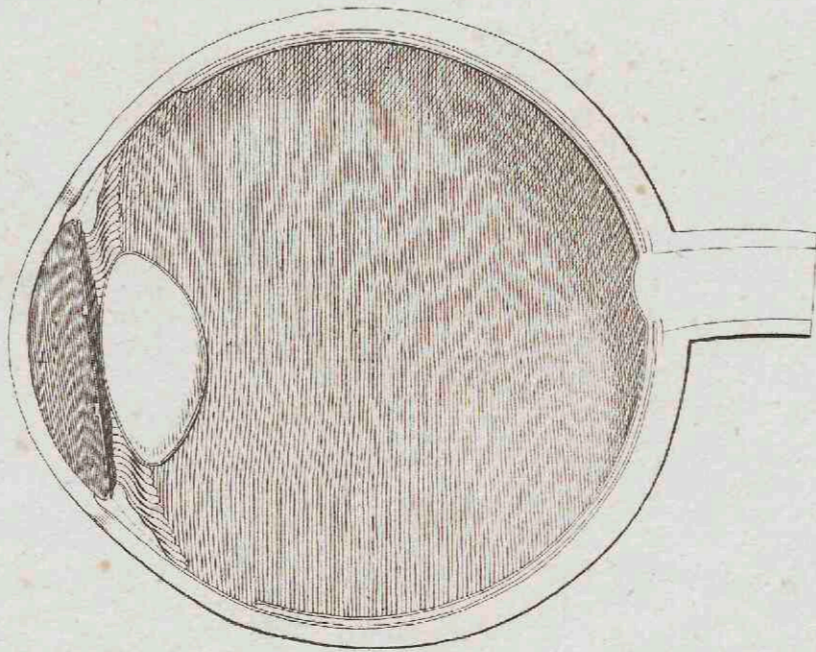
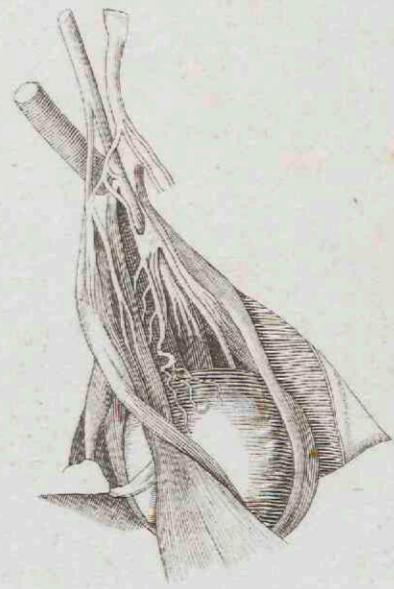
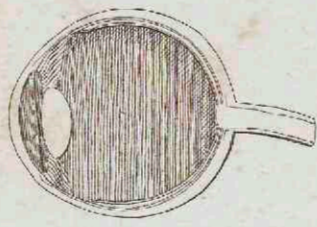
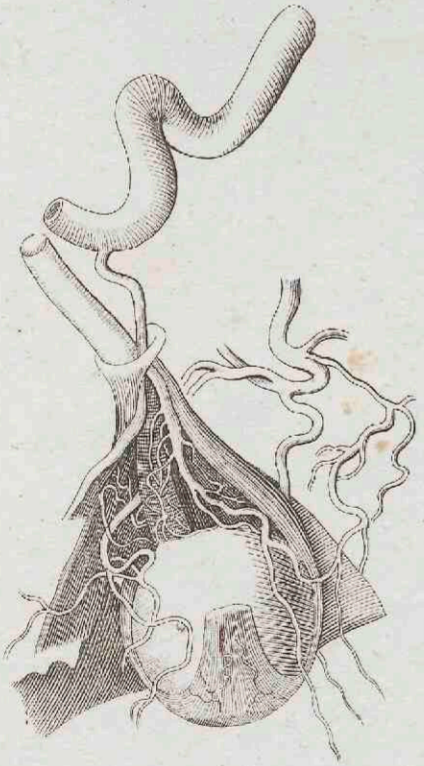
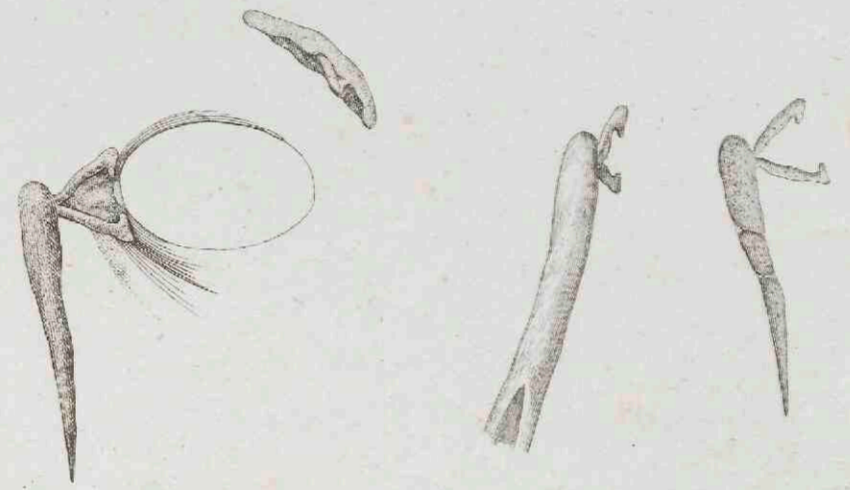
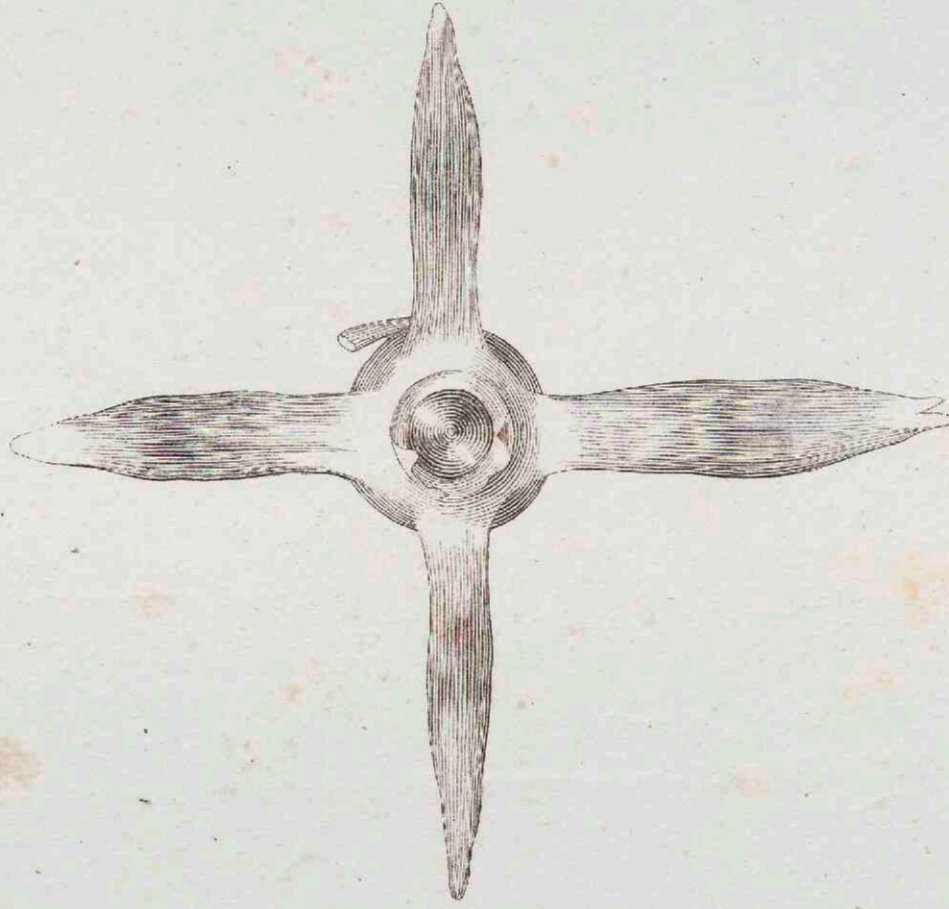
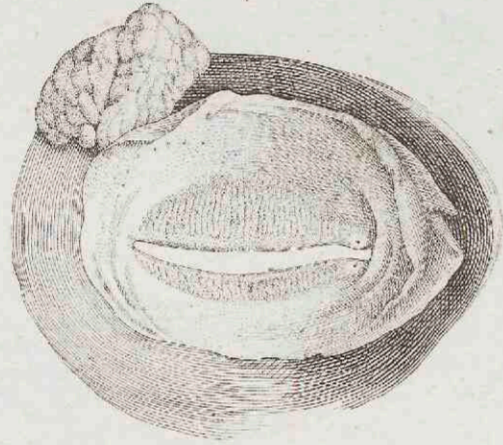
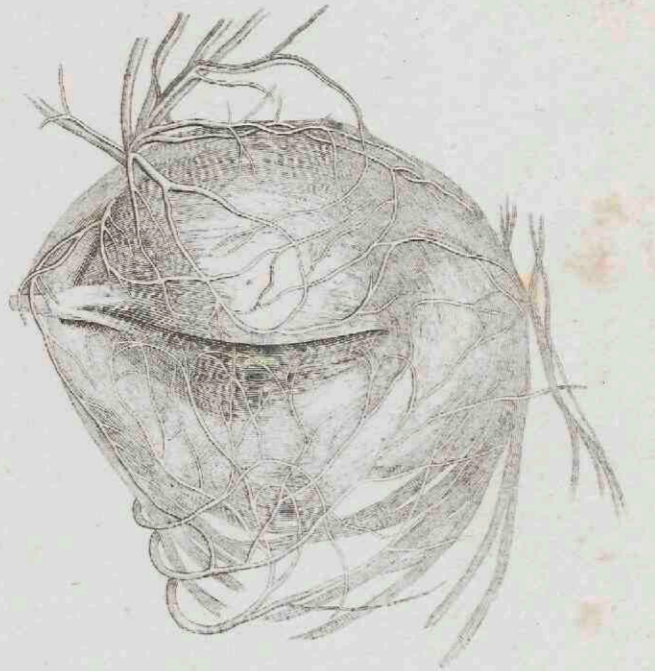
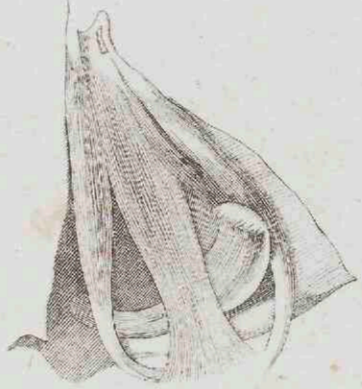
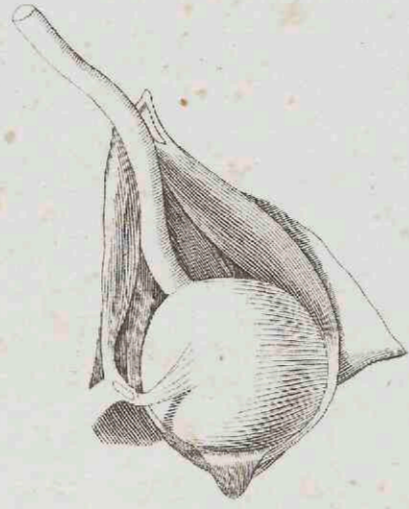

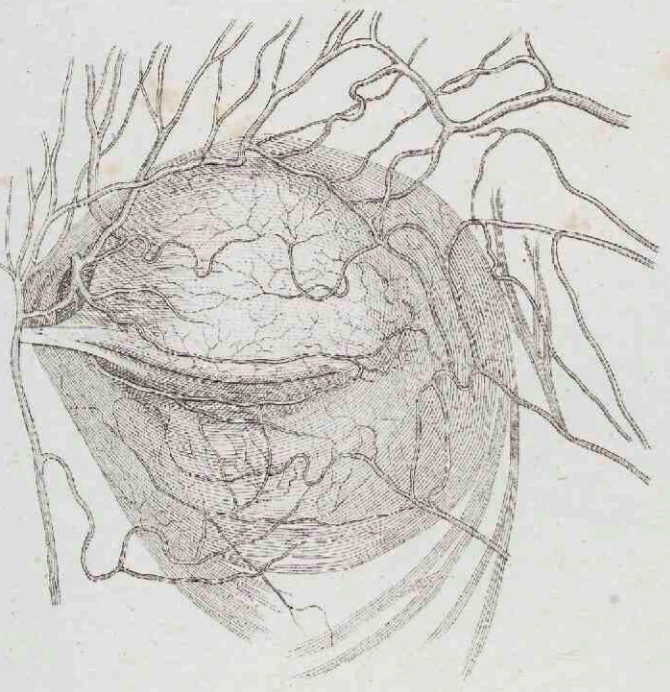

7. Strahlenfortsätze

8. Schleimschicht, welche vorwärts zu 9 läuft

10. Netzhaut, die bei 11 aufliegt

12. Glashaut. 13. Strahlenblättchen 14. Petit's Canal.

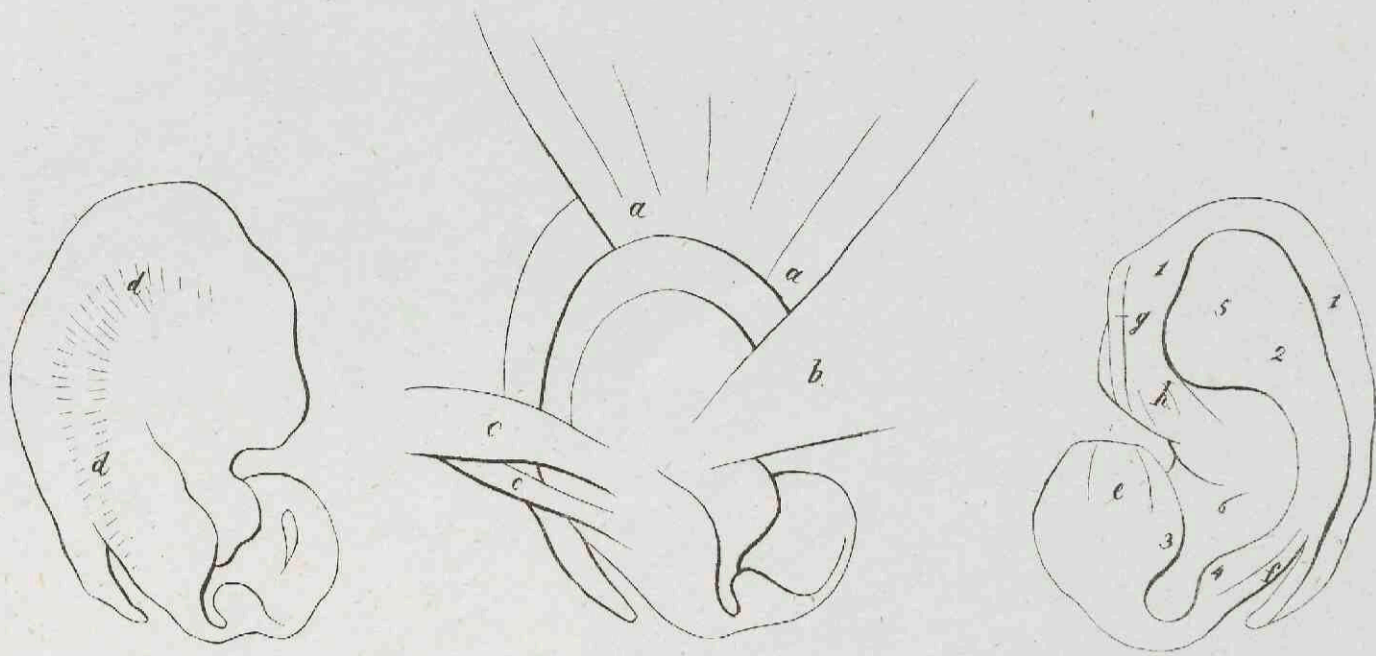




Das äußere Ohr.

Knorpel.

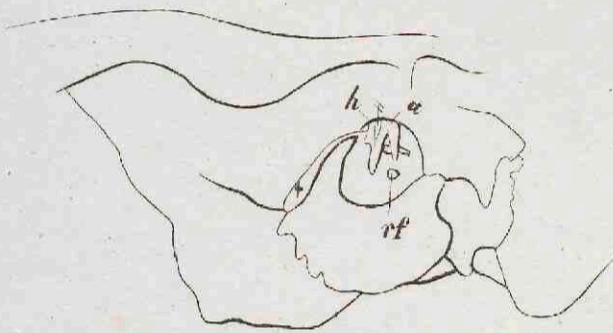
- 1 Leiste
- 2 Gegenleiste.
- 3 Eche.
- 4. Gegenache.
- 5. Platen.
- 6. Muschel.



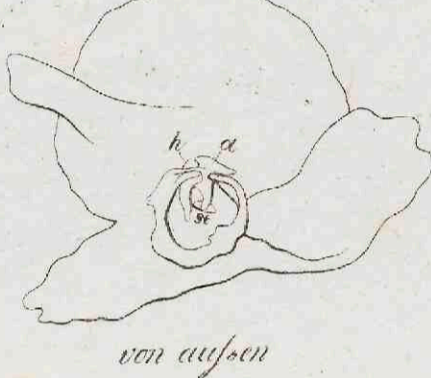
Muskeln.

- a. Aufwärts.
- b. Vorwärts.
- c. Rückwärtszieher.
- d. Quermuskel.
- e. M. d. Eche.
- f. Gegenache.
- g, h. großer u. kleiner Listemuskel.

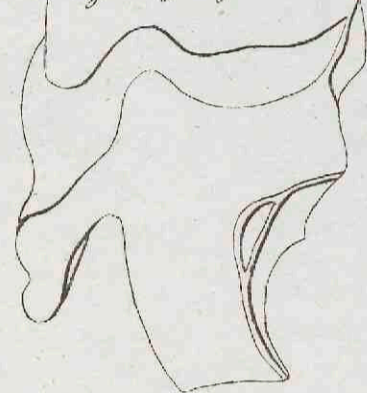
Äußerer Muskel des Hammers + Erschütterer des Paukenohrs.




Knochenring.



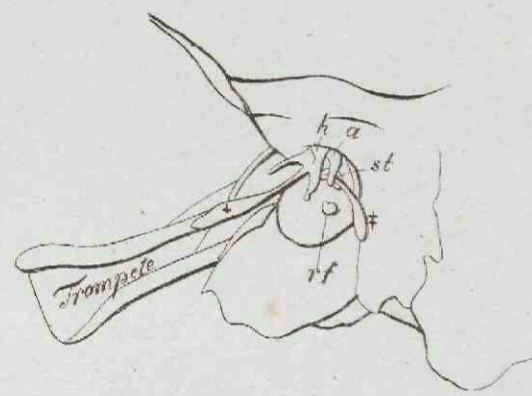
Windungen des Gehörganges.



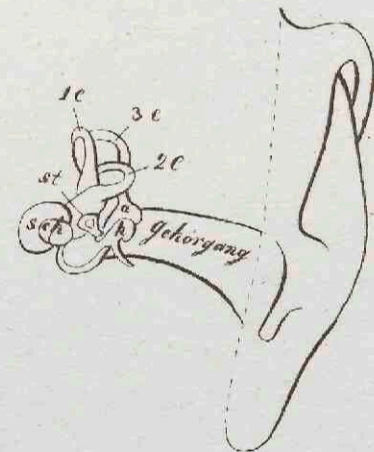
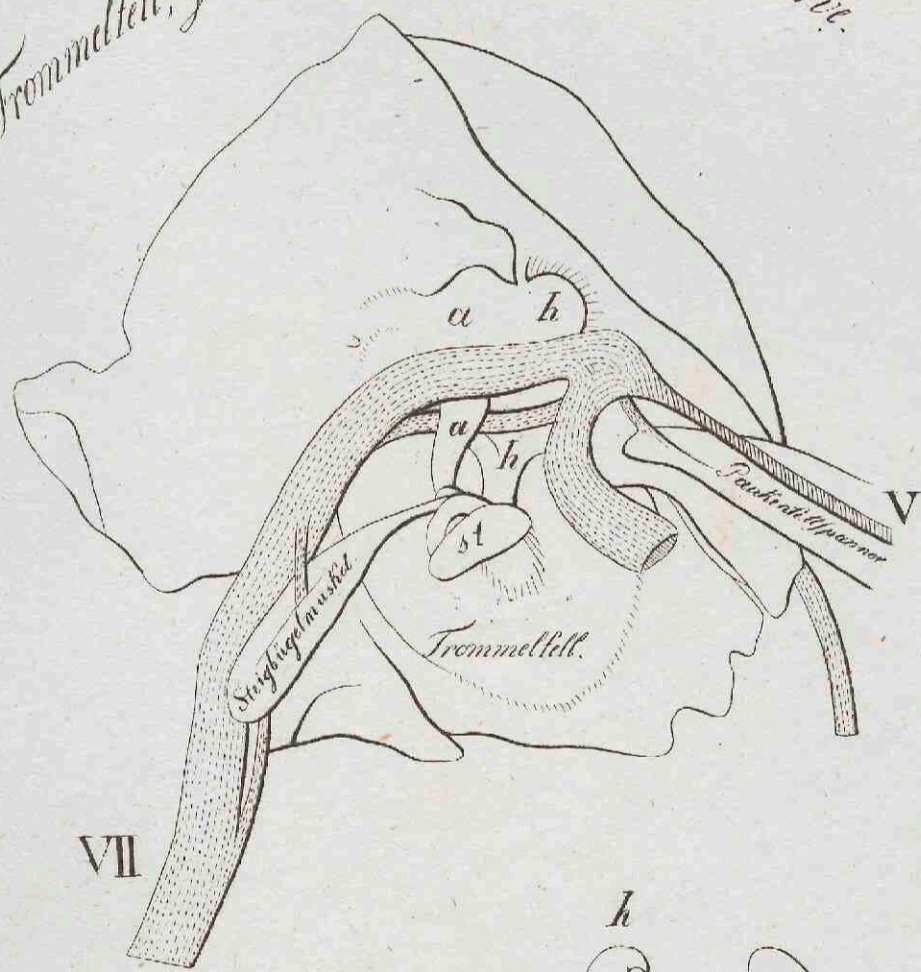
Knochenring.



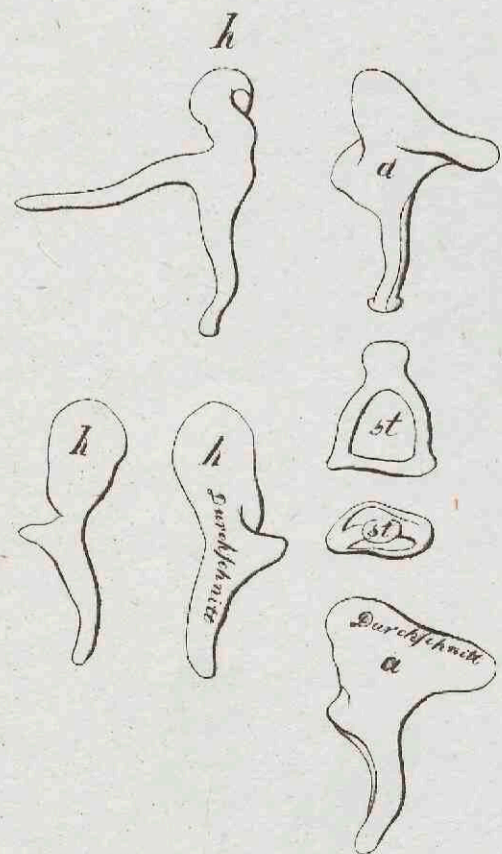
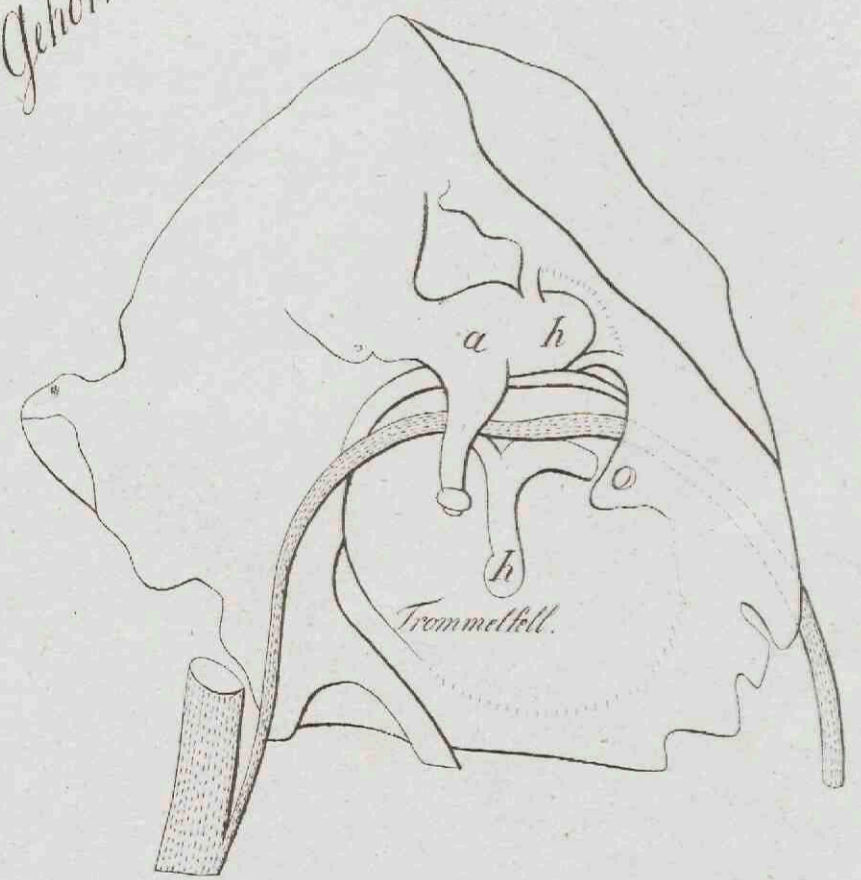
Paukenohrs-Steigbügelmuskel



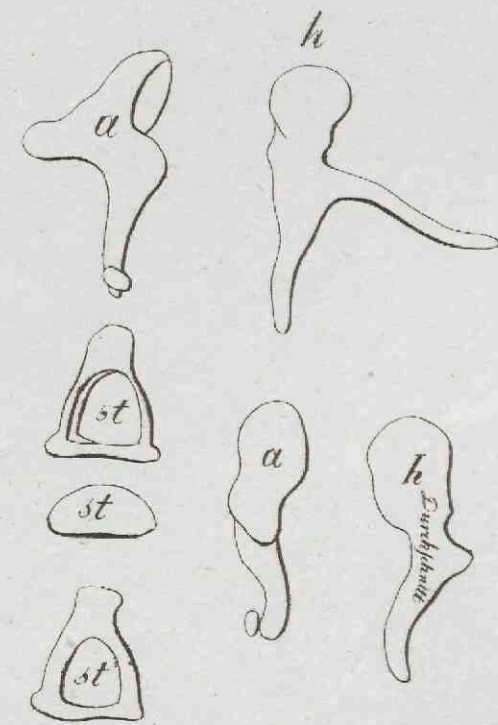
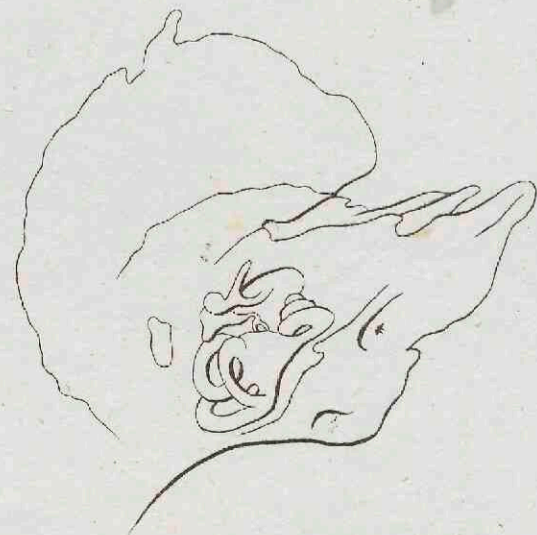Trommelfell, Gehörknochen, Muskeln, Antlitznerv.



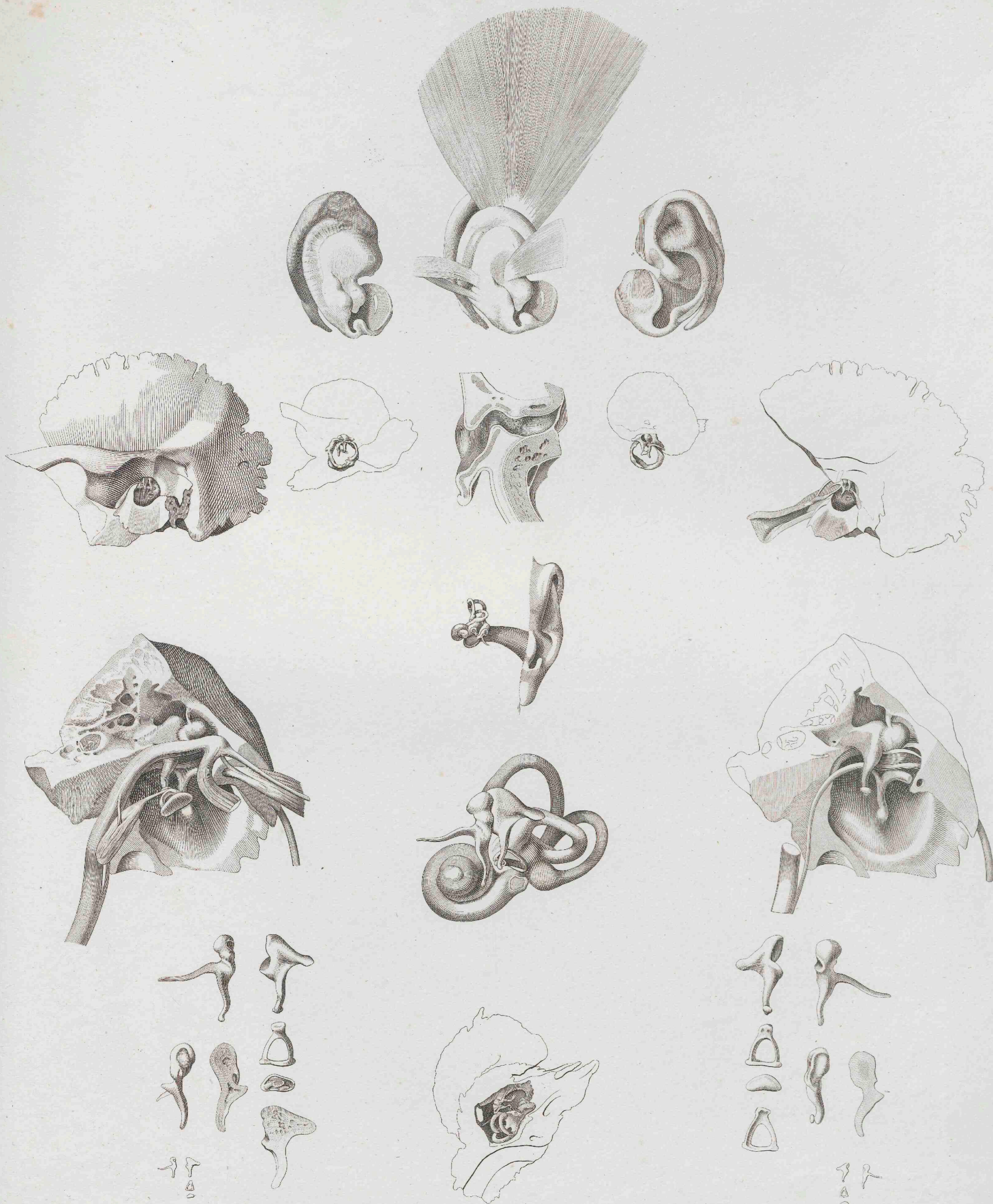
Gehörknochen, Paukenohrsaiten (Chorda).



Das Hörorgan im Felsenbein.




Erklärung: h Hammer, a Anvil, st Steigbügel, sch Schwächte, v Vorhol, 1, 2, 3, 4, 5, 6, vorderer, äußerer, hinterer Canal, rf rundes Fenster, * Canal des Hörz. u. Antlitznerven.

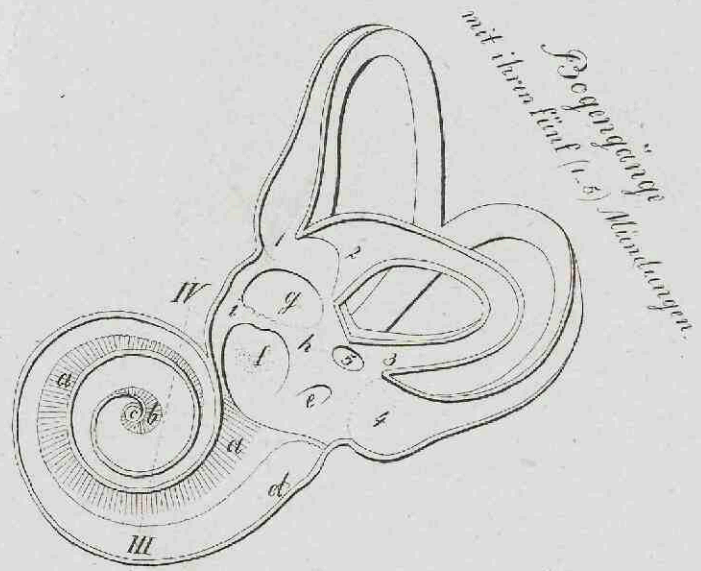


Das Ohr,

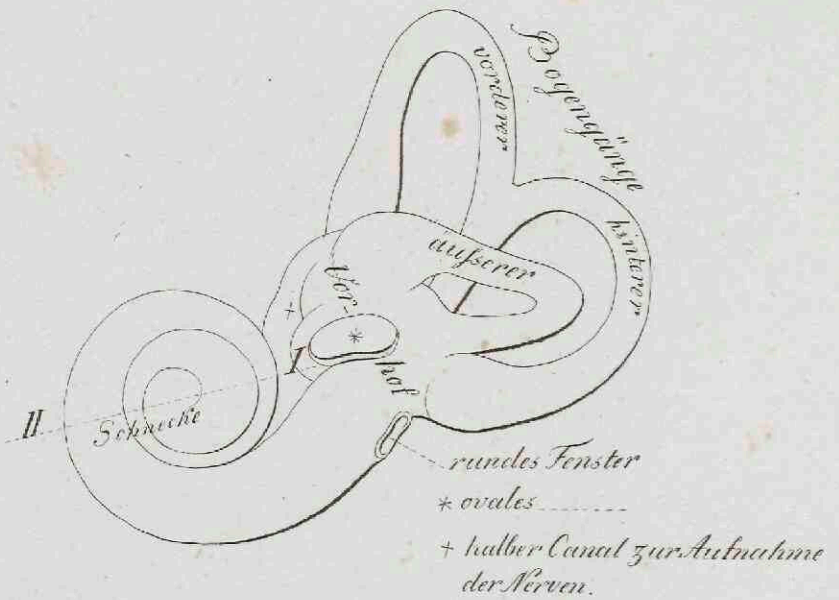
nach Soemerring und Saunders.



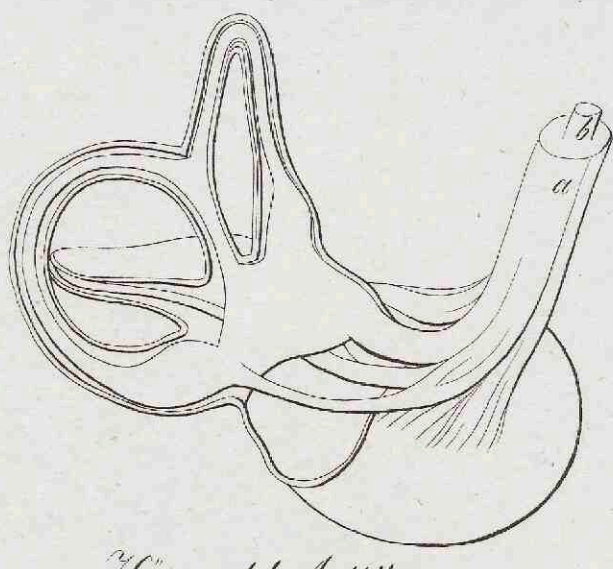
Die 4 Zonen des Spirallabyls: 1. knöcherne, 2. durchsichtige
3. bläsige, 4. schleimige
a. sphärisches Säckchen, b. gemeinsamer Schlauch, mit dem
die 3 Bogengänge in Verbindung stehen.




a Spirallblatt, b Haken abgaben, c Mittelpunktes Trichters,
d Mündung d. Wasserleitung der Schnecke, e des Vorboles,
f runde Vertiefung mit peripherem Grunde, g ovale Vertiefung,
h erhabener Rücken, der mit der Pyramide i entligt.



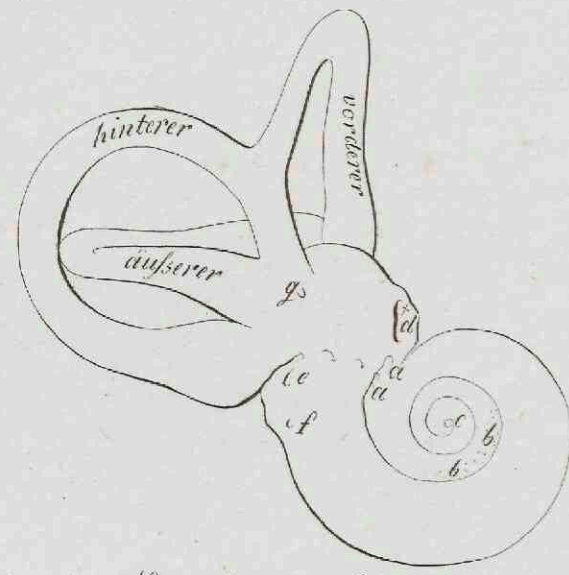
II Schnecke
rundes Fenster
+ ovales
+ halber Canal zur Aufnahme
der Nerven.



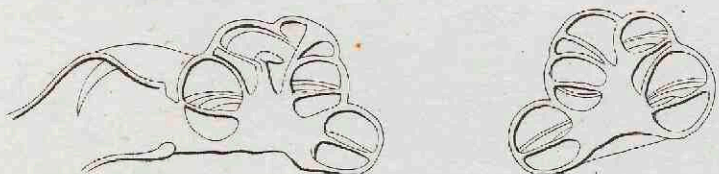
a Hör- und b Antlitznerve.



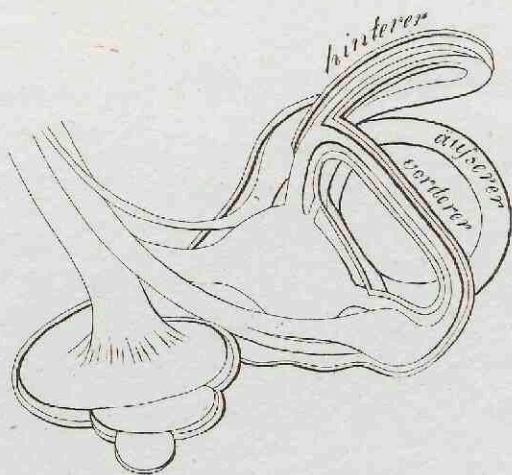
+ ovales Fenster




a Löcher für d. Nerven des sphärischen Säckchens, b. für Nerven u. Gefäße,
c Mündung des Spindelkanals, d. Säckchen des Canals für die Nerven
der beiden Blöcken des vorderen u. äußeren Ganges, e. des Wehels u.
hinteren Ganges, f Wasserleitung d. Schnecke, g. des Vorboles.



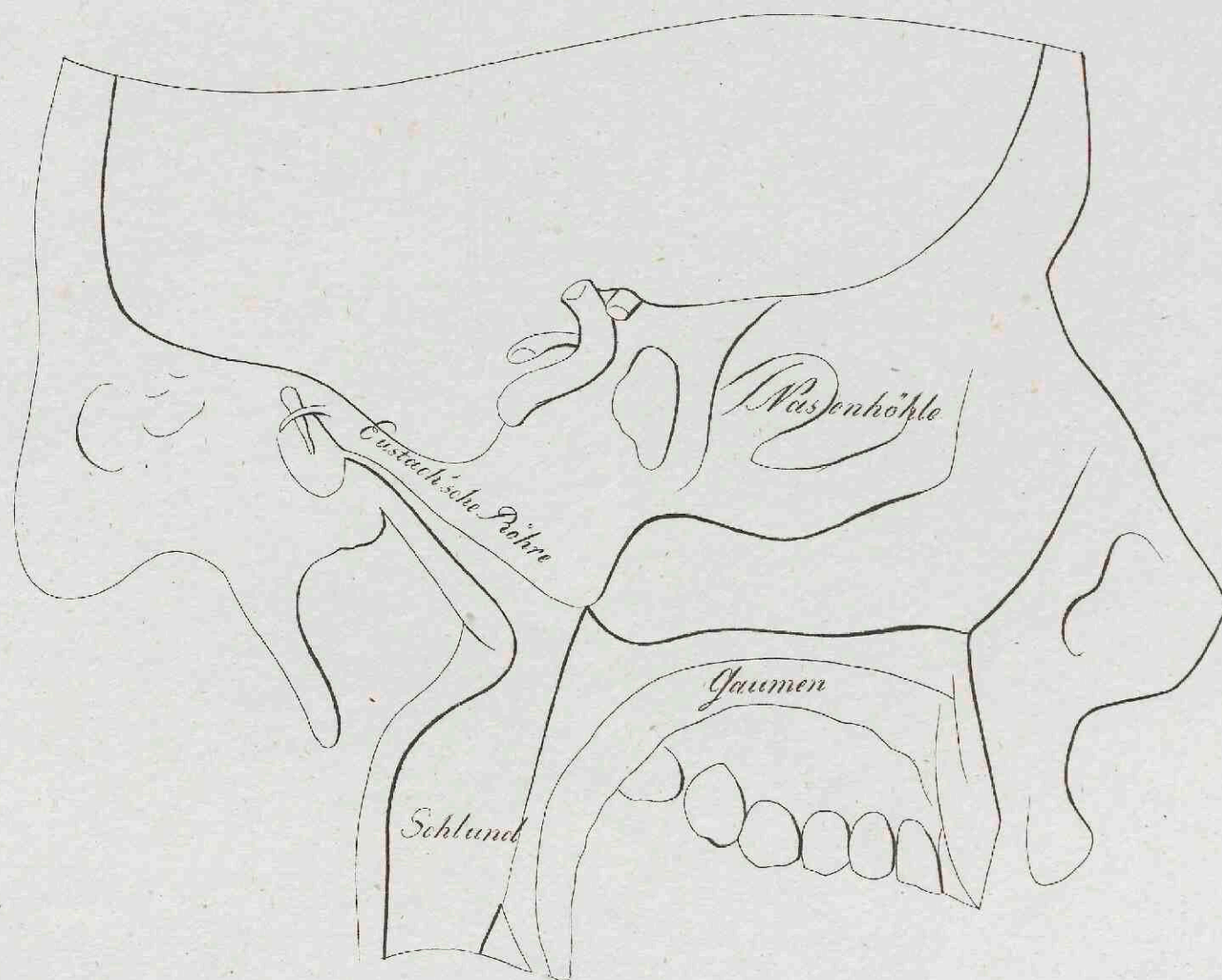
Durchschn. von I zu II.



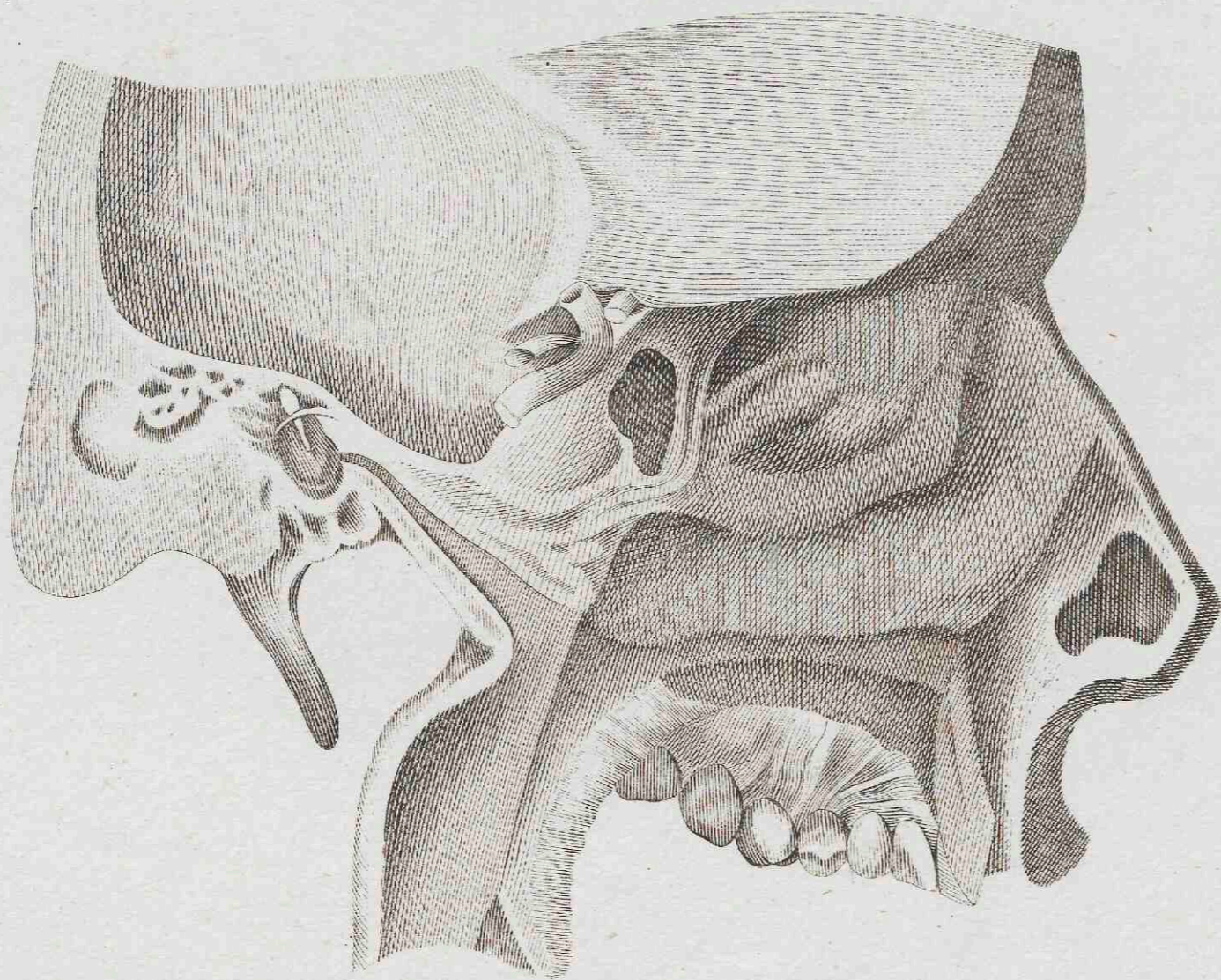

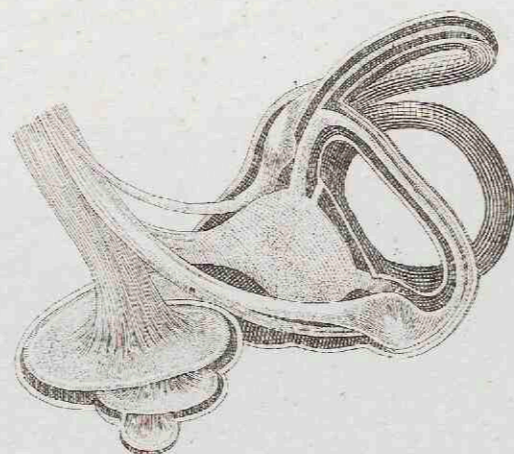


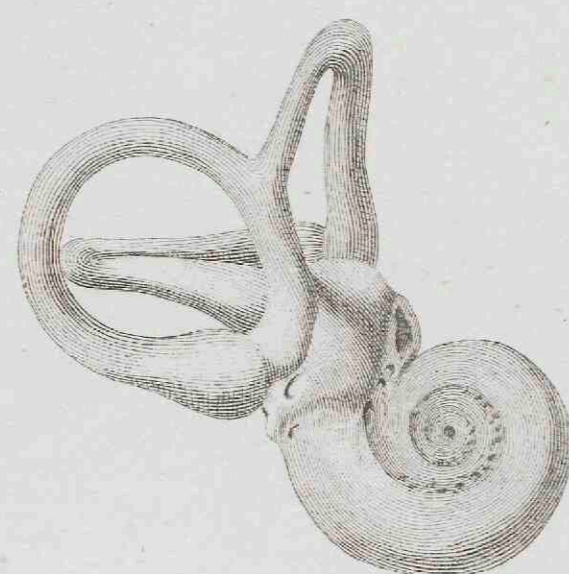
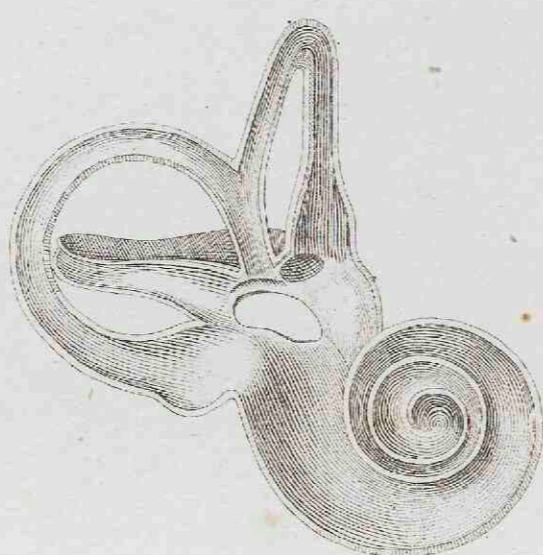
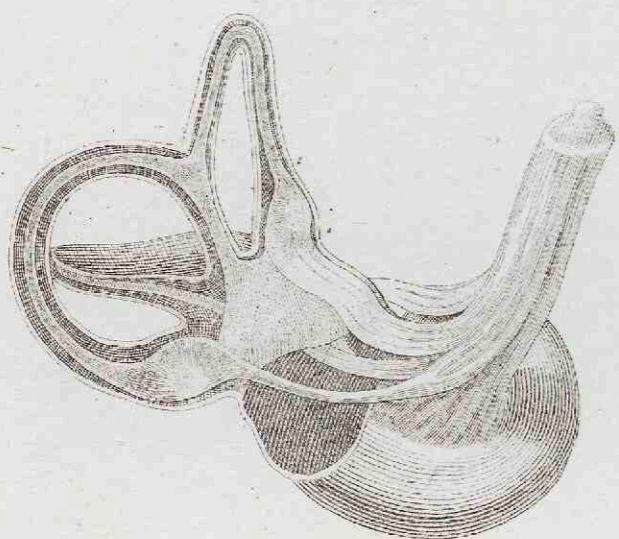

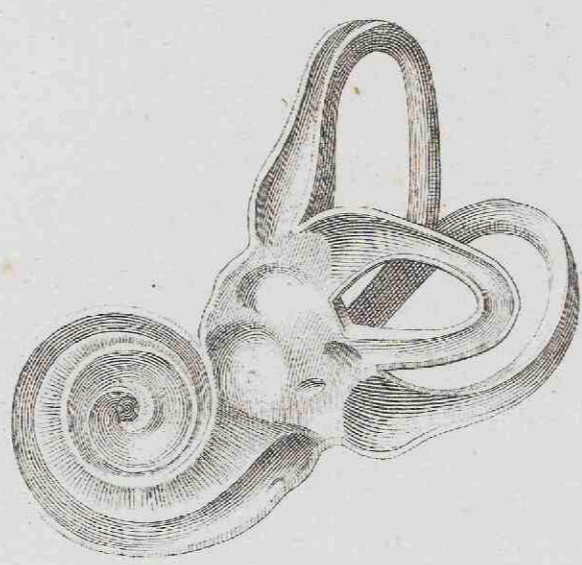
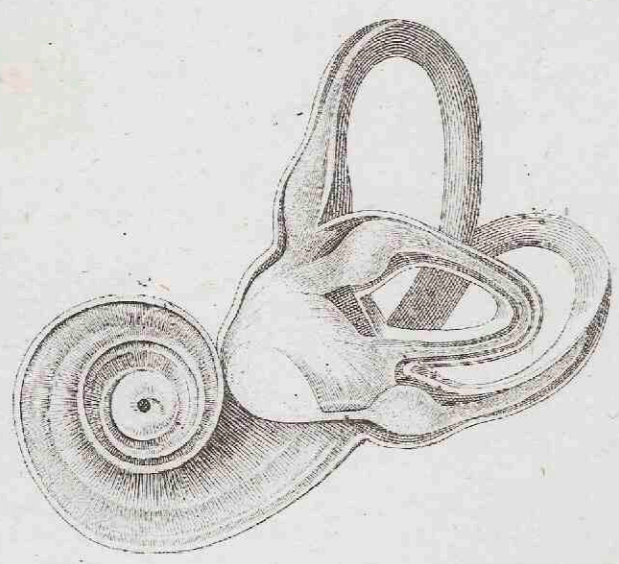
Seitenansicht.



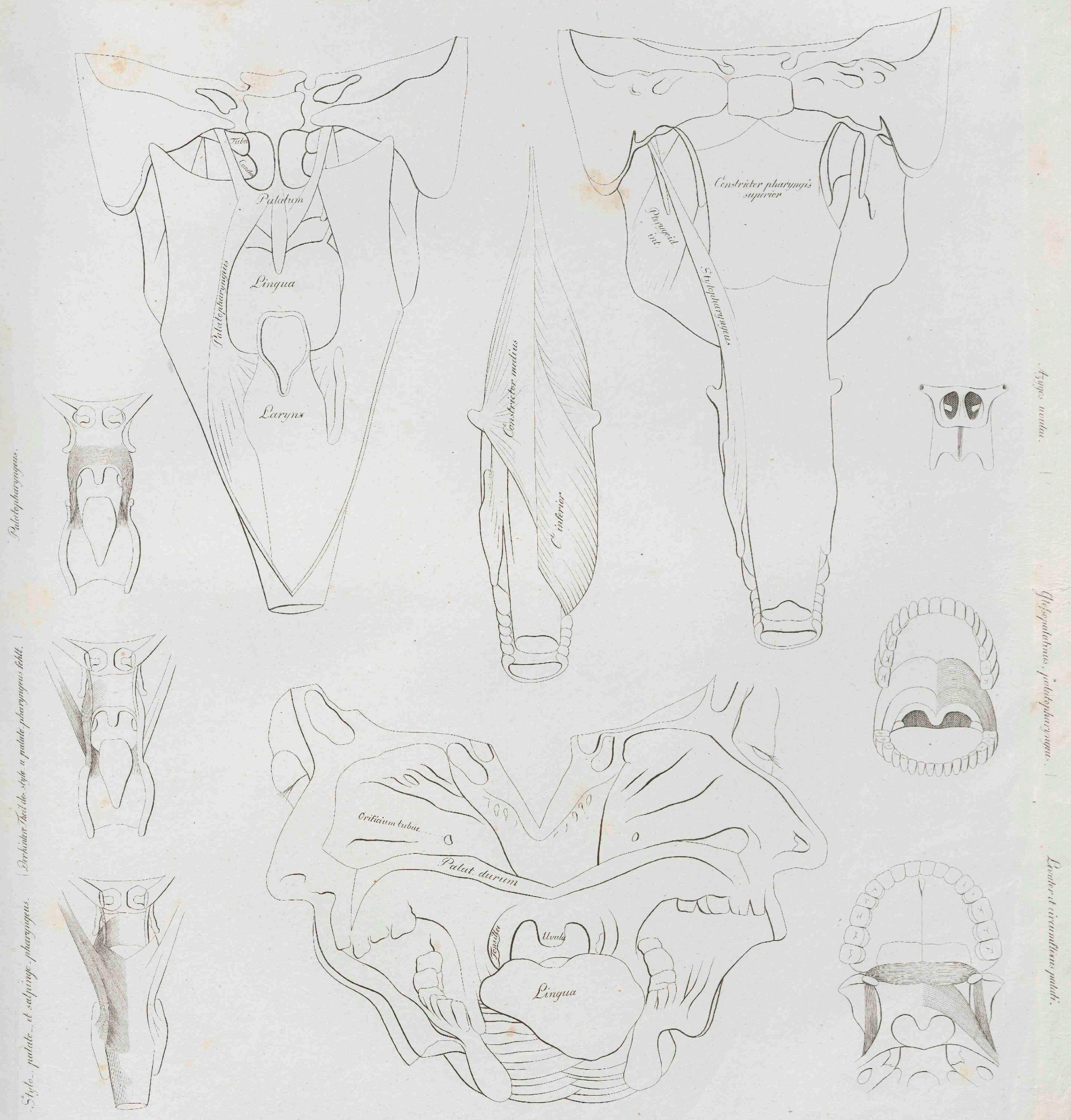
Durchschnitt v. III, IV.



Nasenhöhle
Gaumen
Schlund



Caumensegel und Schlundkopf,



Palatopharyngeus.

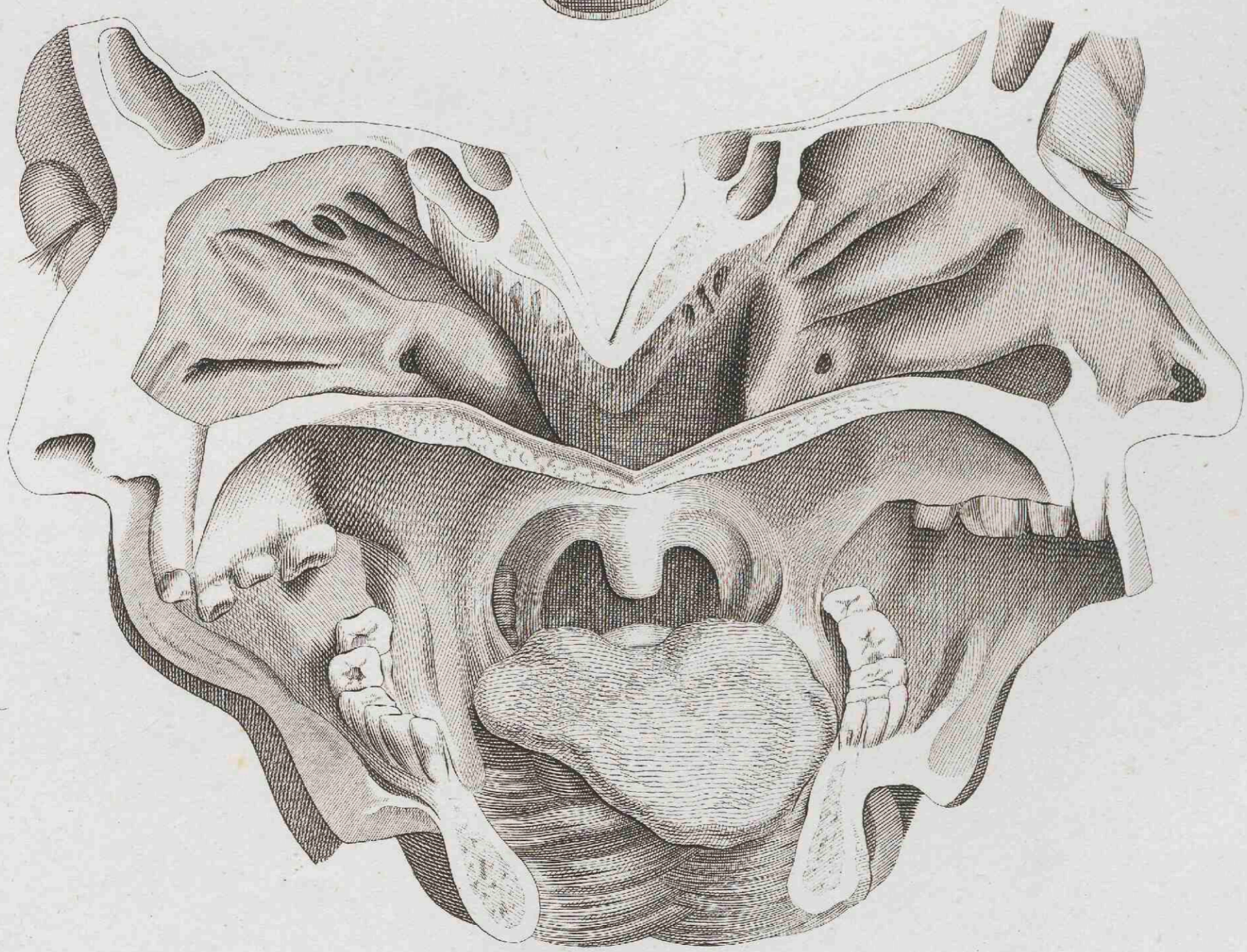
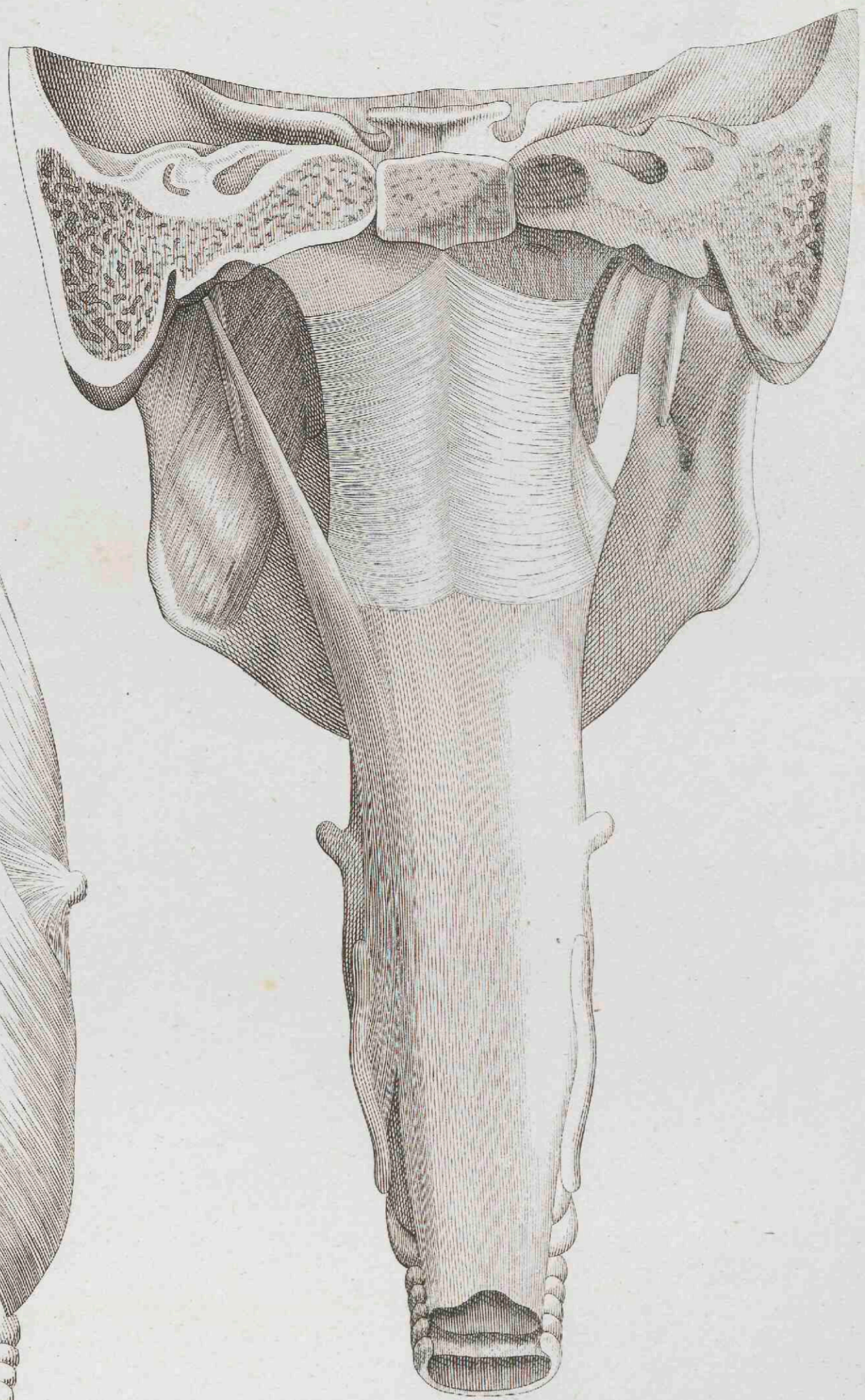
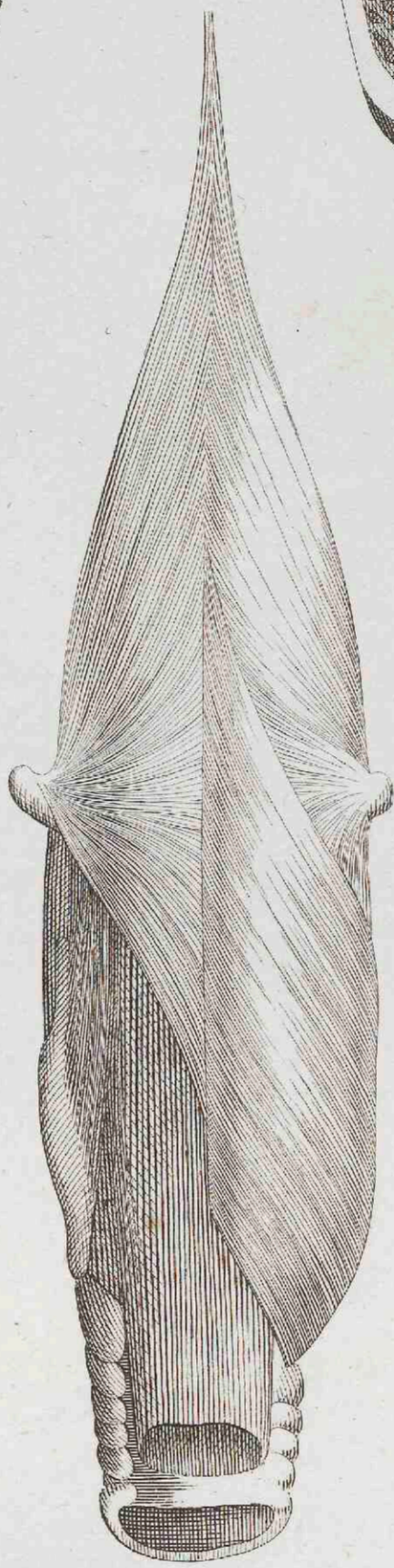
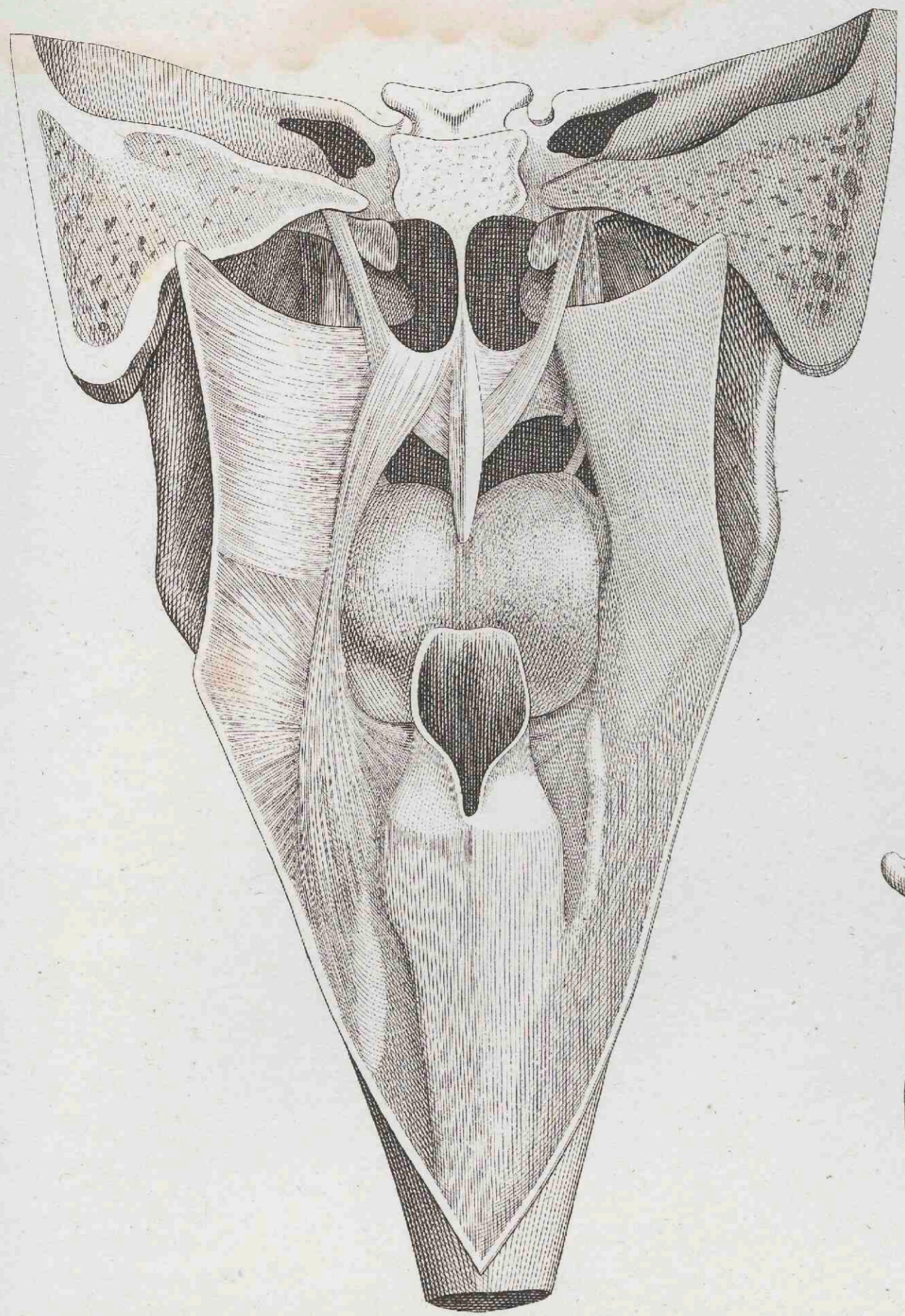
Pharynx. Tub. tub. stylo u. palato pharyngeus. bell.

Stylo., palato., et salpinge pharyngeus.

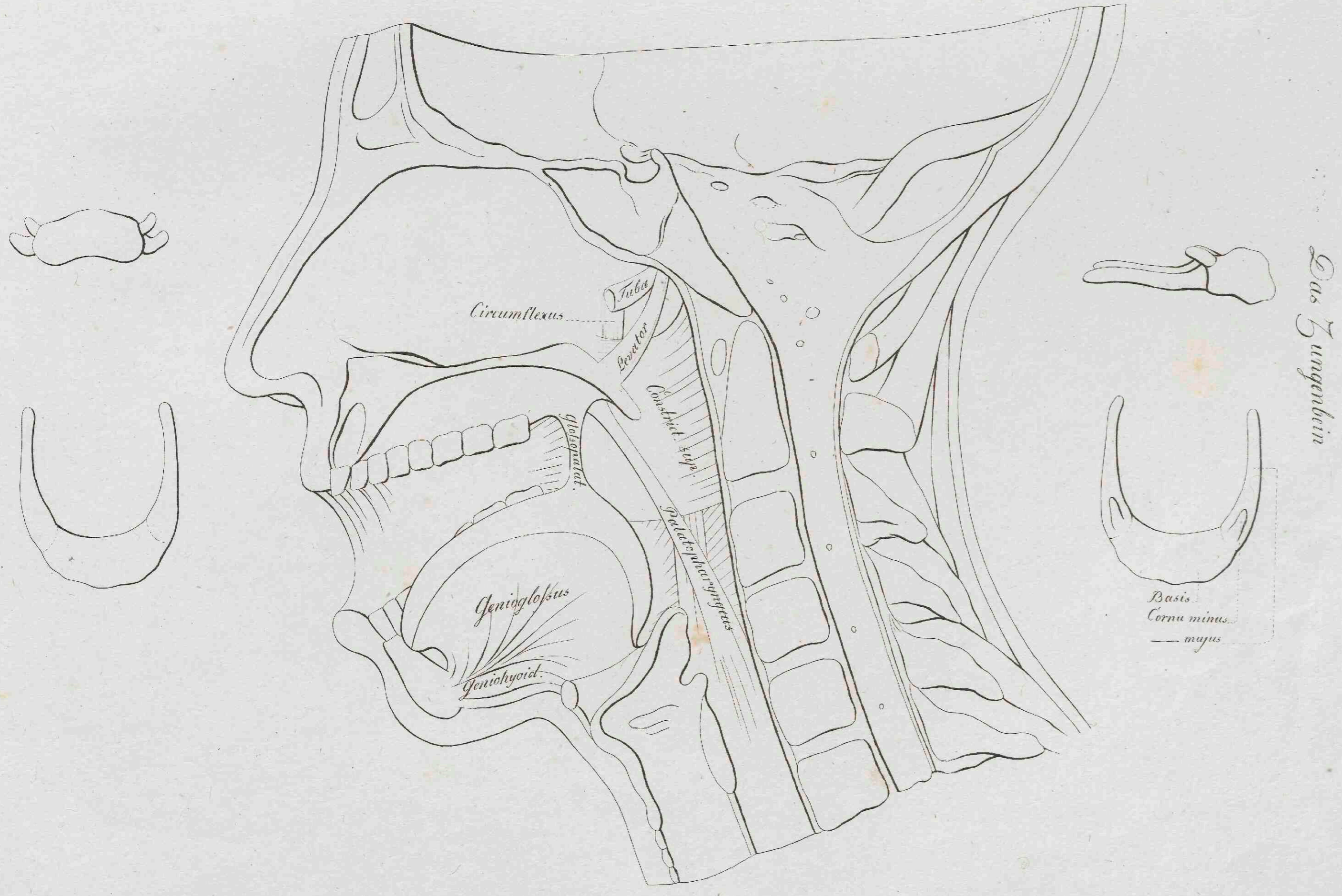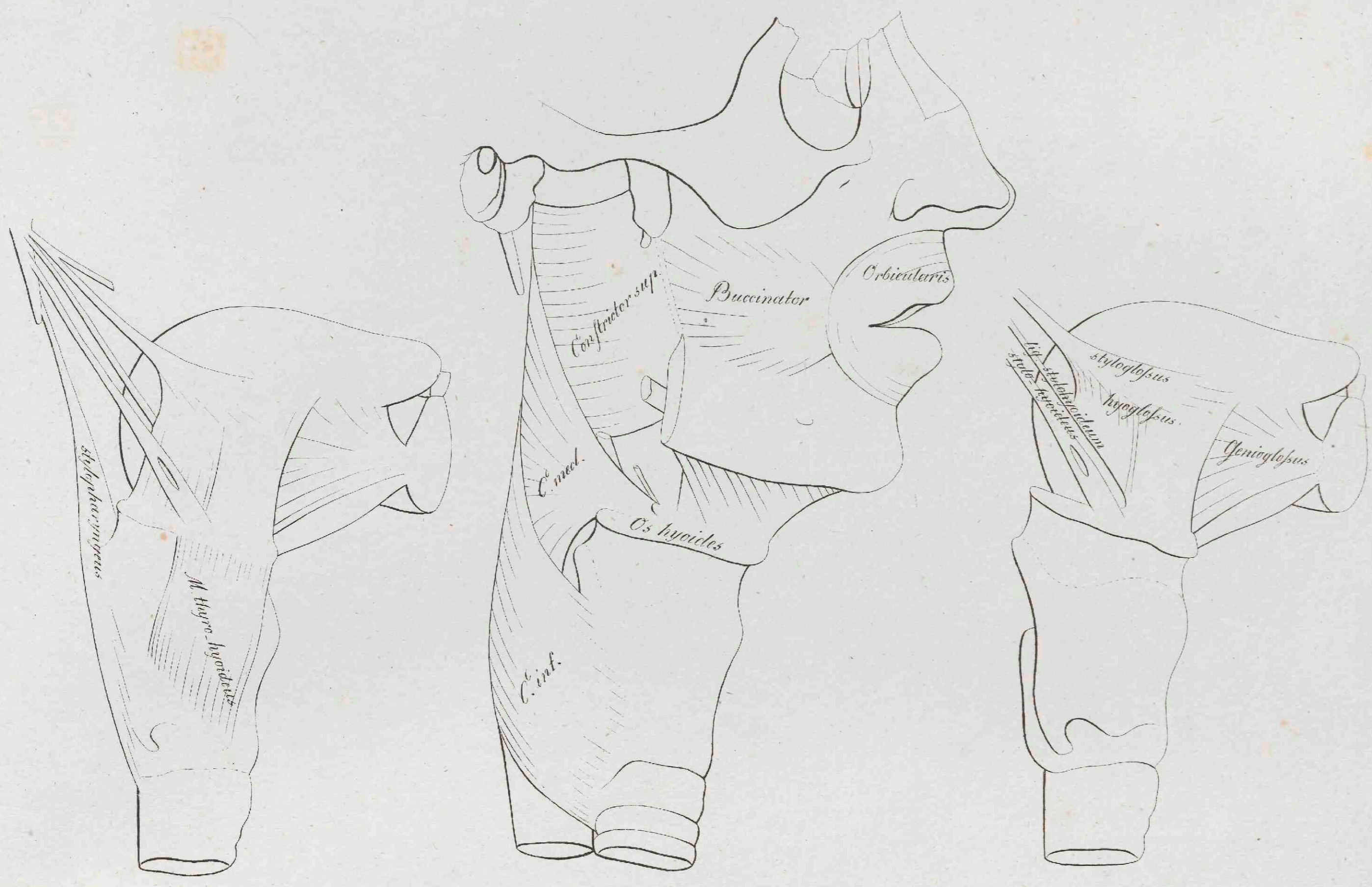
Pharynx.

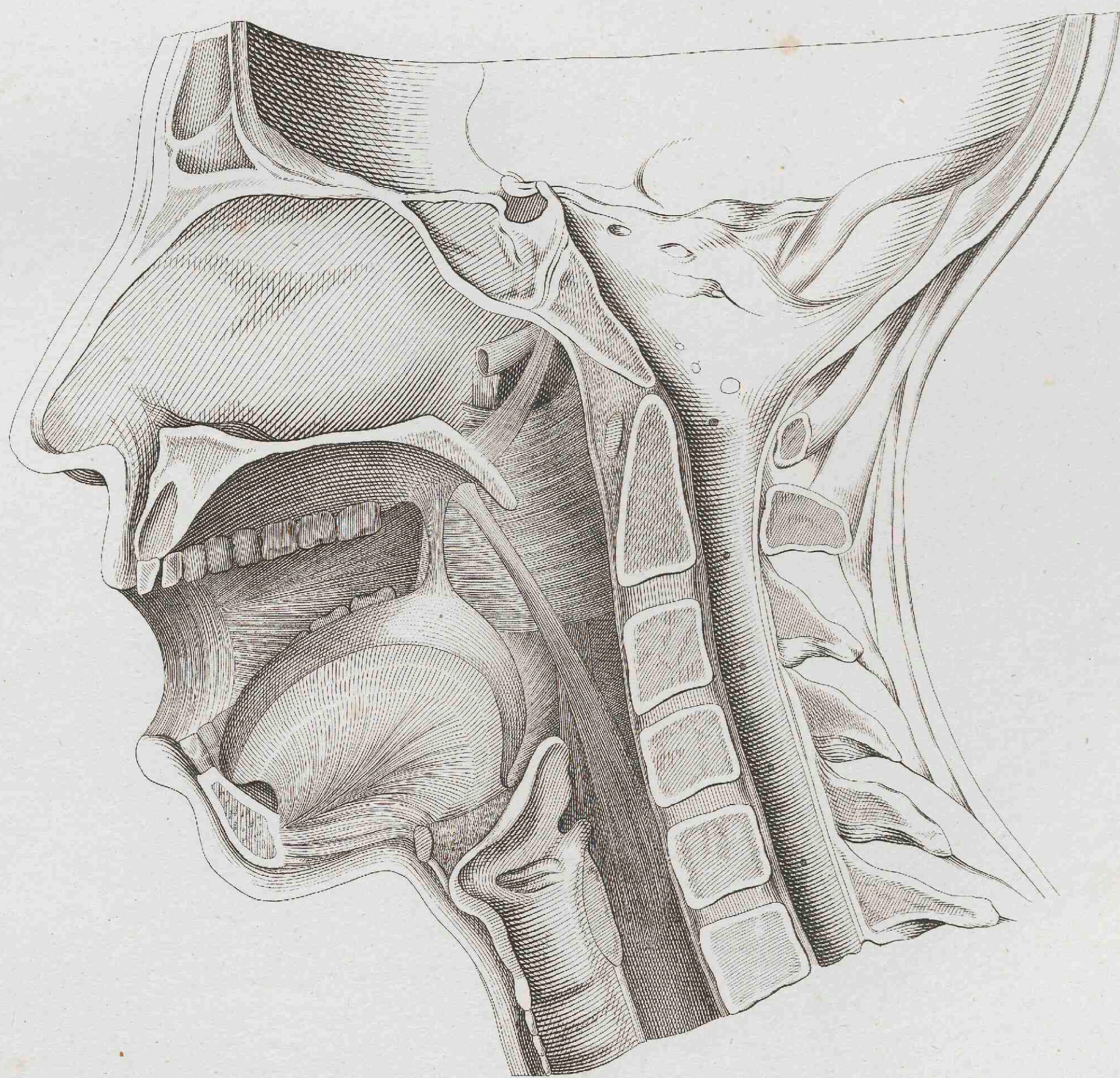
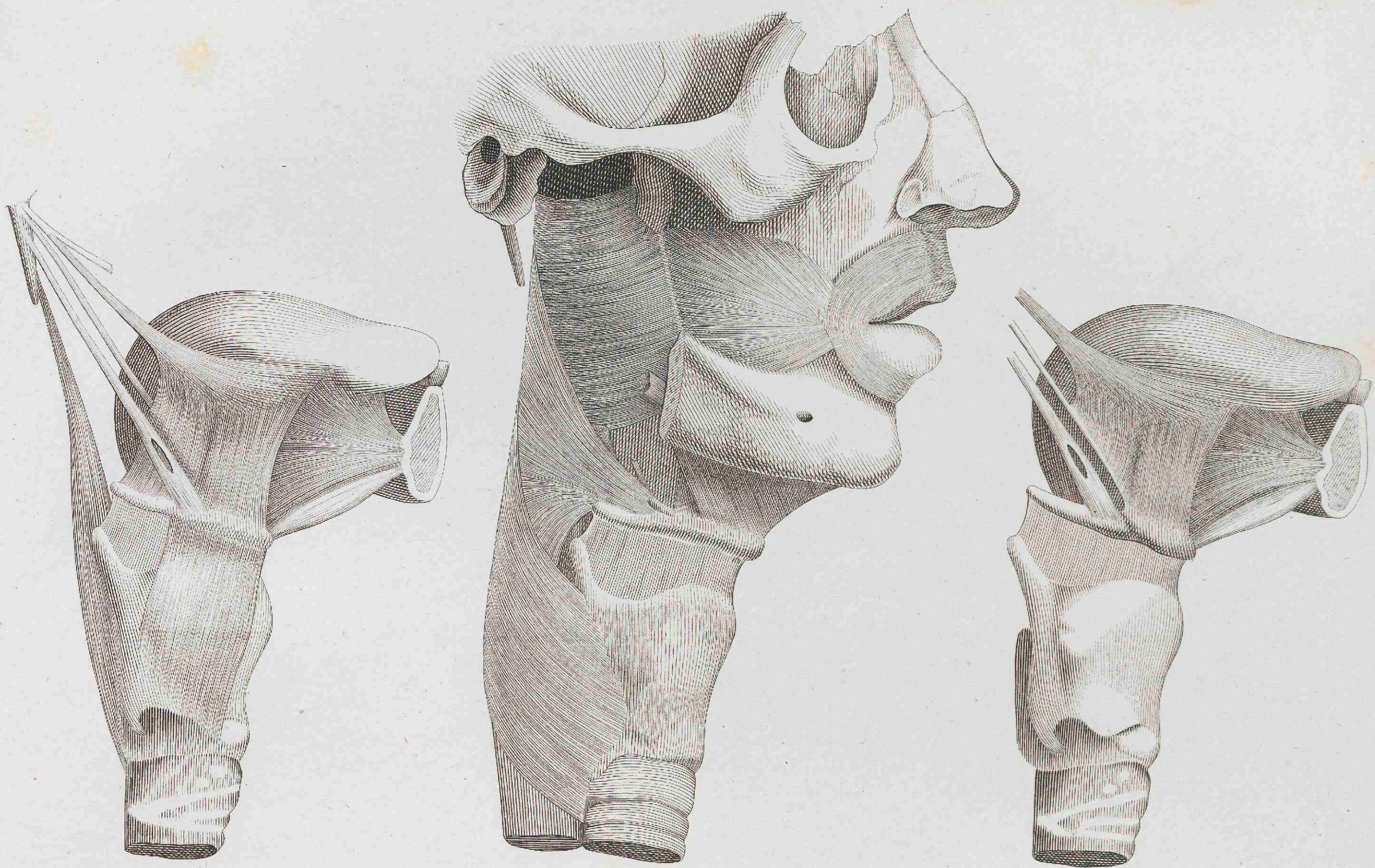
Pharynx.

Pharynx et uvulae palati.



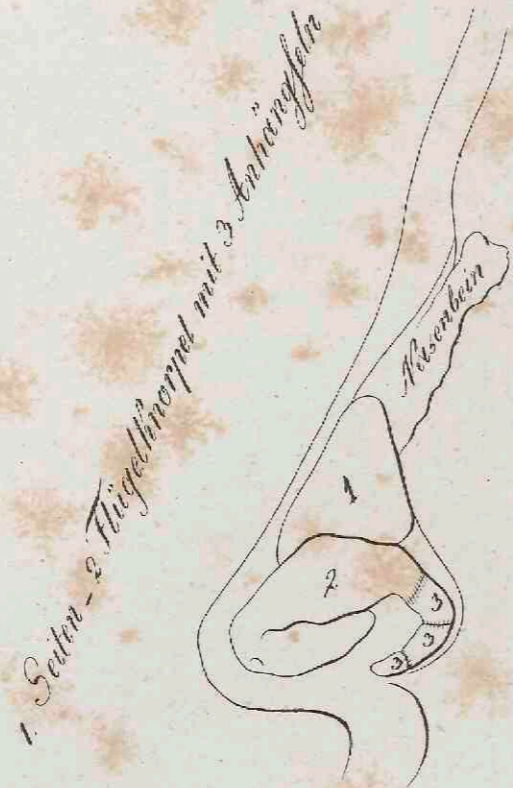

Mund, Zunge, Schlund.




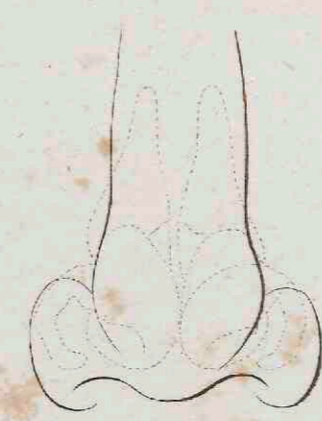



Die Nase,

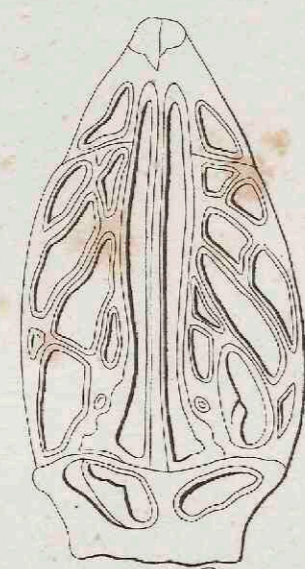
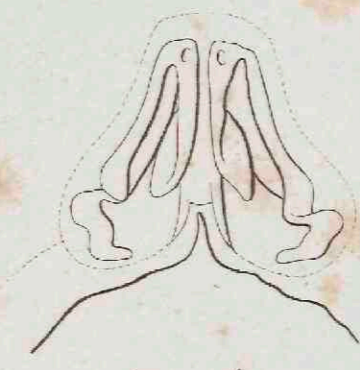
n. Soemmerring.



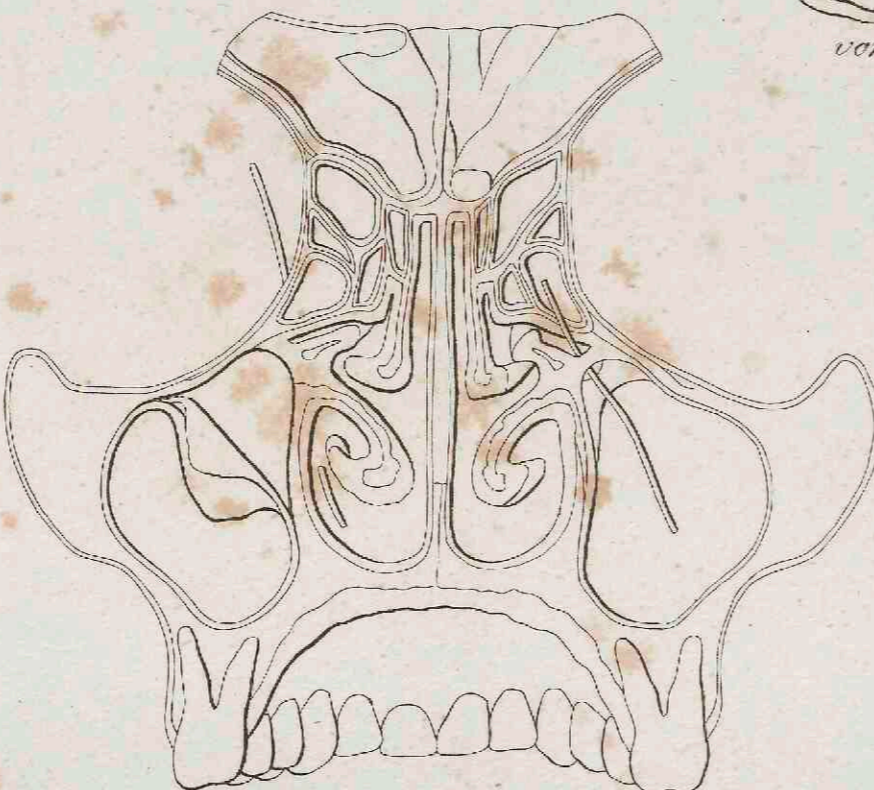Nasenschleimhautknorpel



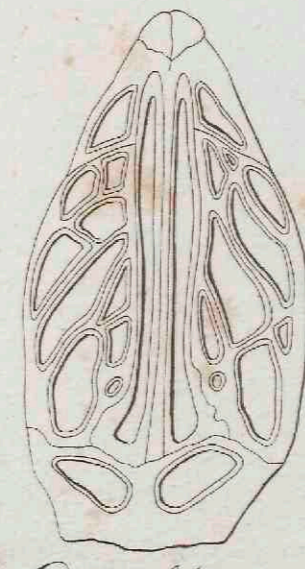
Die Zwischenknorpel



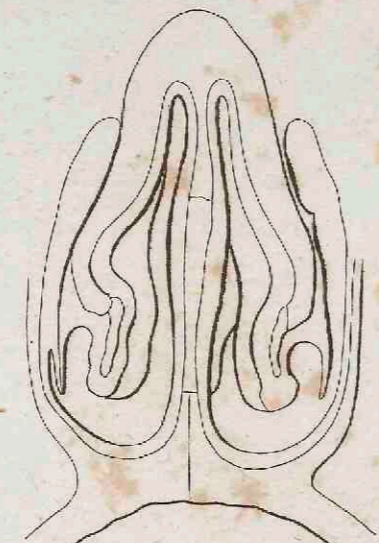
Horizontaler Durchschnitt 4 oberes Stück



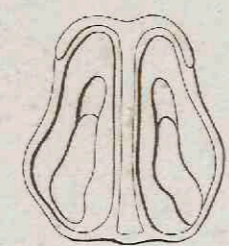
Hintere Durchschnittsfläche der Nasenhöhlen Richtung des Schnittes von 3 zu 3.



Durchschnitt 4 unteres Stück

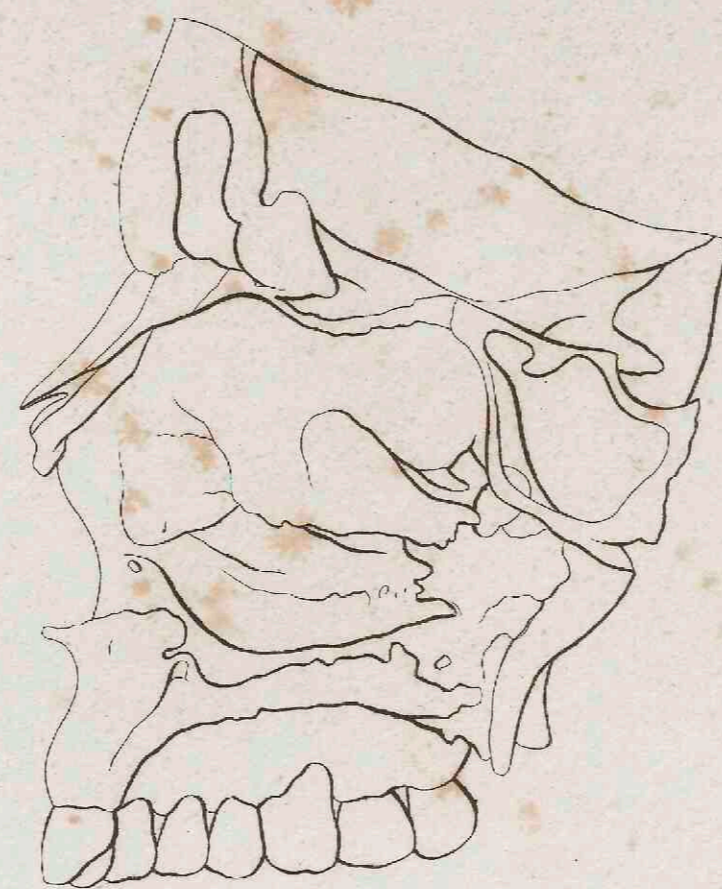


Durchschnitt 2

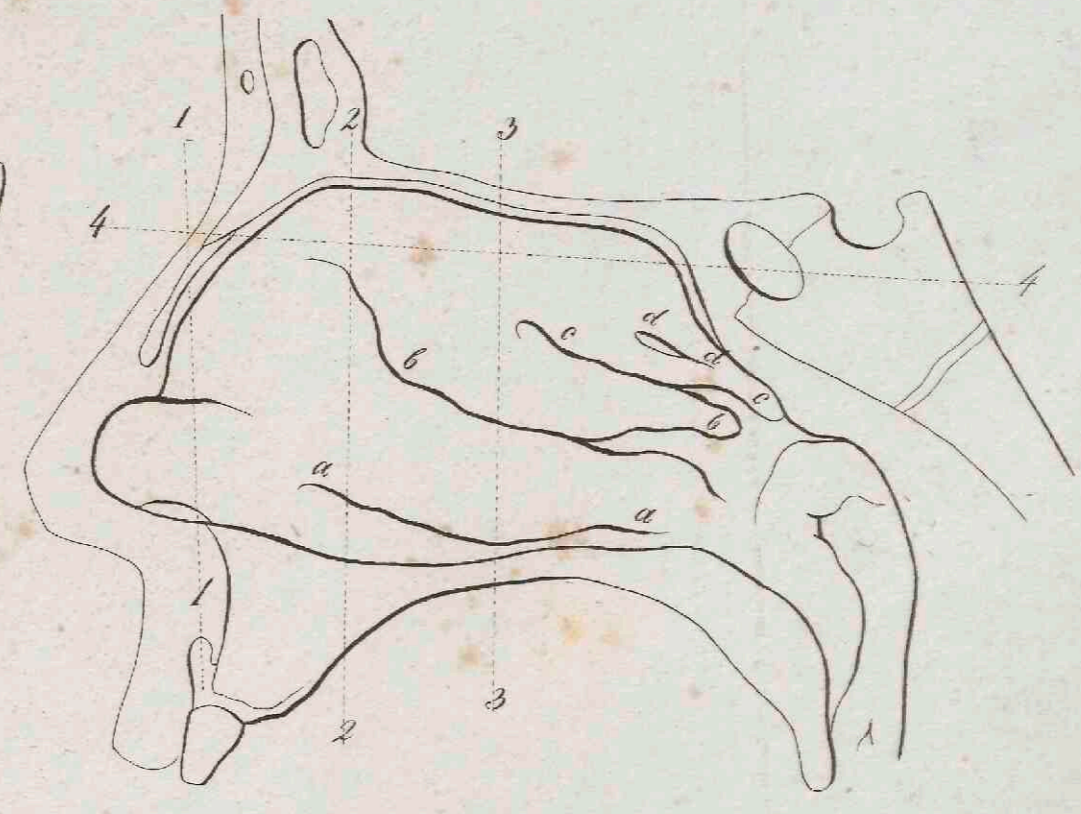


Durchschnitt 1

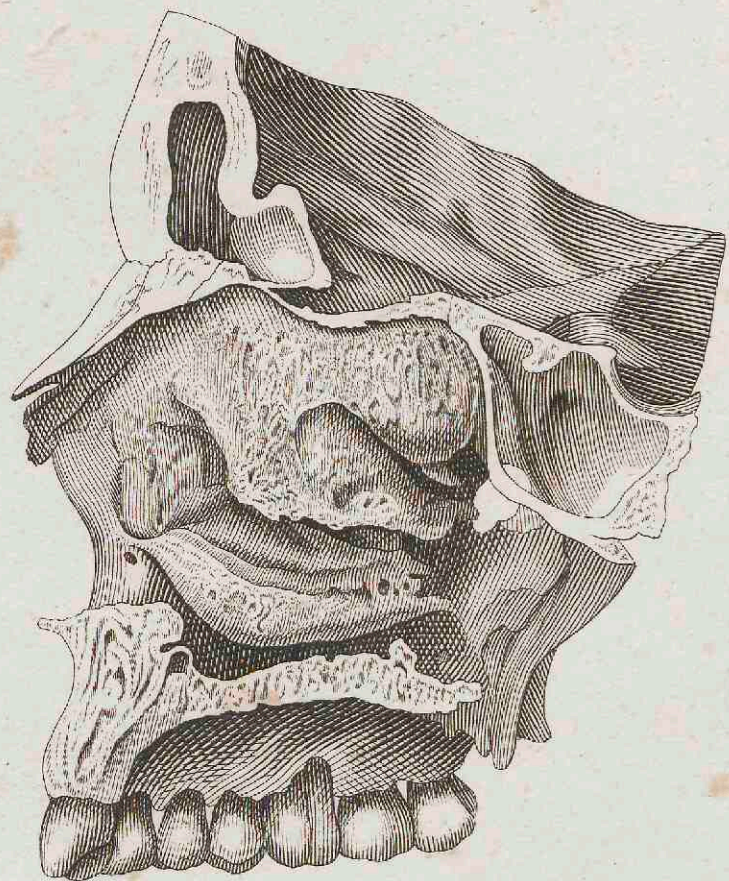
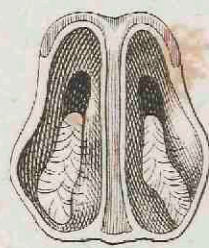
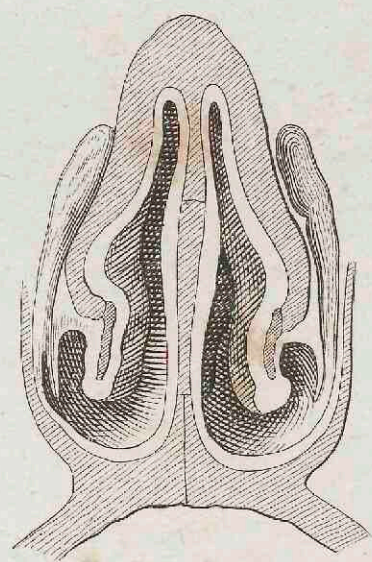
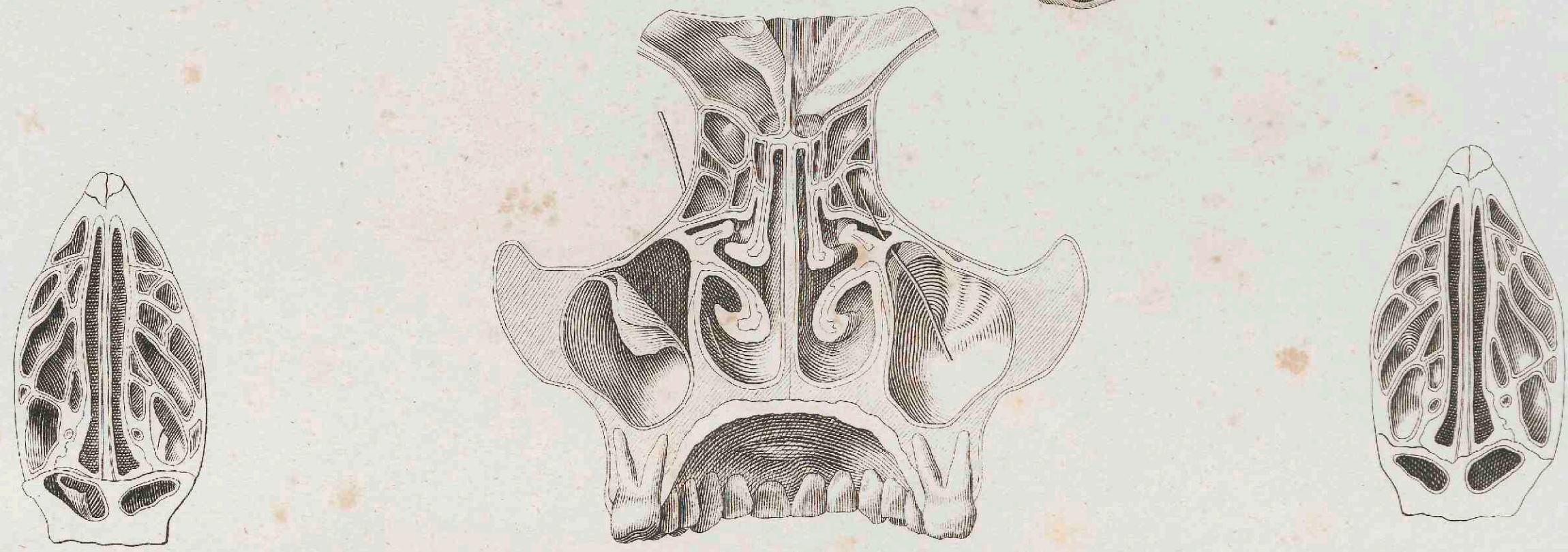
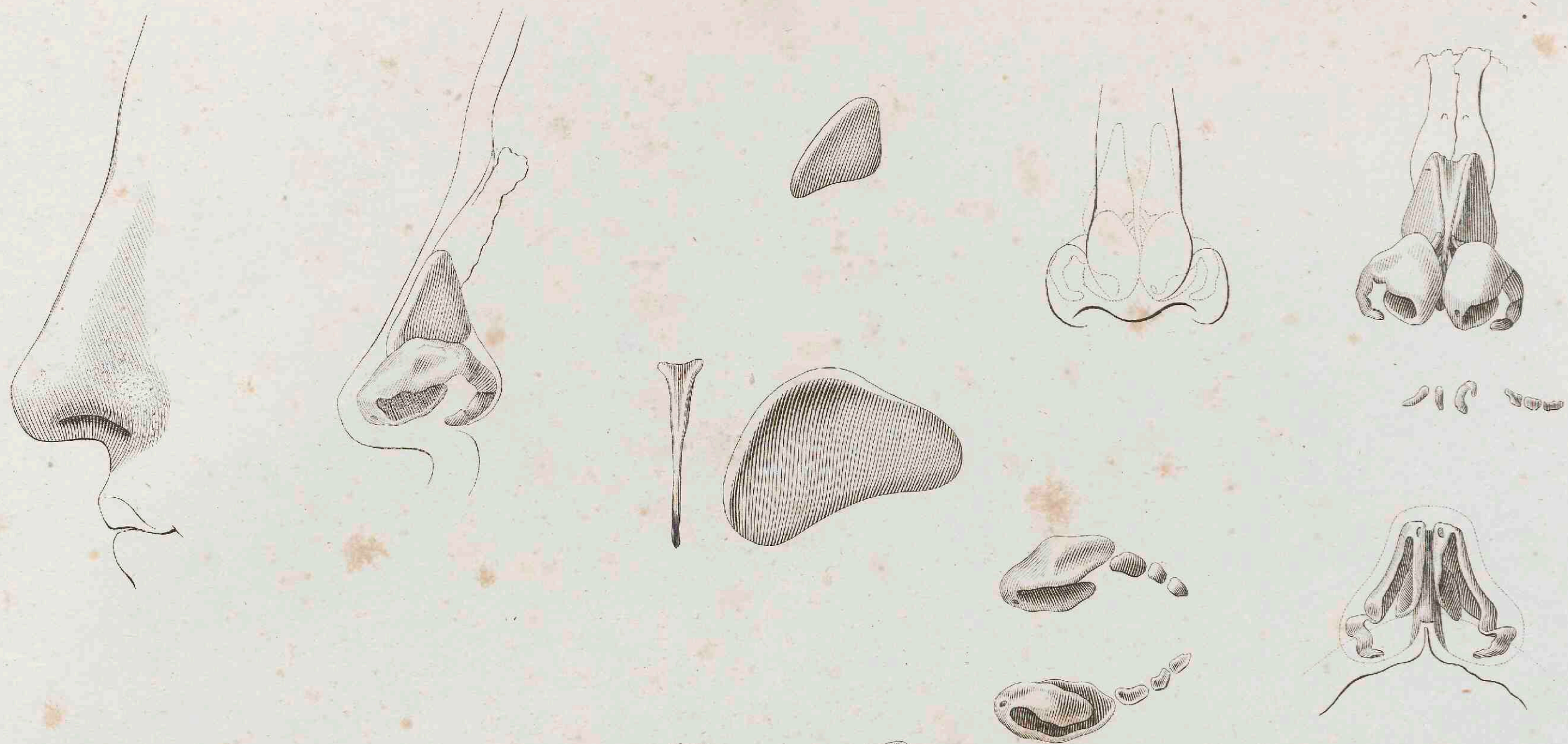
Den Riechnerven findet man in der Stirn-, die Arterien der Nasenhöhlen in der Gelenklehre.



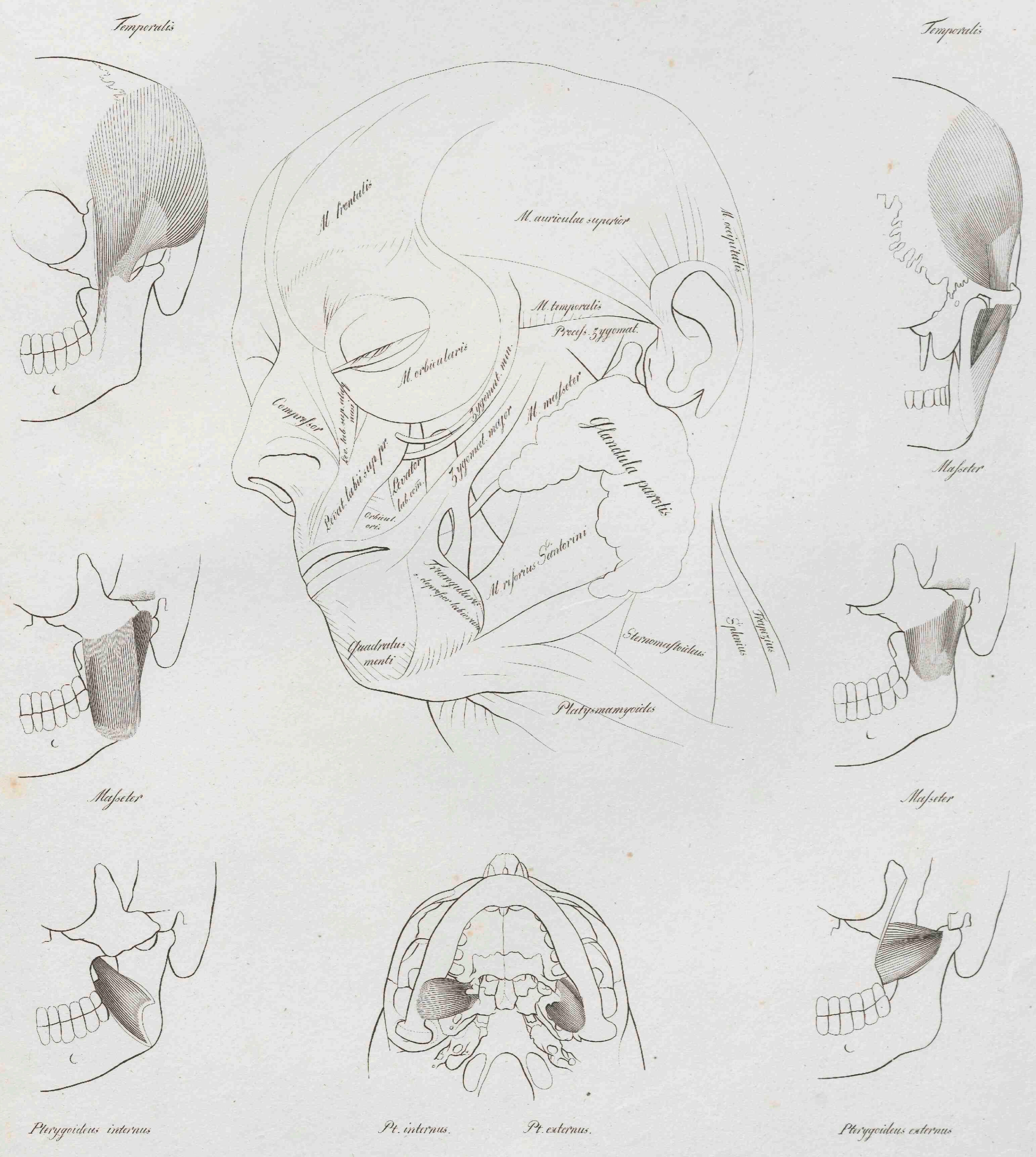
Knochengerüste für die äußere Wand d. rechtl. Nasens.



Ansicht der inneren Wand der rechten Nasenhöhle a untere, b mittlere, c obere, d Andeutung der obersten Nasenhöhle.



Ohrspeicheldrüse, nach Santorini.



Temporalis

Temporalis

Masseter

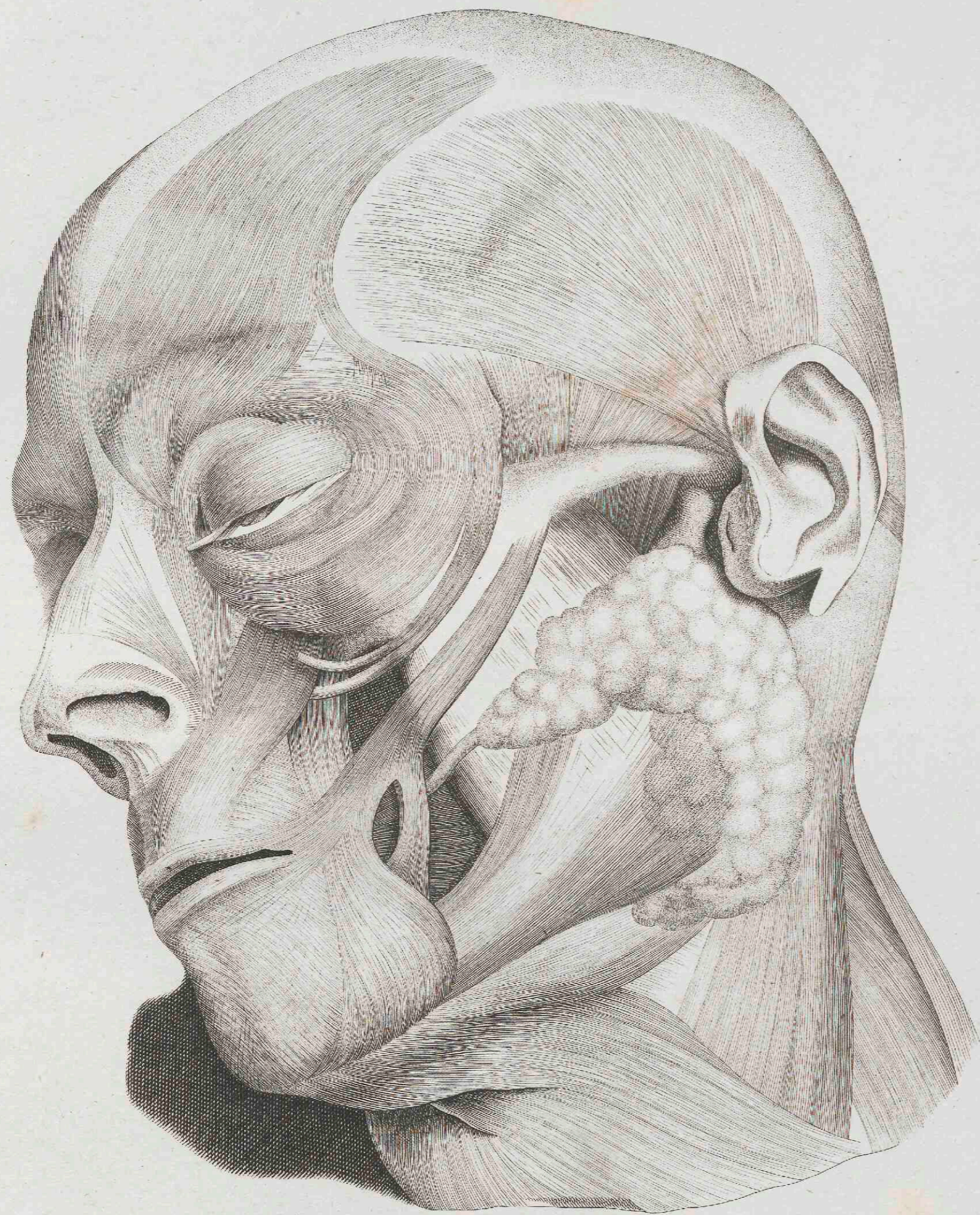
Masseter

Pterygoidae internus

Pt. internus.

Pt. externus.

Pterygoidae externus

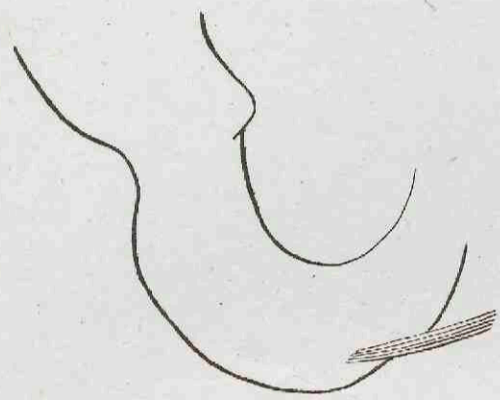


Geschlechtstheile,

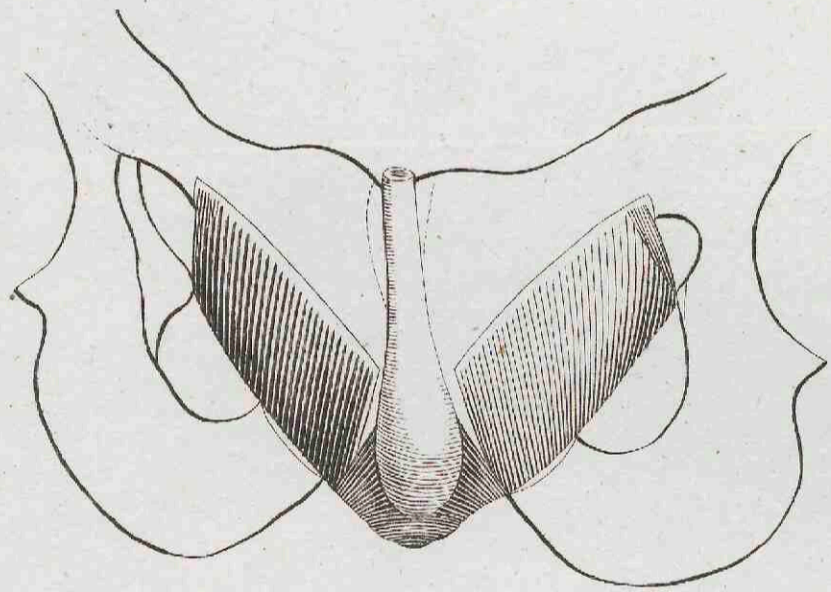
nach Santorini.



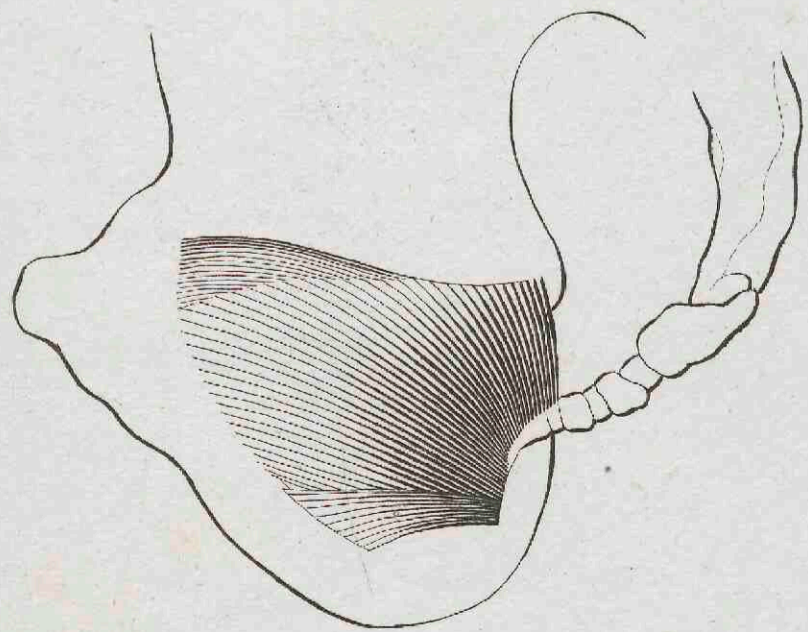
Erector penis



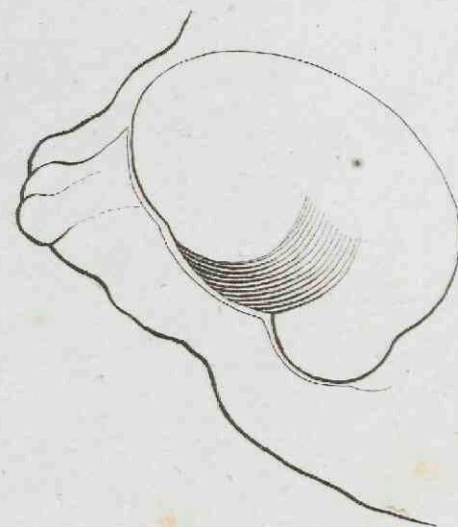
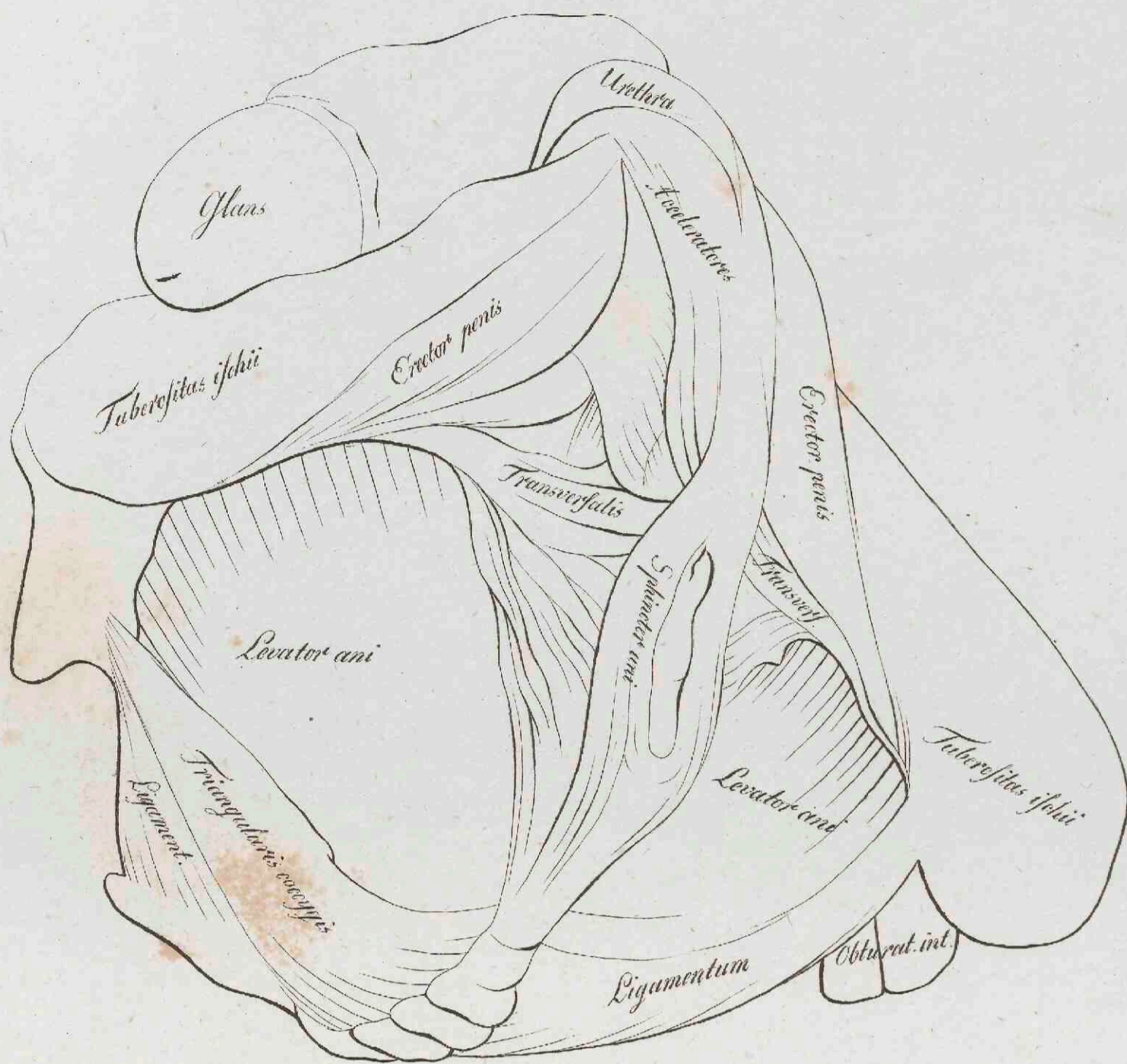
Transversus perinaei




Levator ani cum sphinctere interno.



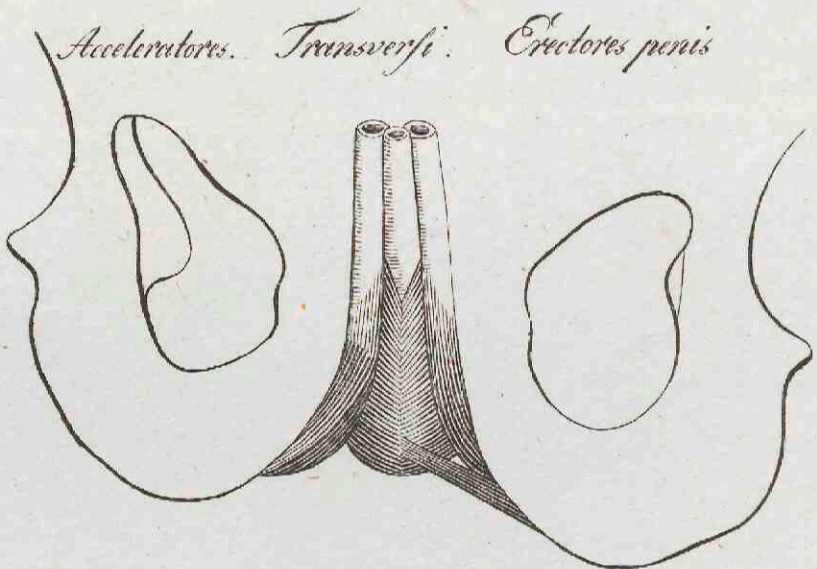
Levator ani.



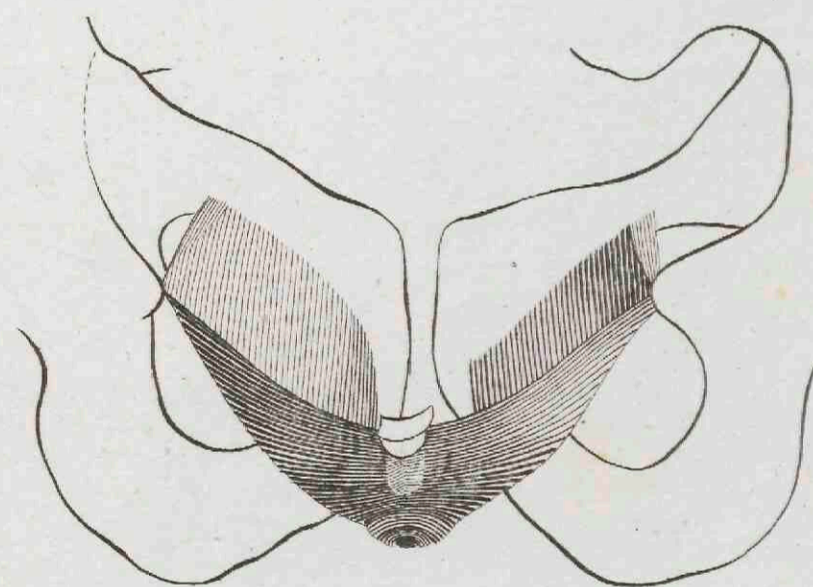
M. vesicae



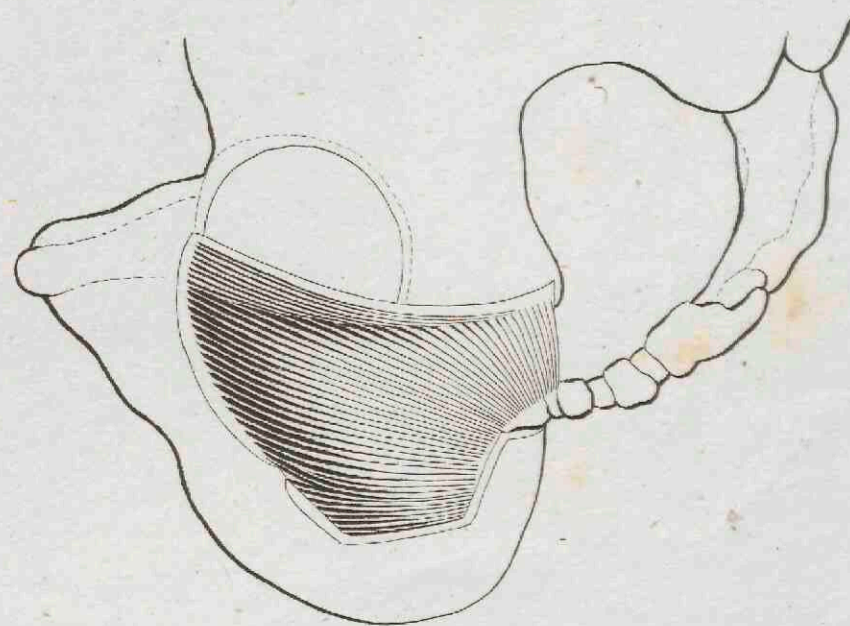
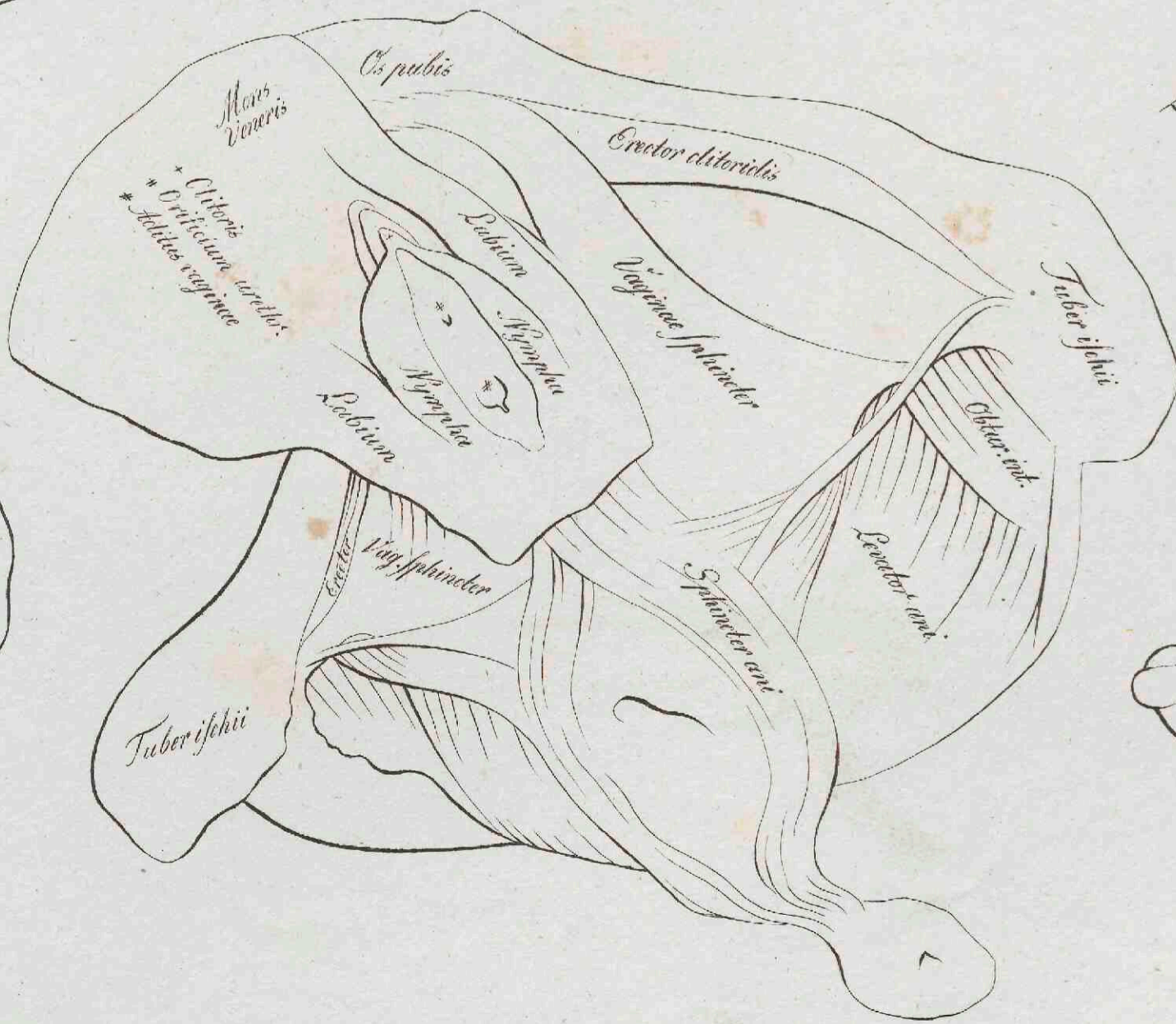
Transversus perinaei alter



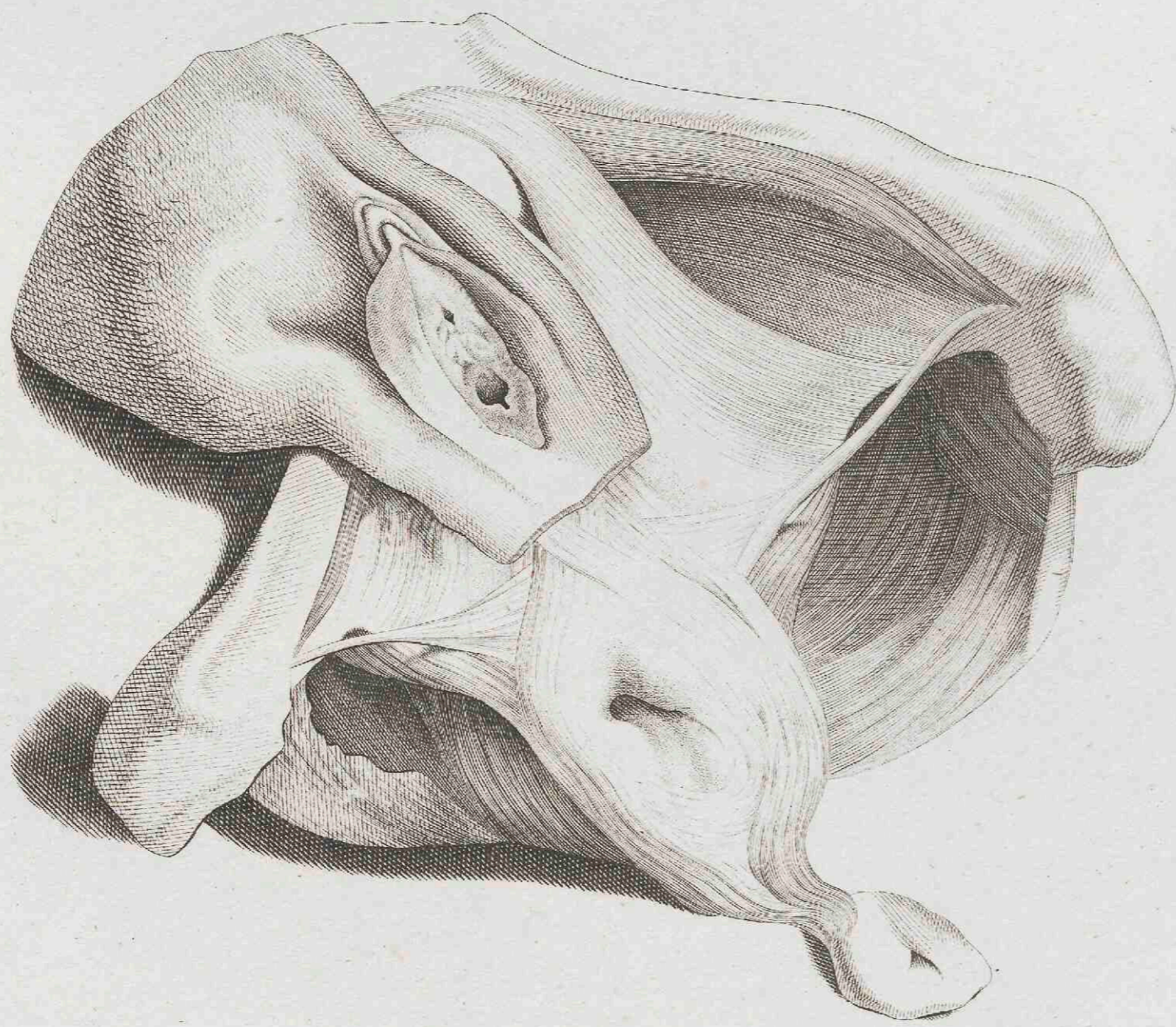
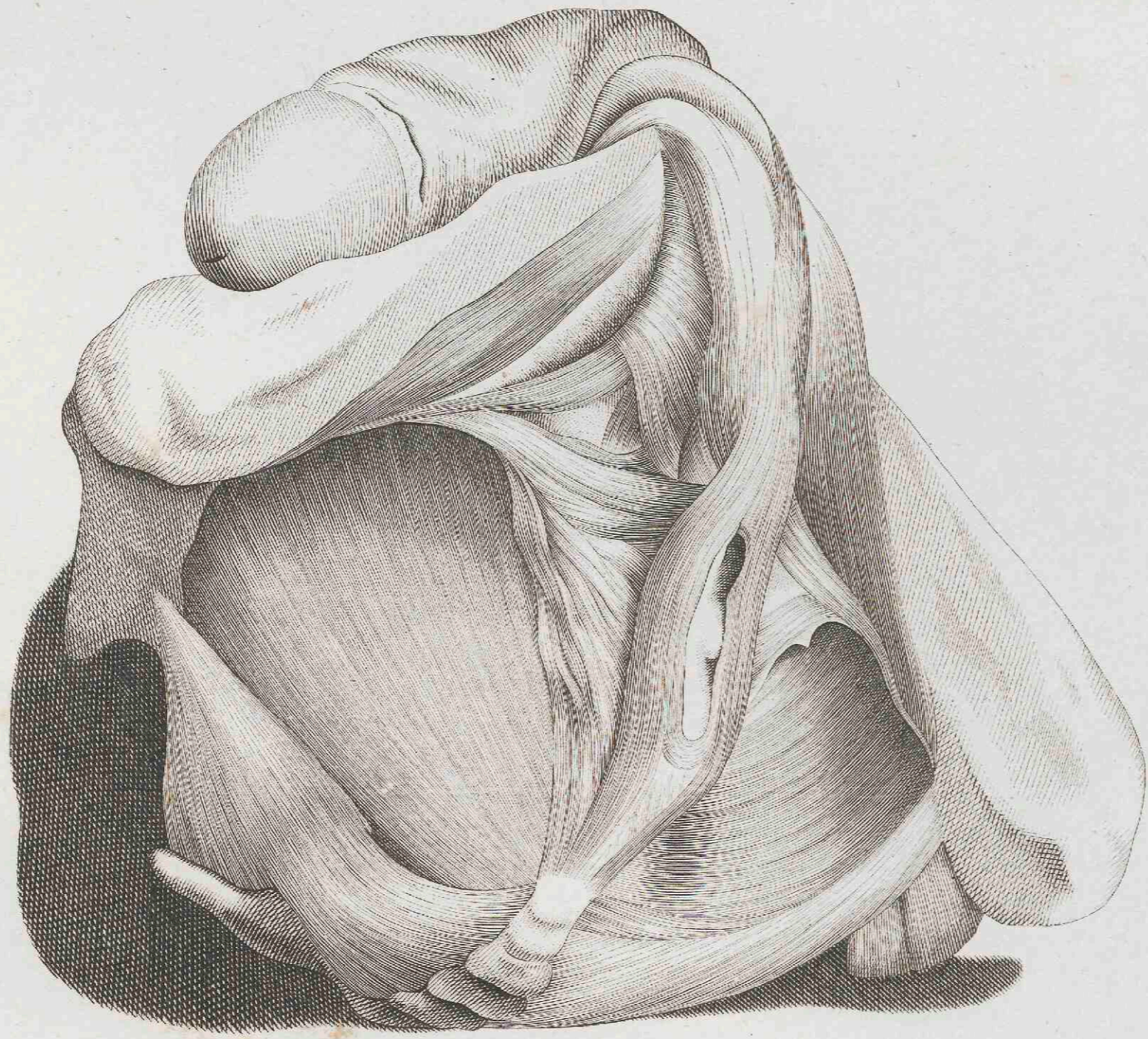
Acceleratores Transversi Erectores penis



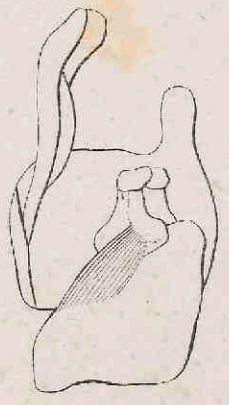
Levator ani cum sphinctere interno.



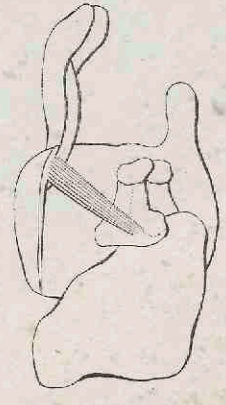
Levator ani.



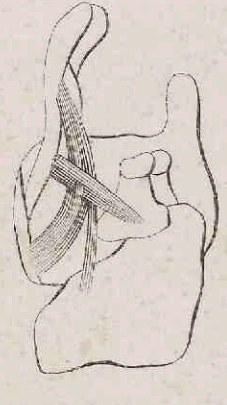
Kehlkopf



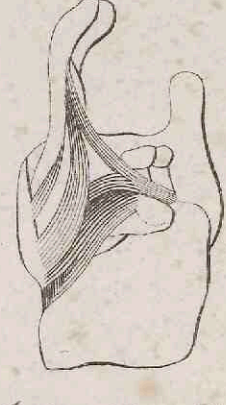
Cricarytenoideus lateralis



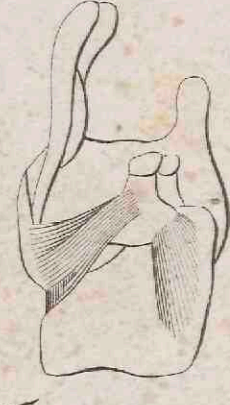
Thyroarytenoideus alter s. minor



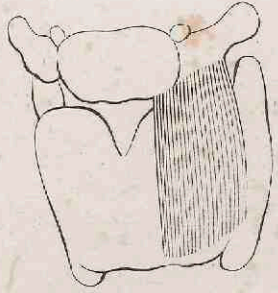
*Thyroepiglotticus major
Thyroarytenoideus alter*



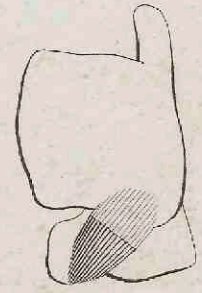
*Arytenoideus obliquus
Thyroarytenoideus
Thyroepiglotticus major et minor*



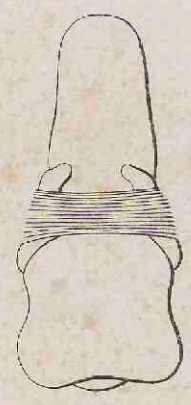
*Thyroarytenoideus
Cricarytenoideus posticus*



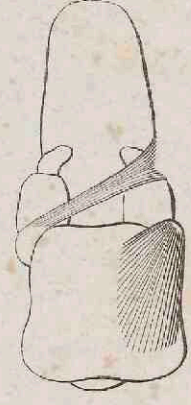
Thyrohyoideus



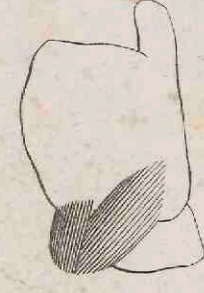
Cricothyroideus



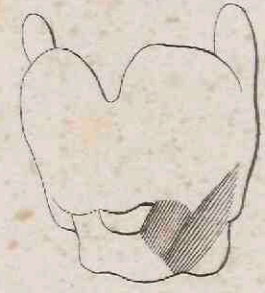
Arytenoideus transversus



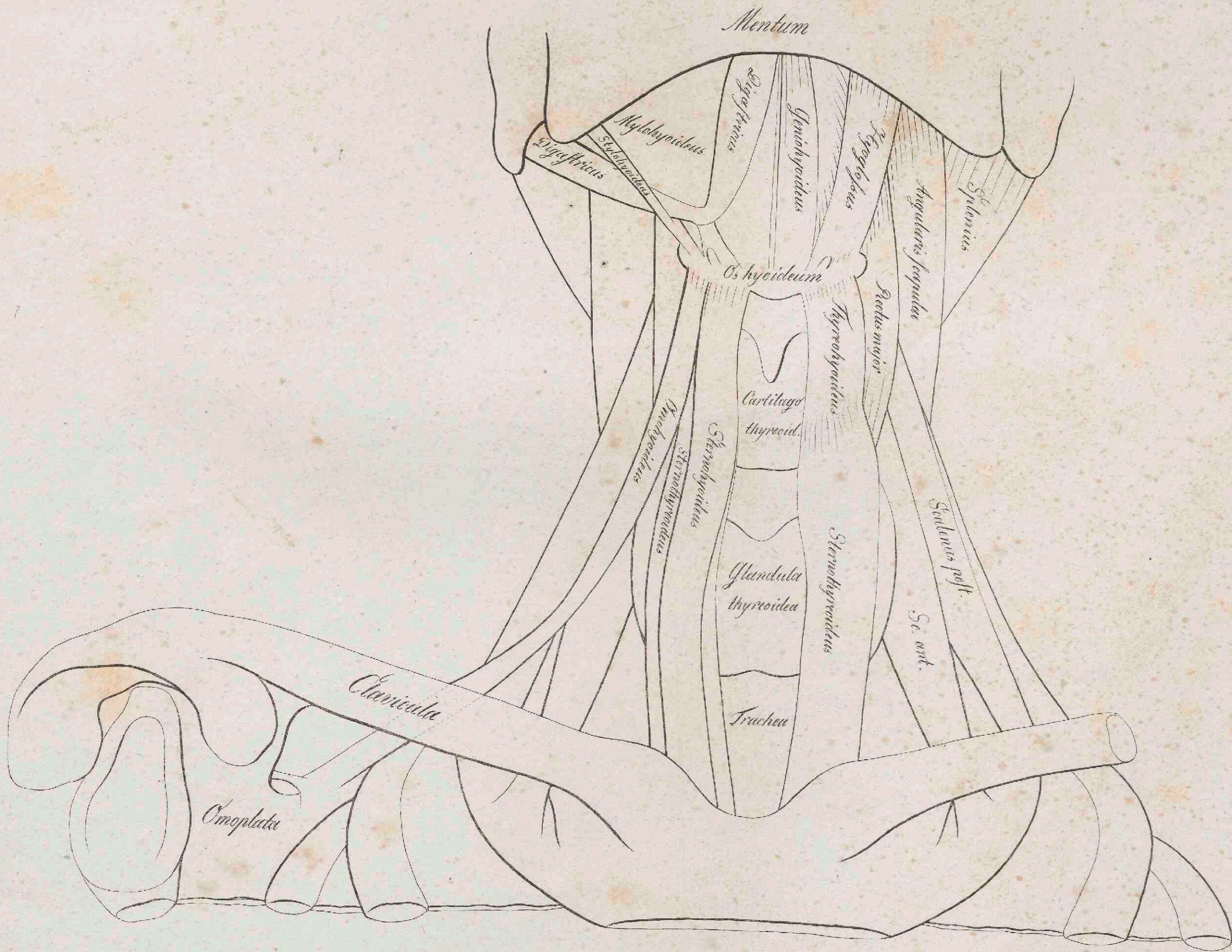
*Arytenoideus obliquus
Cricarytenoideus posticus*

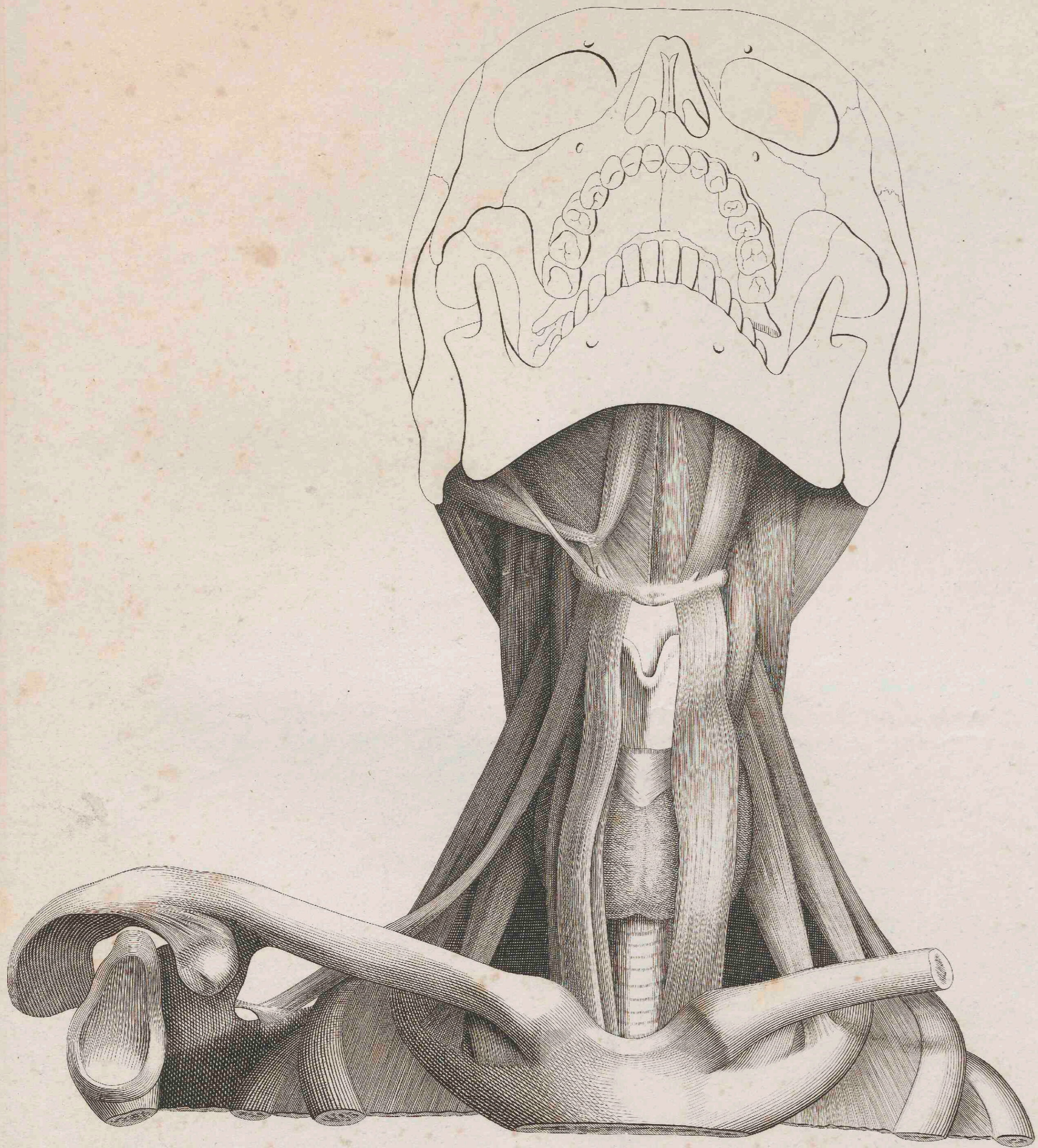


Cricothyroideus



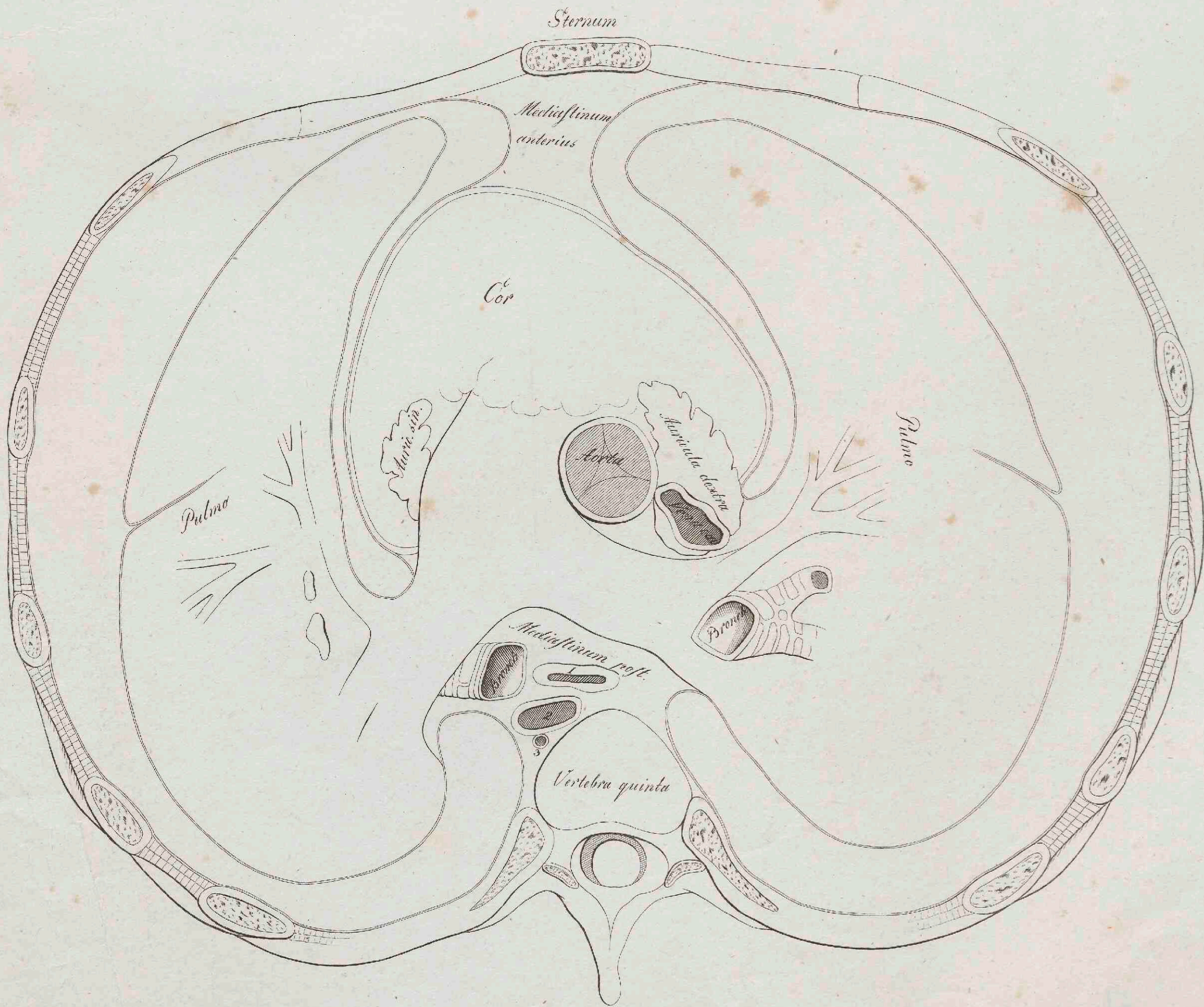
Cricothyroideus



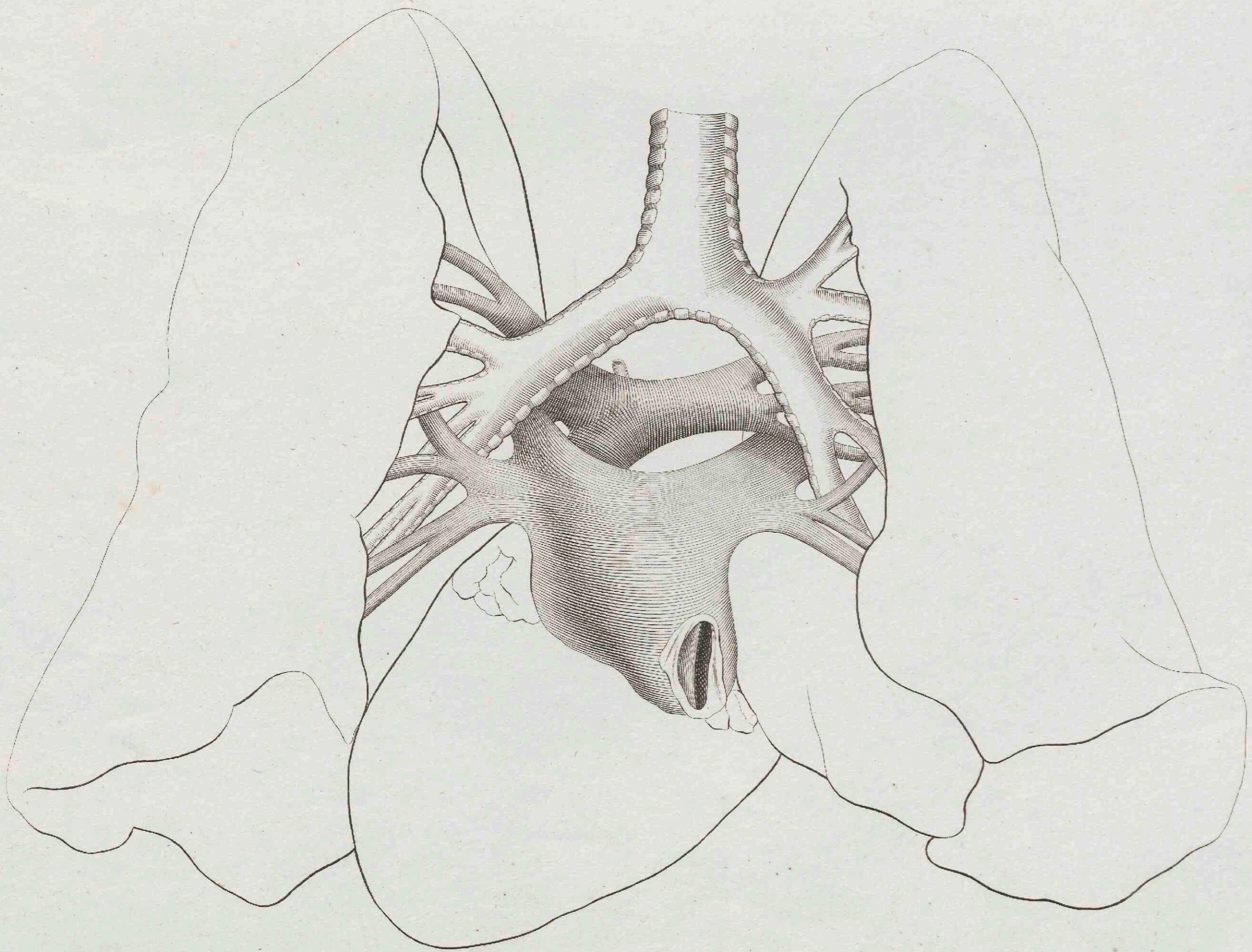
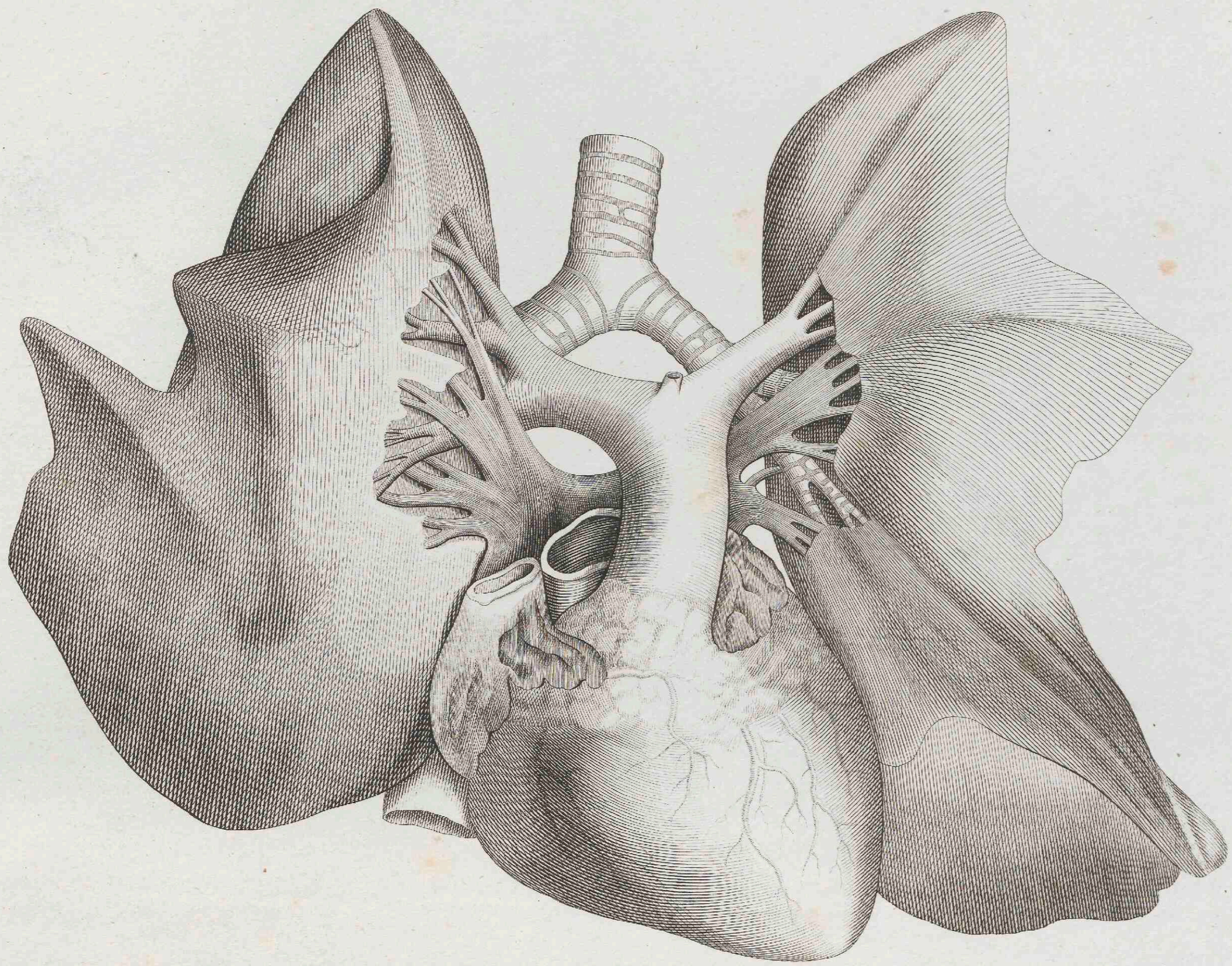


Lunge

nach Cloquet

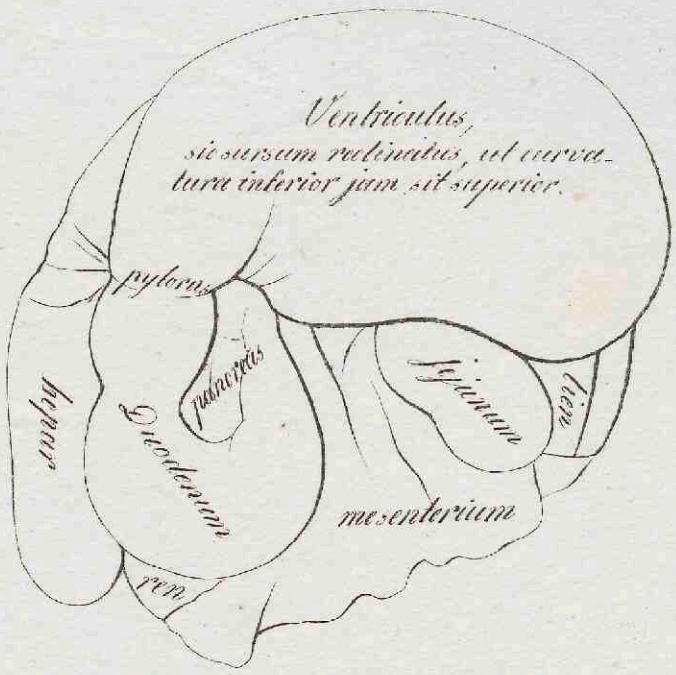
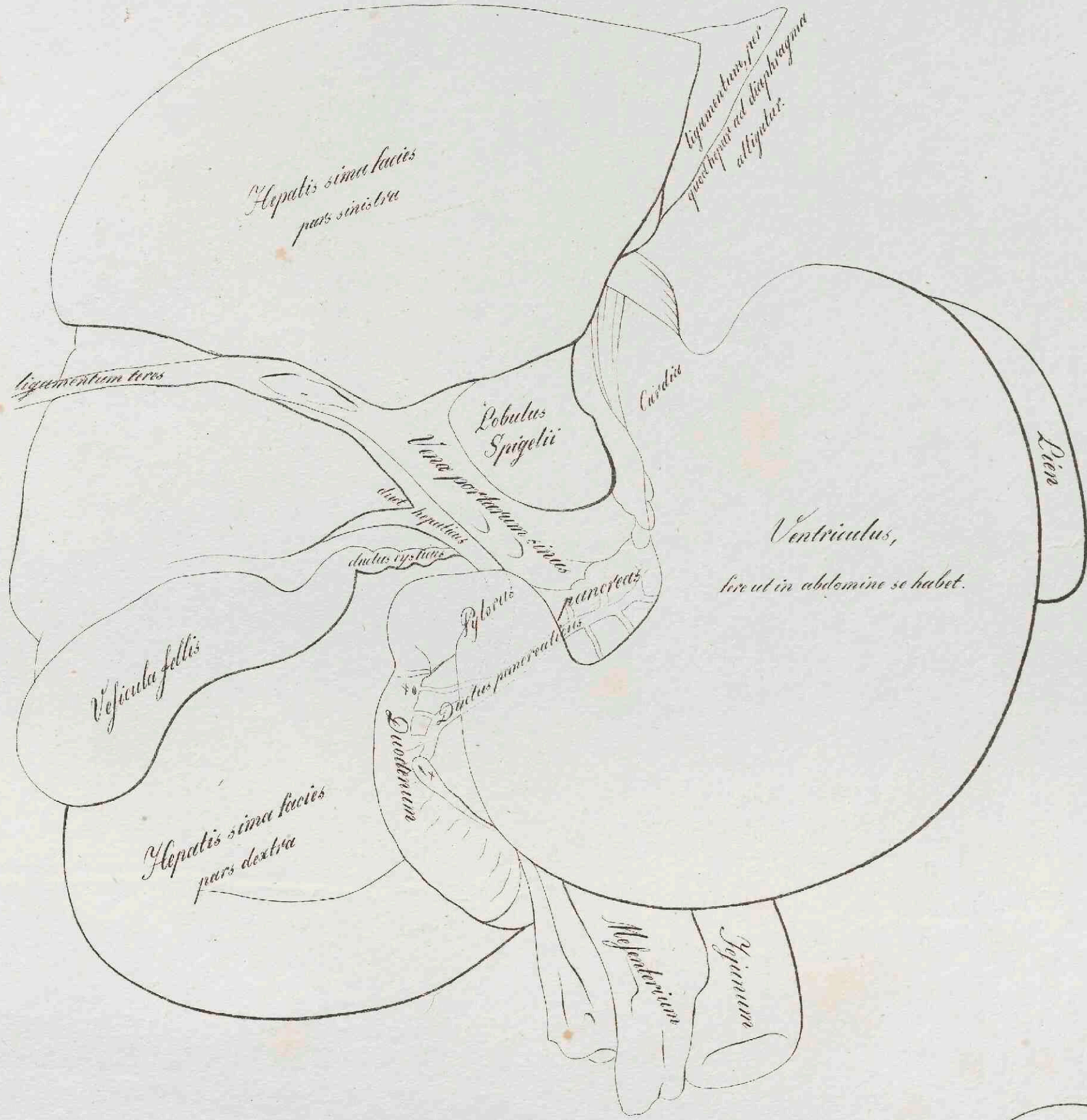


1. Oesophagus. 2. Aorta thoracica. 3. Canalis thoracicus.

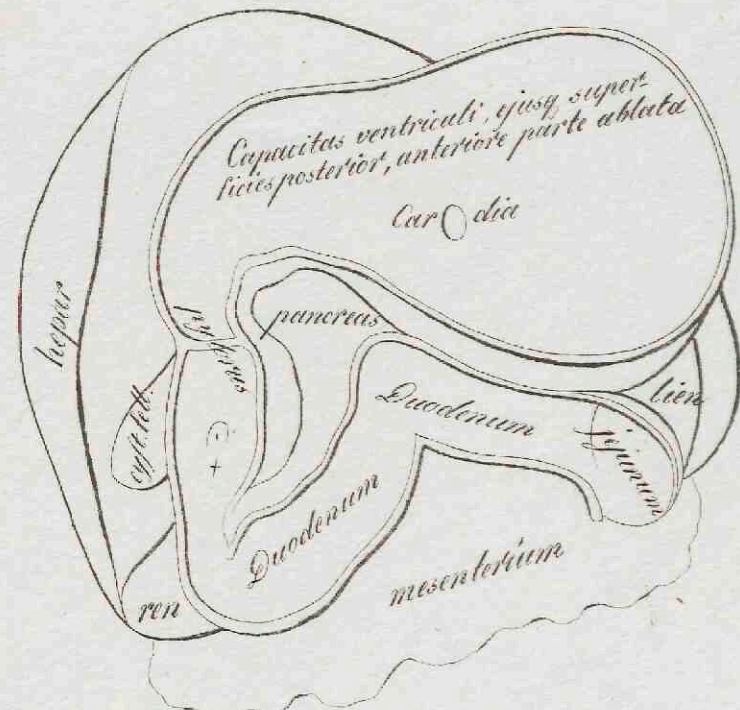


Magen, Leber, Milz, Darm, Drüse,

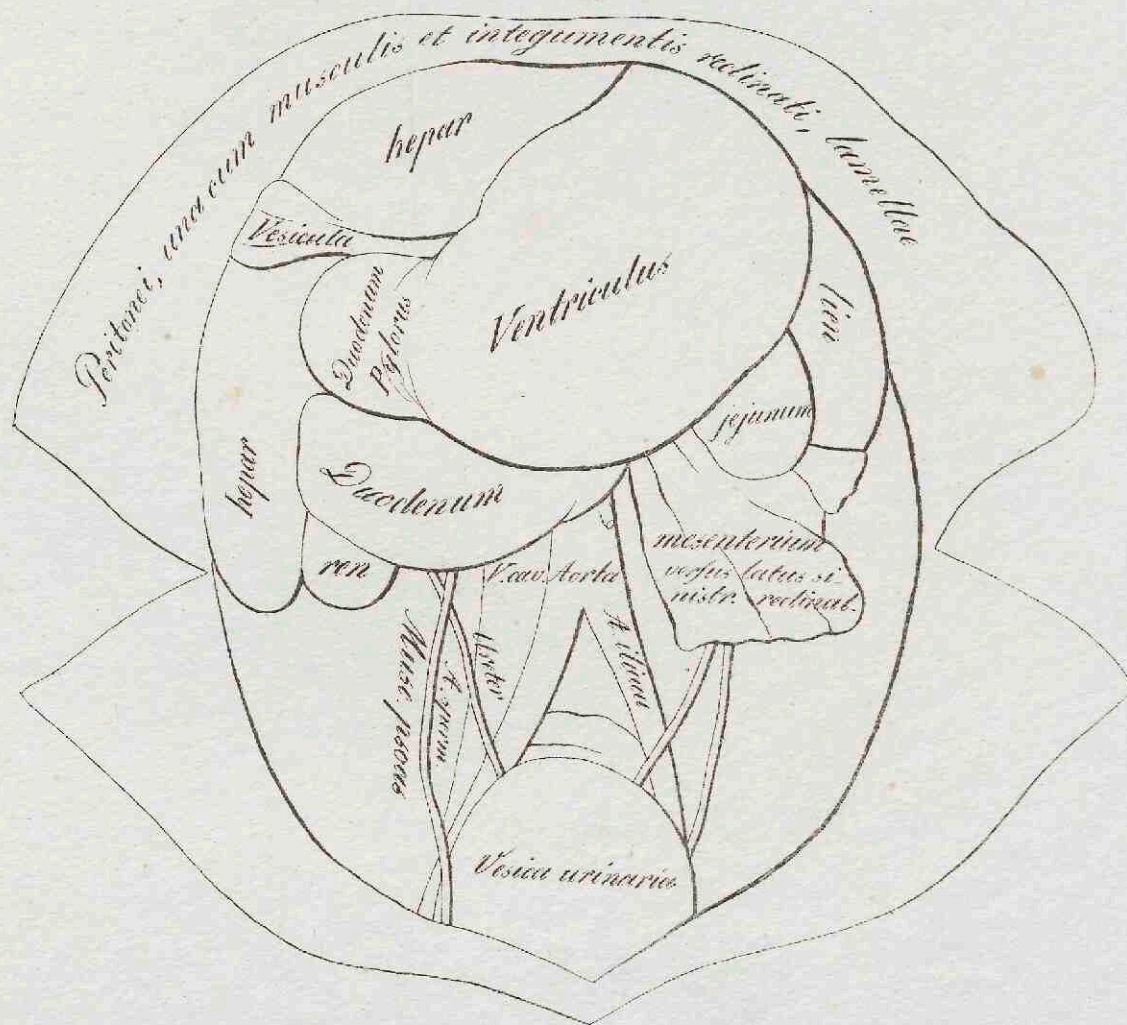
nach Sandifort und Sautorini.

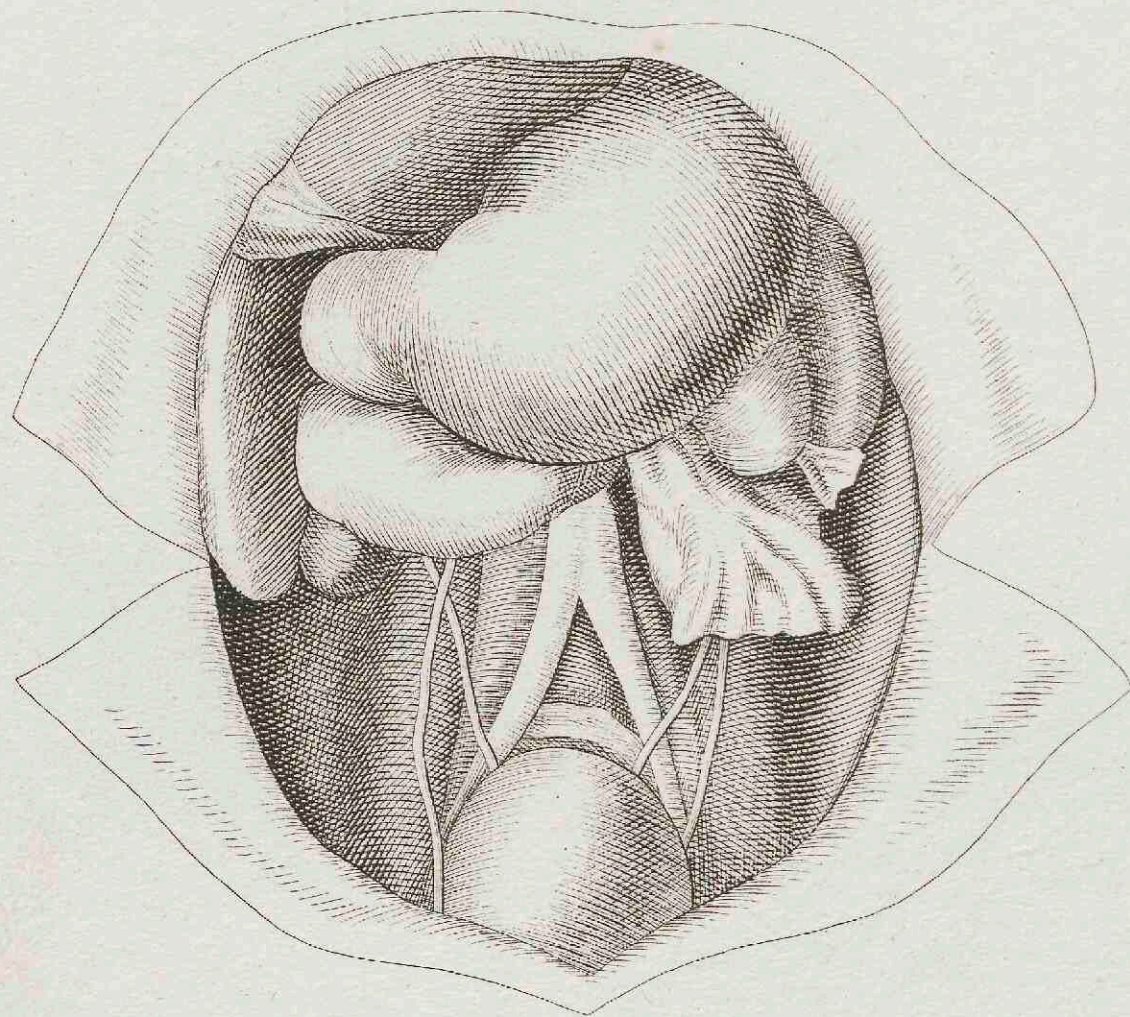
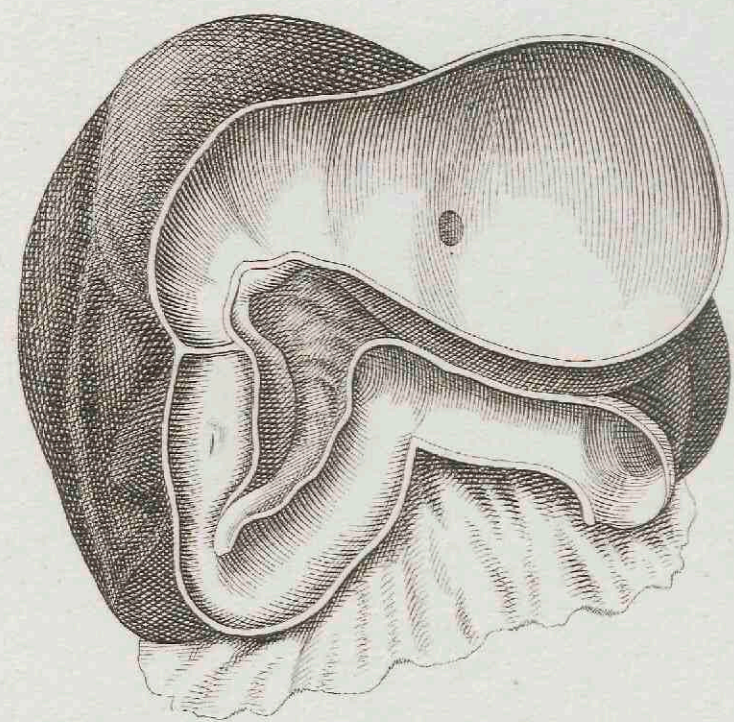
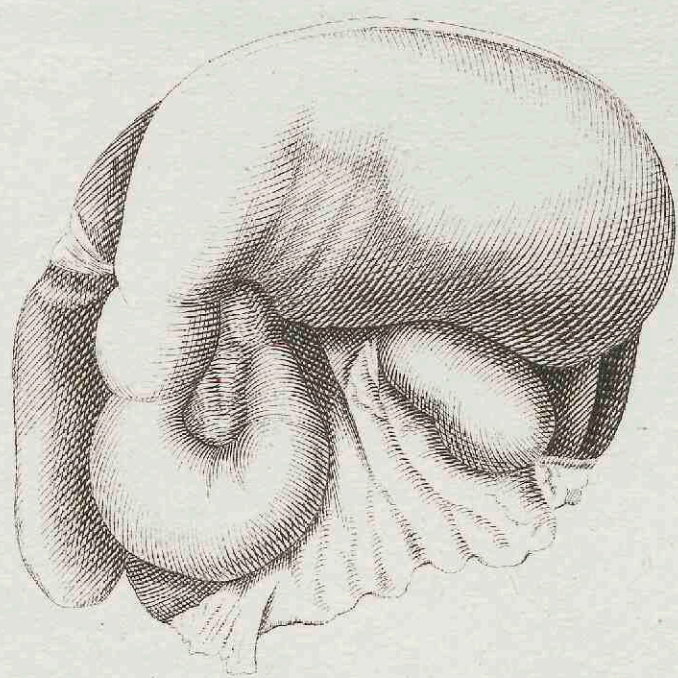
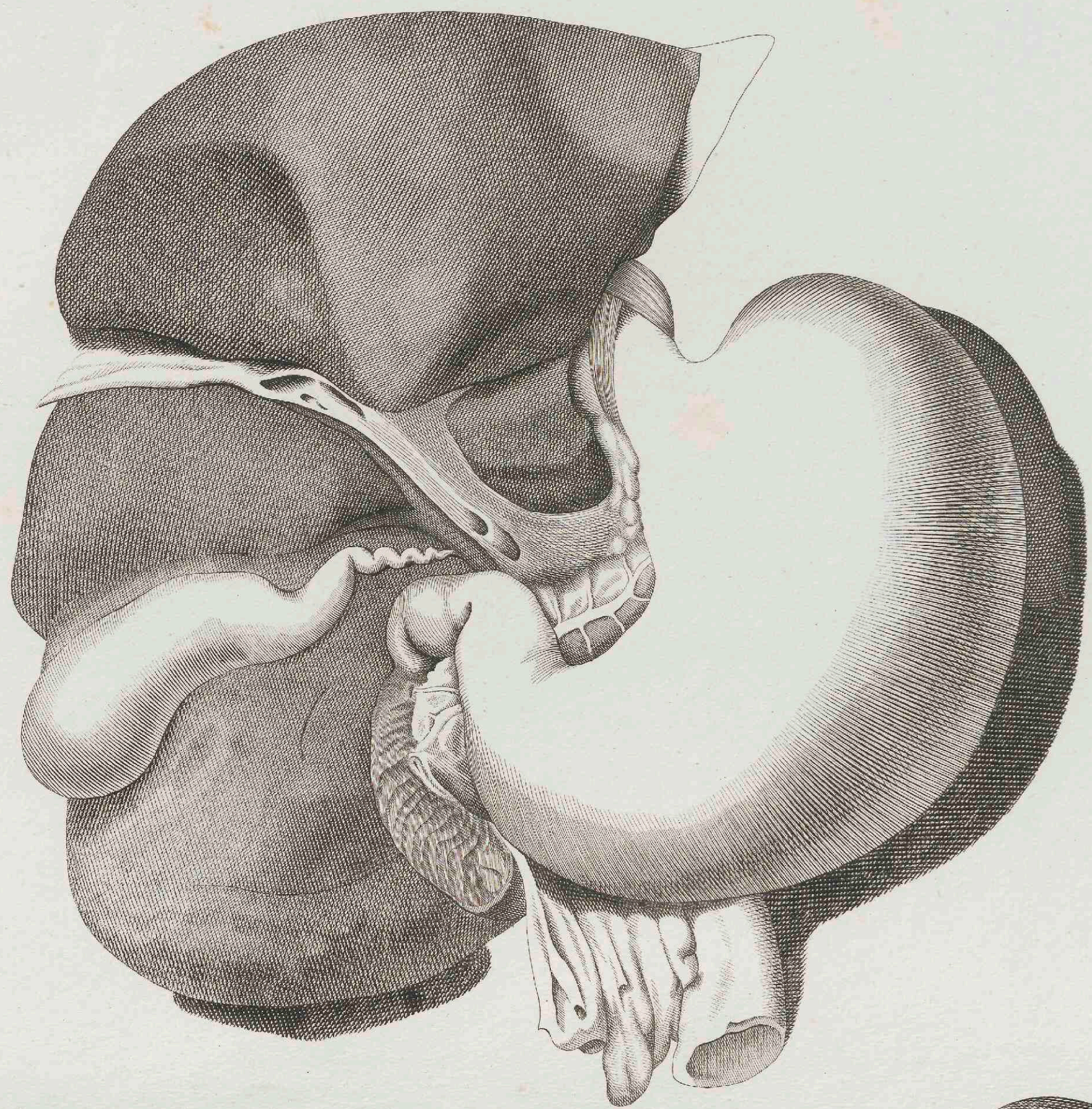


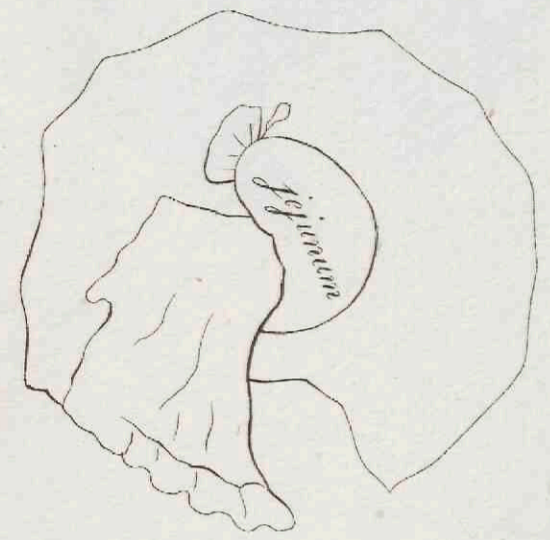
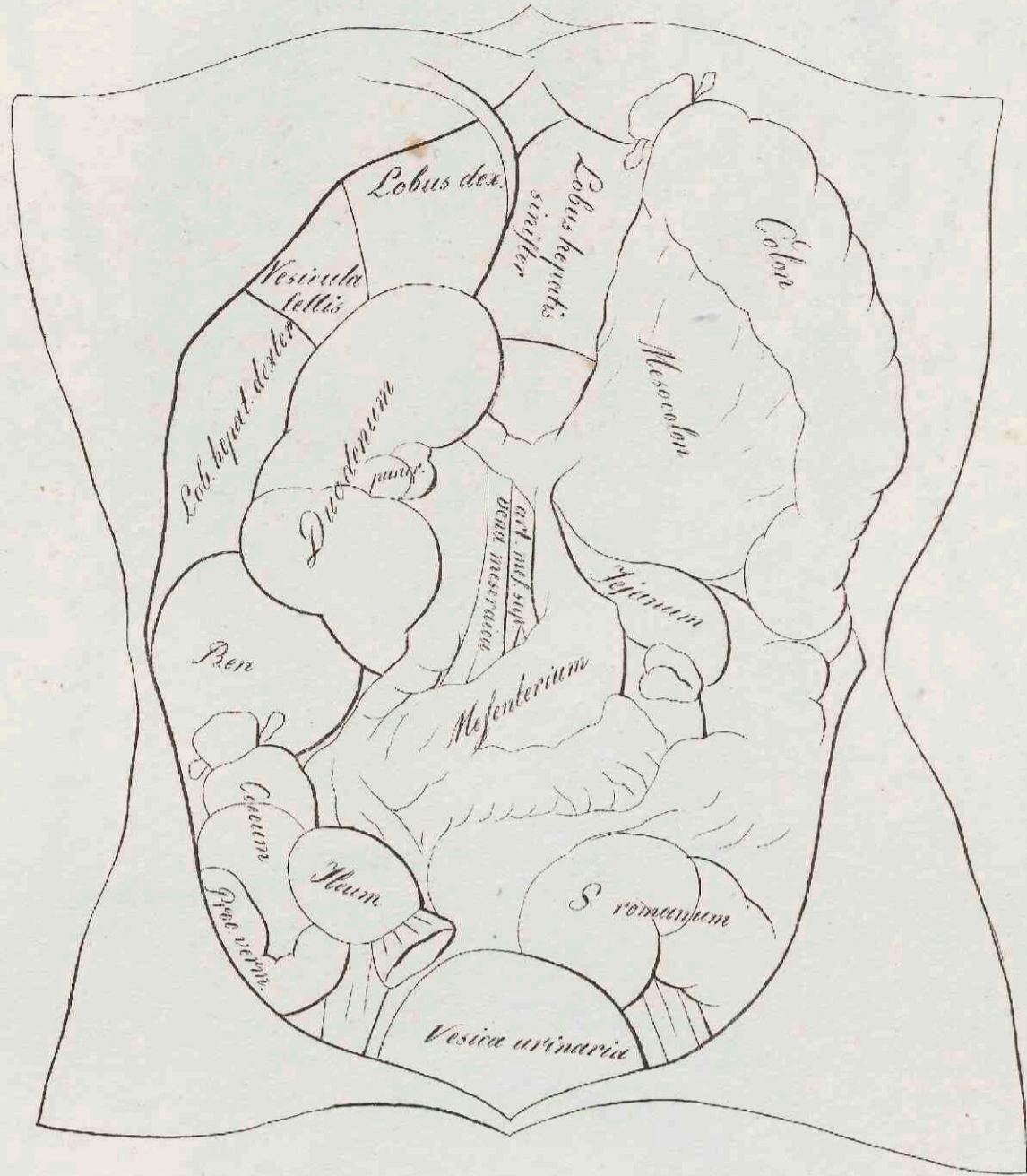
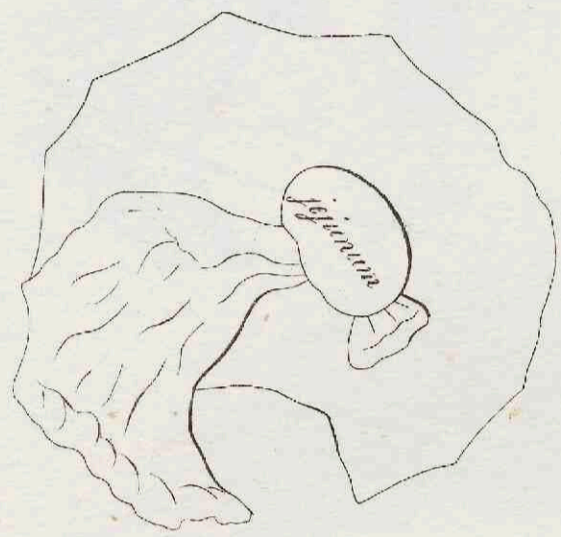
1. aperturam communem ductus cholechochi et pancreatici
 2. aperturam superioris ductus pancreatici



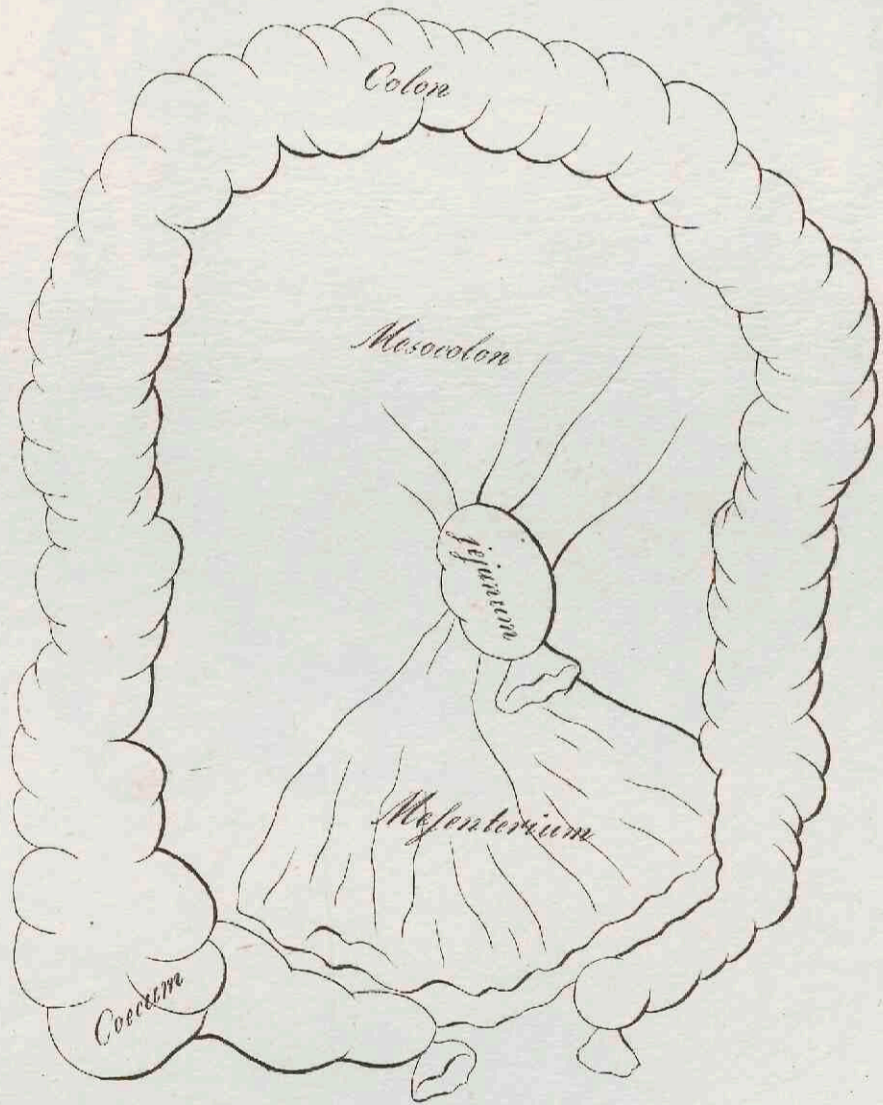
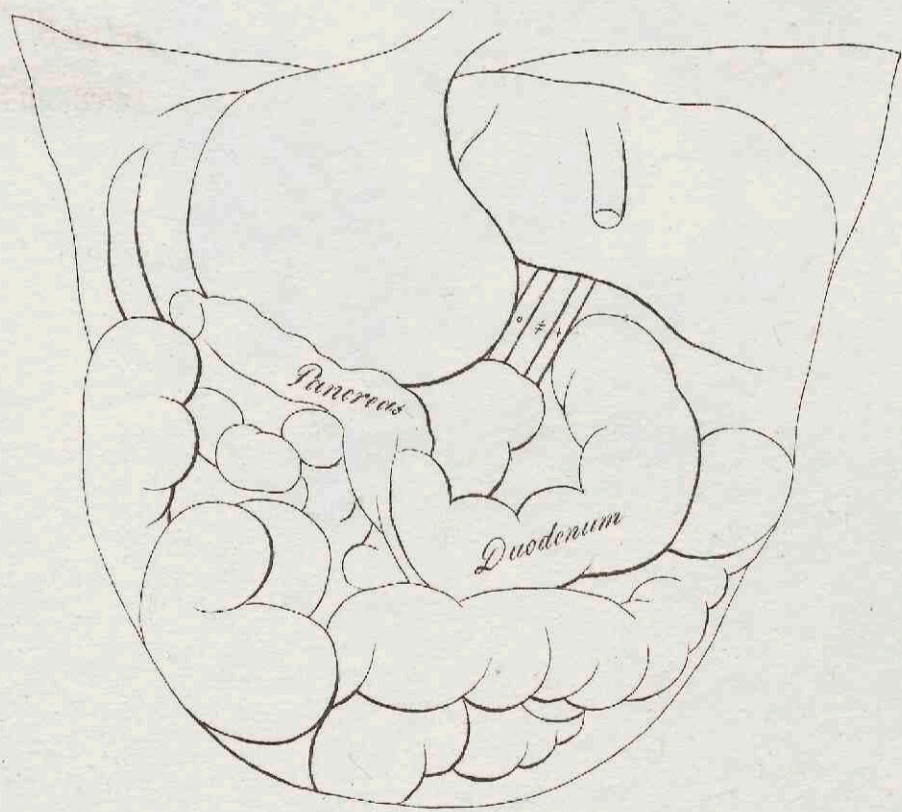
1. aperturam ductus cholechochi et pancreatici



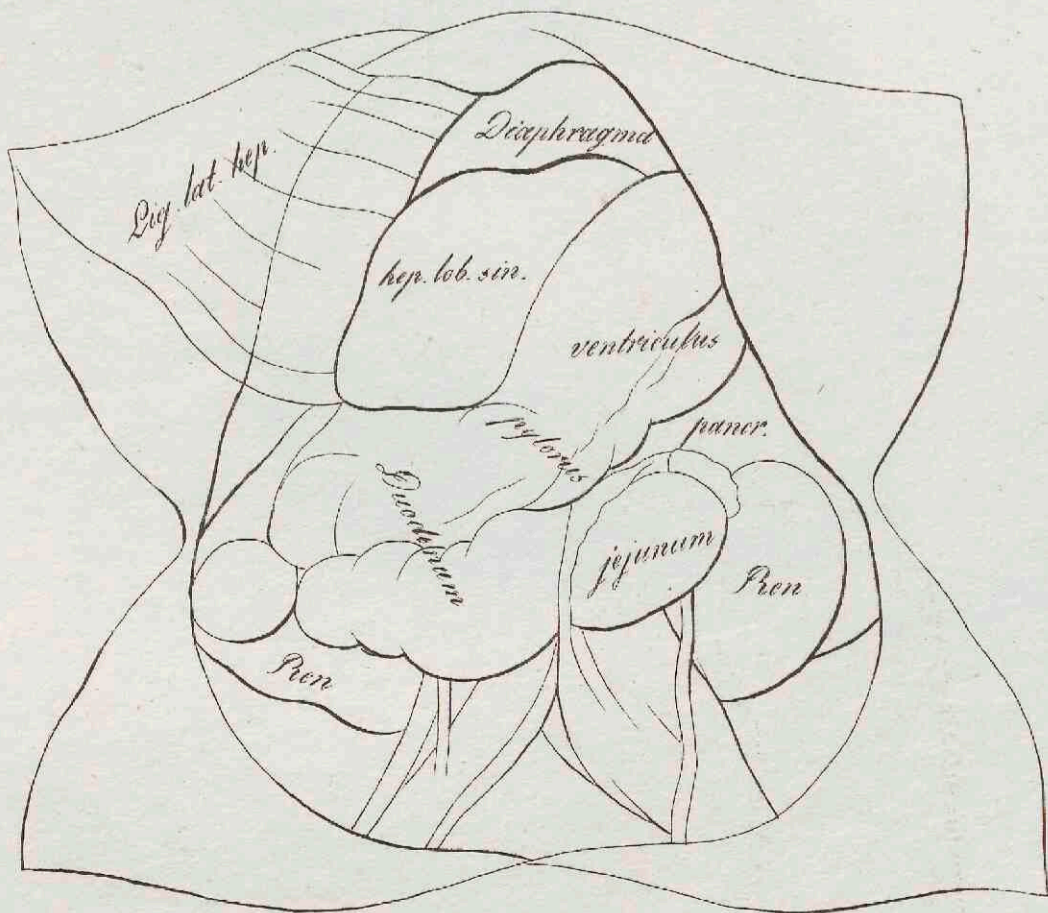
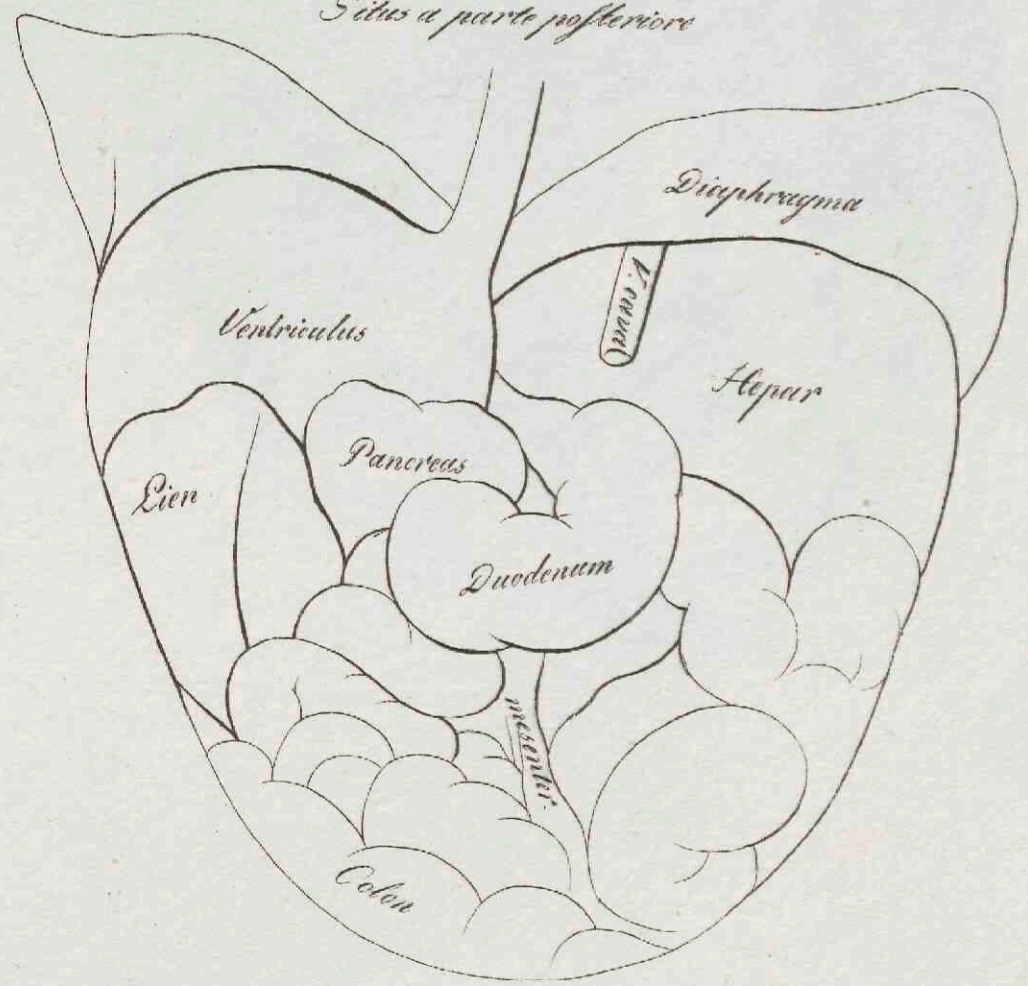




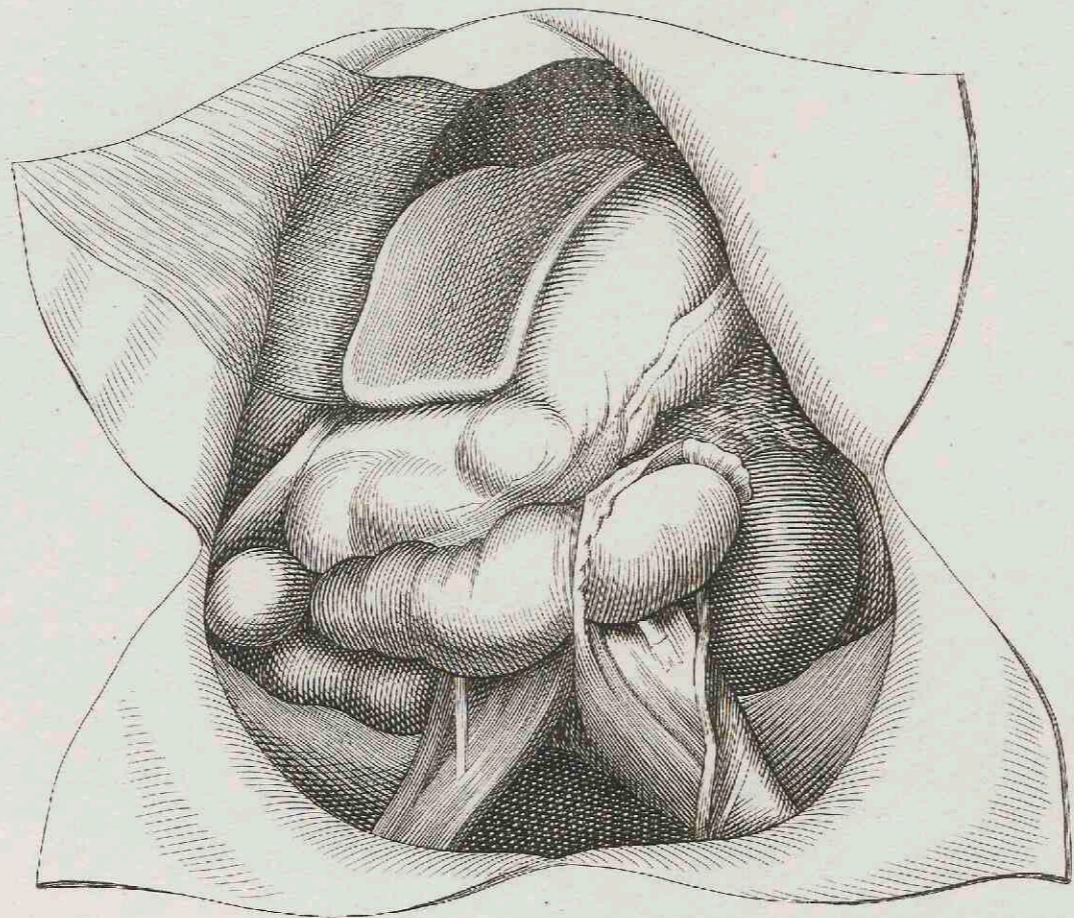
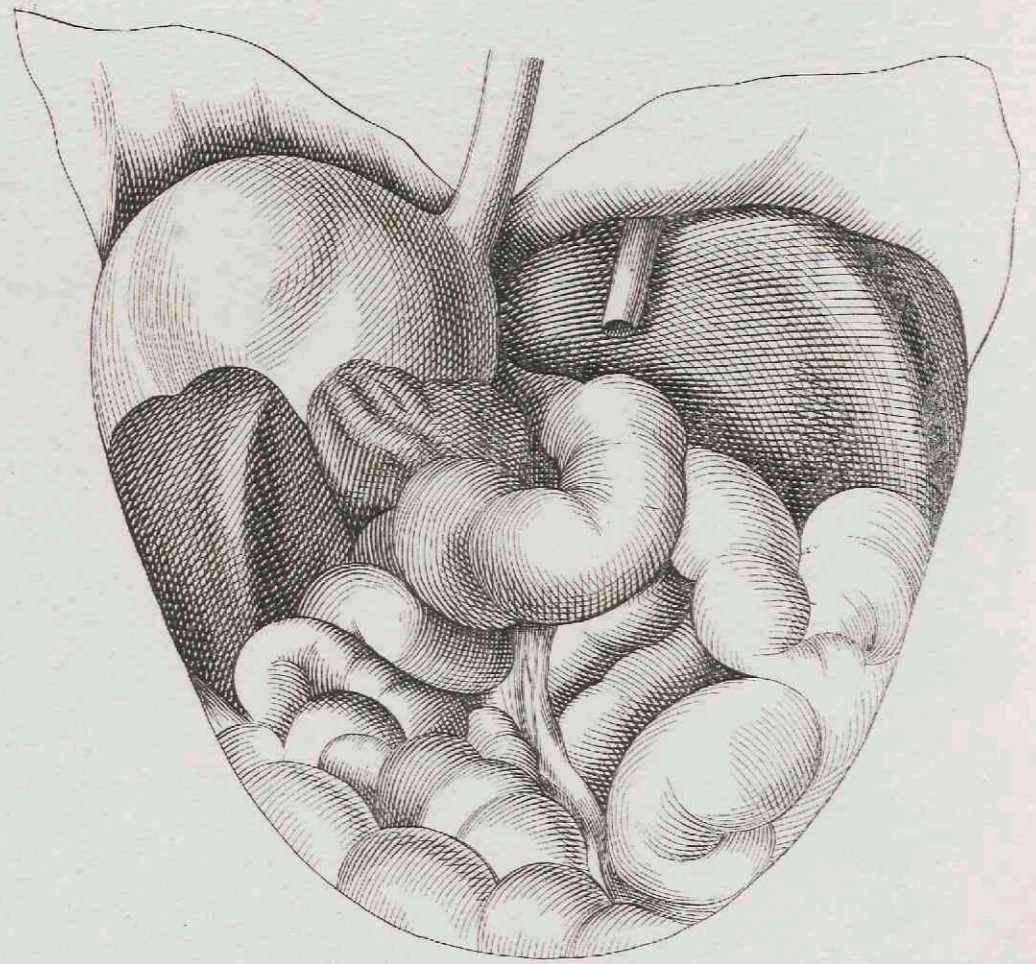
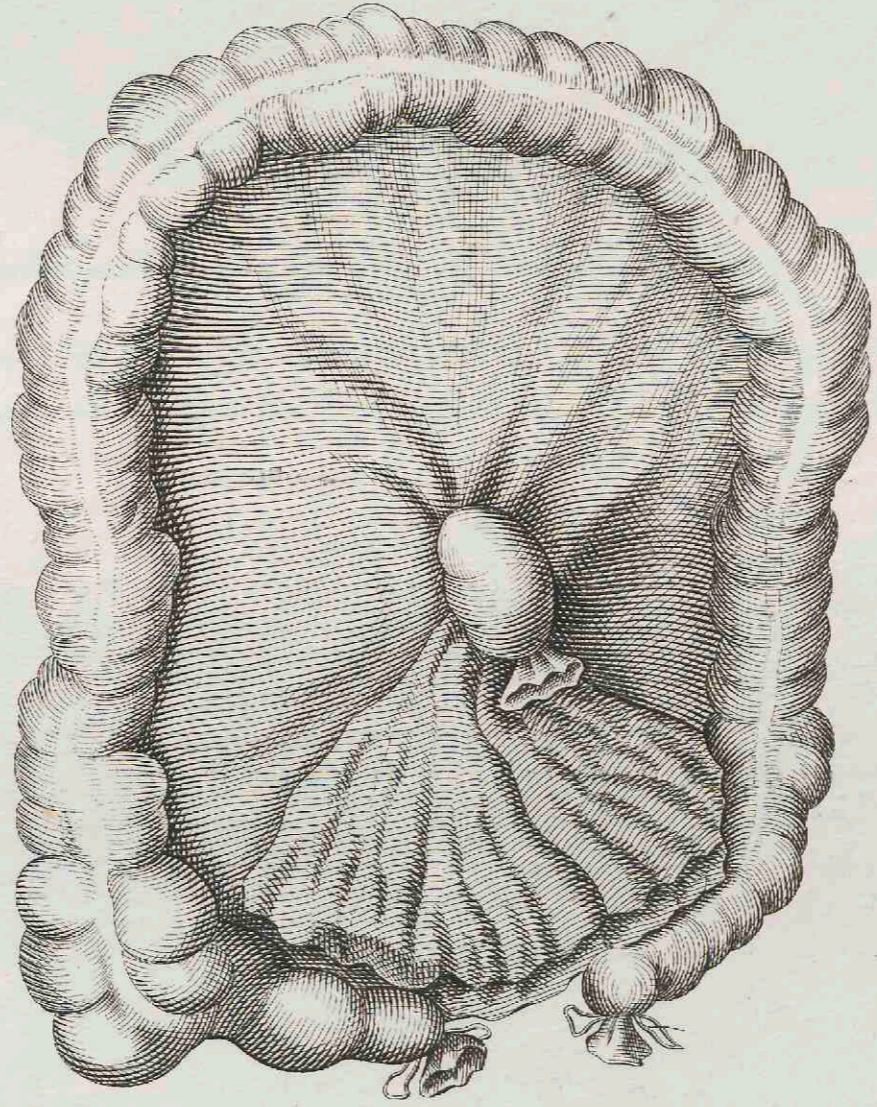
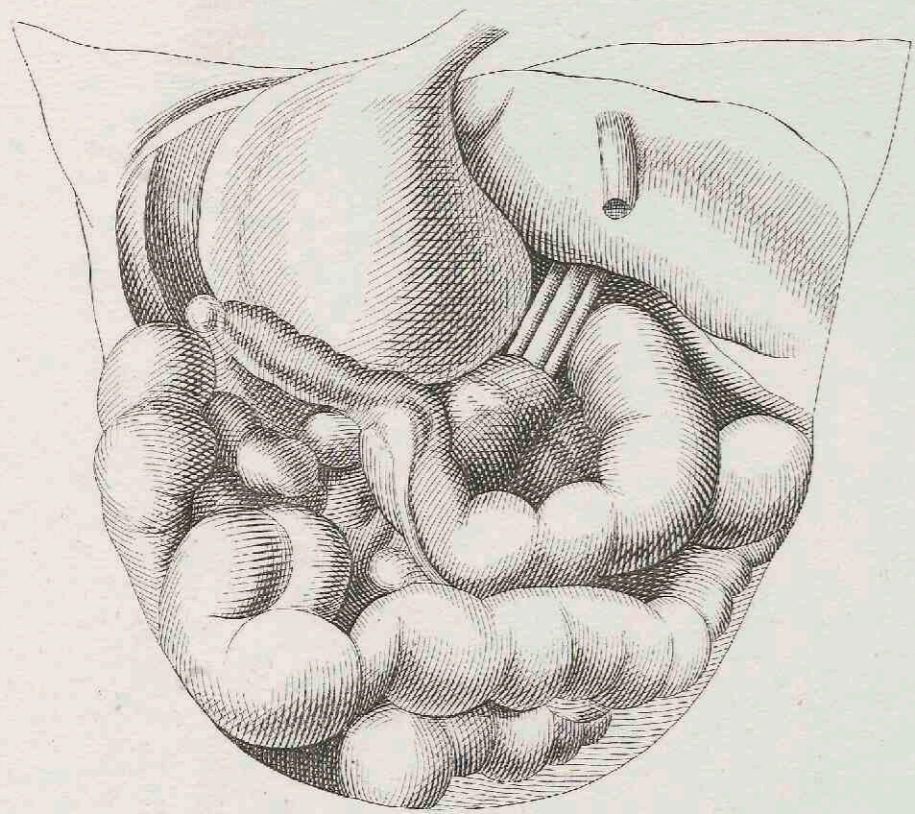
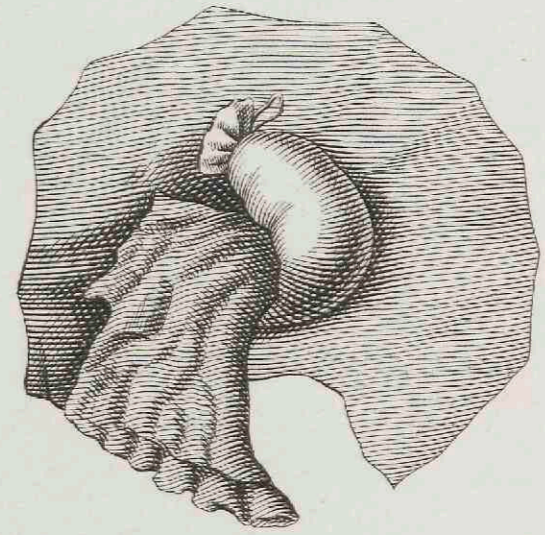
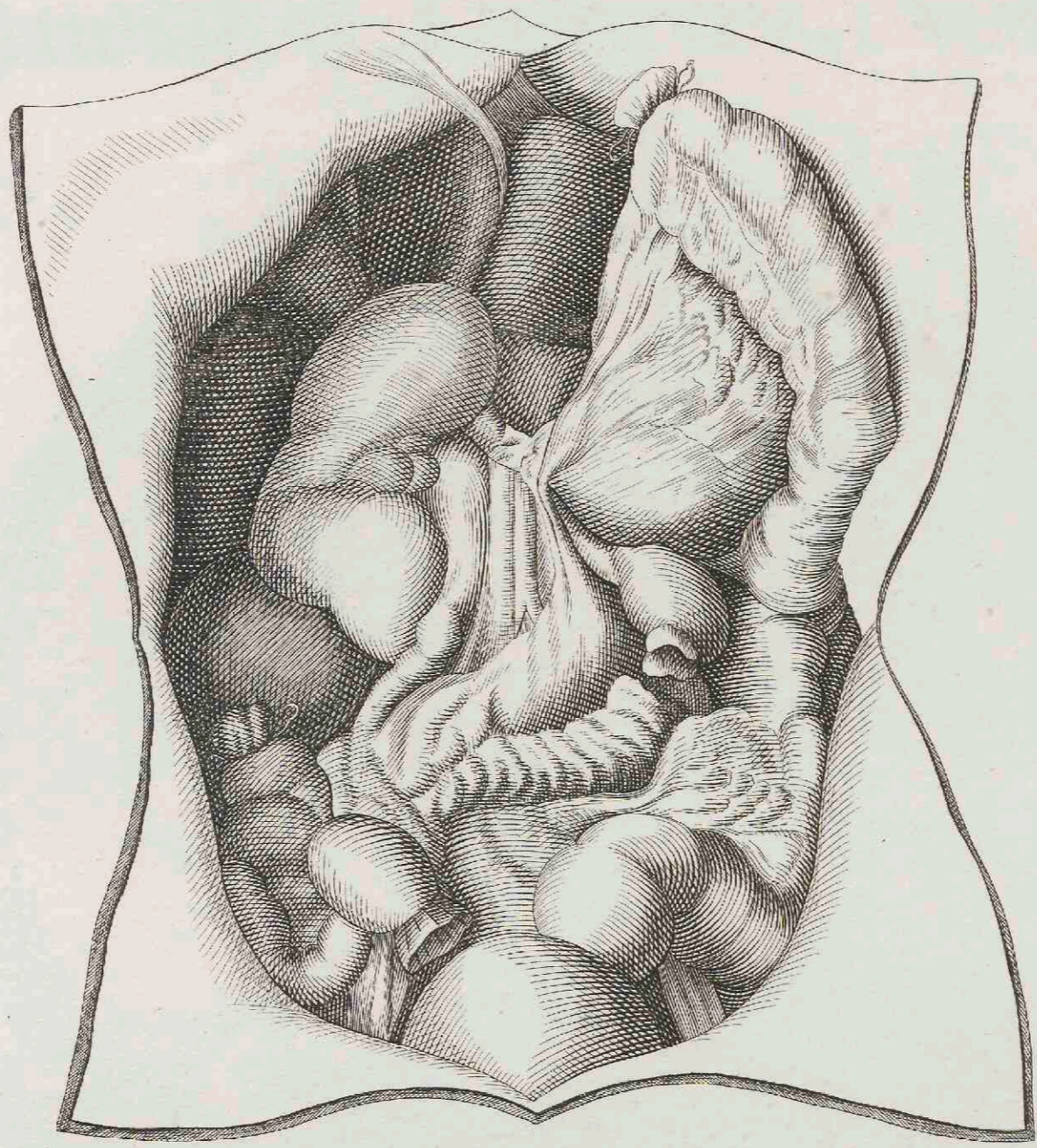
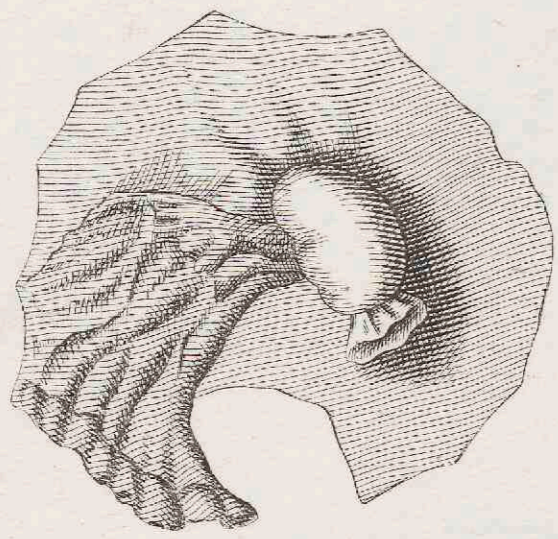
duct choledochus. + vena port. + art. hep.



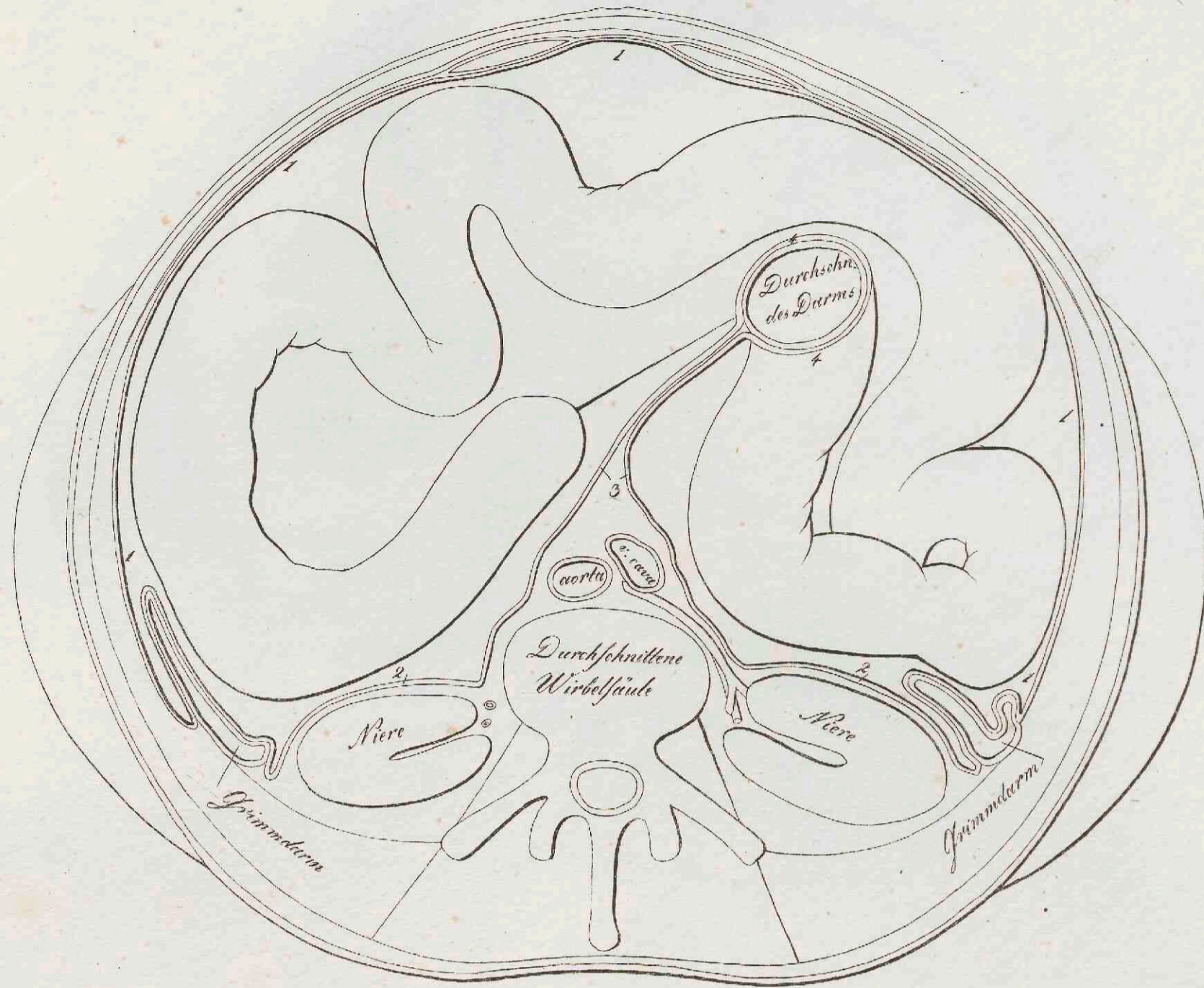
Setus a parte posteriori



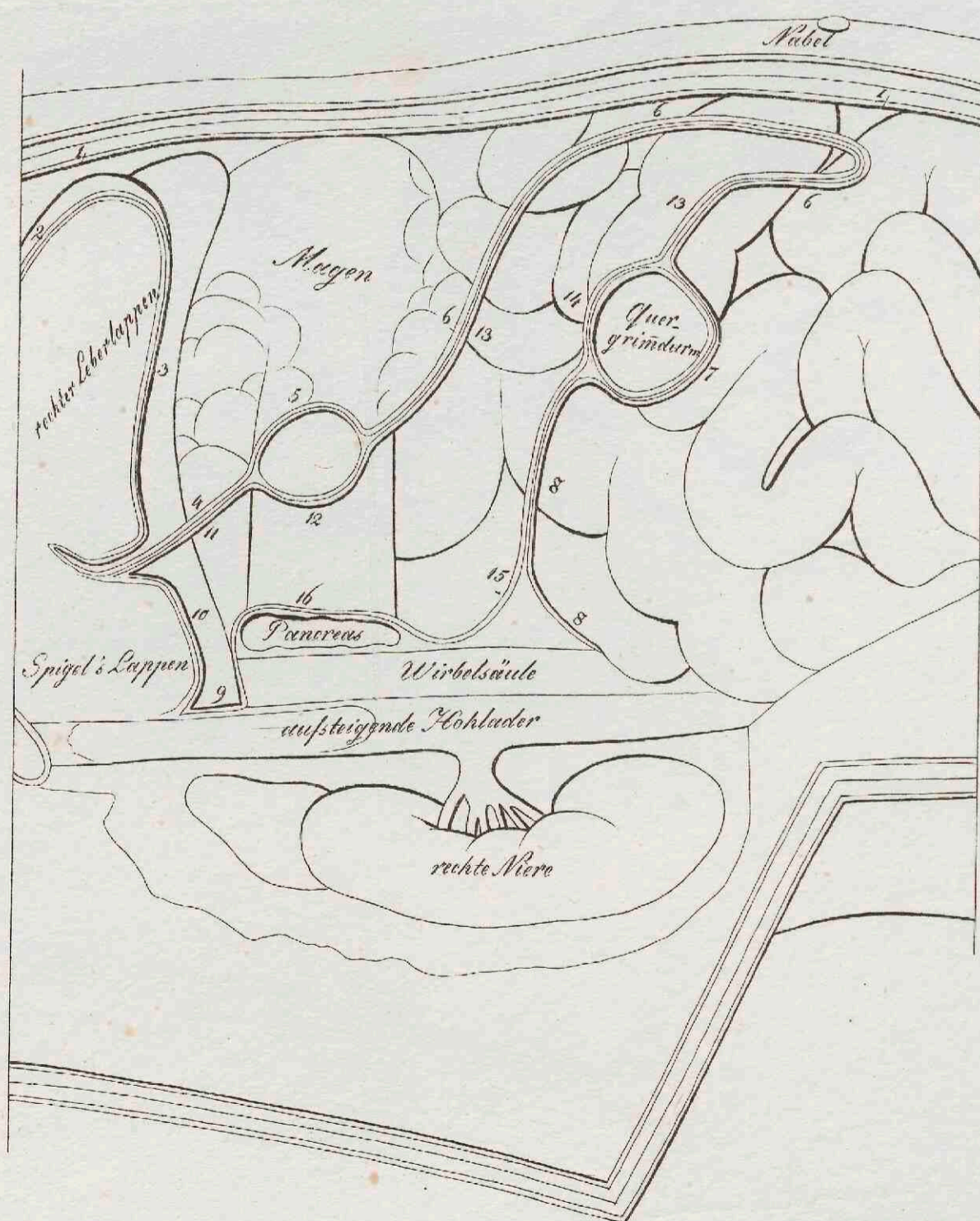
Status morbosus



Bauchfell, Gekroes, Netze, nach Froriep.

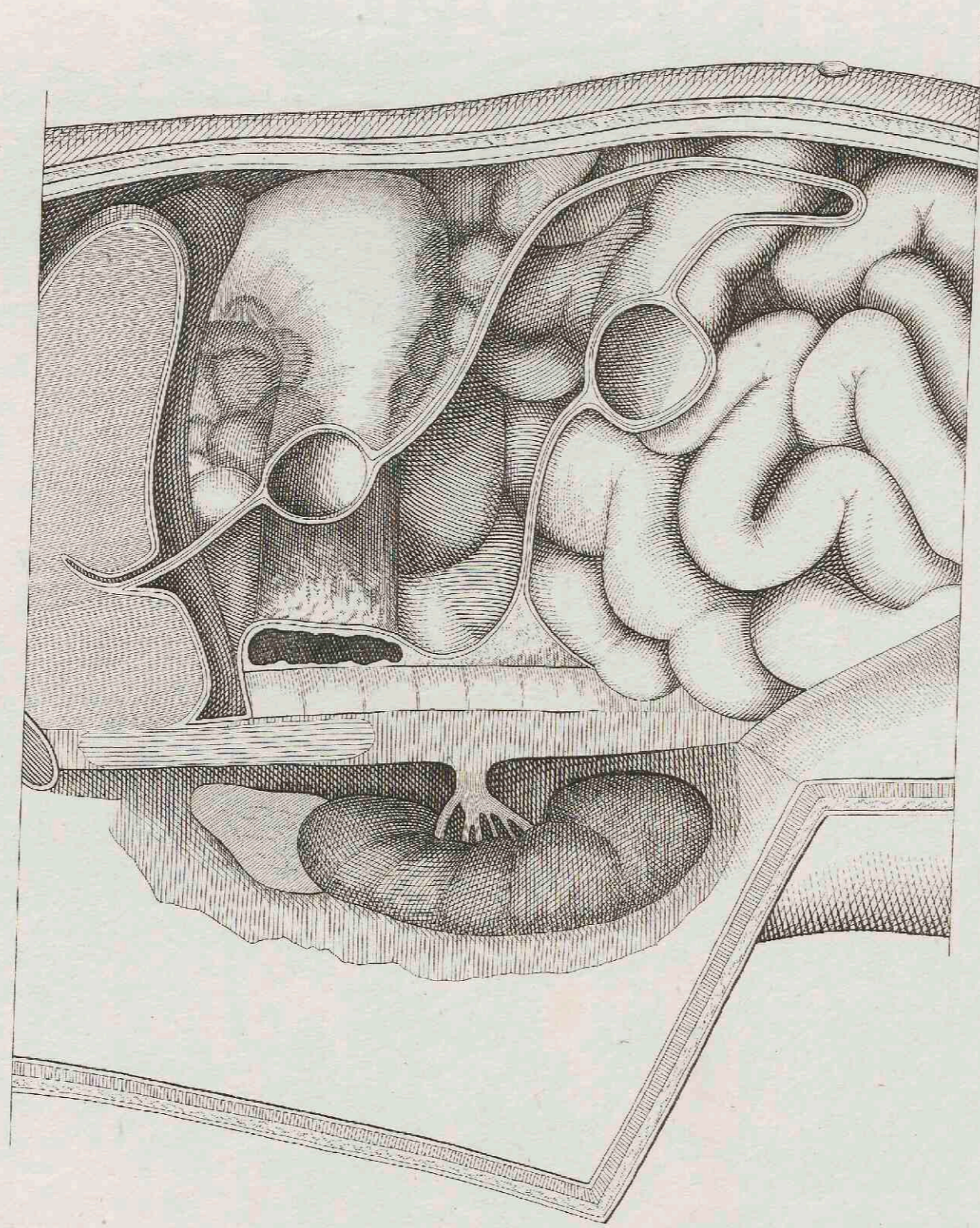
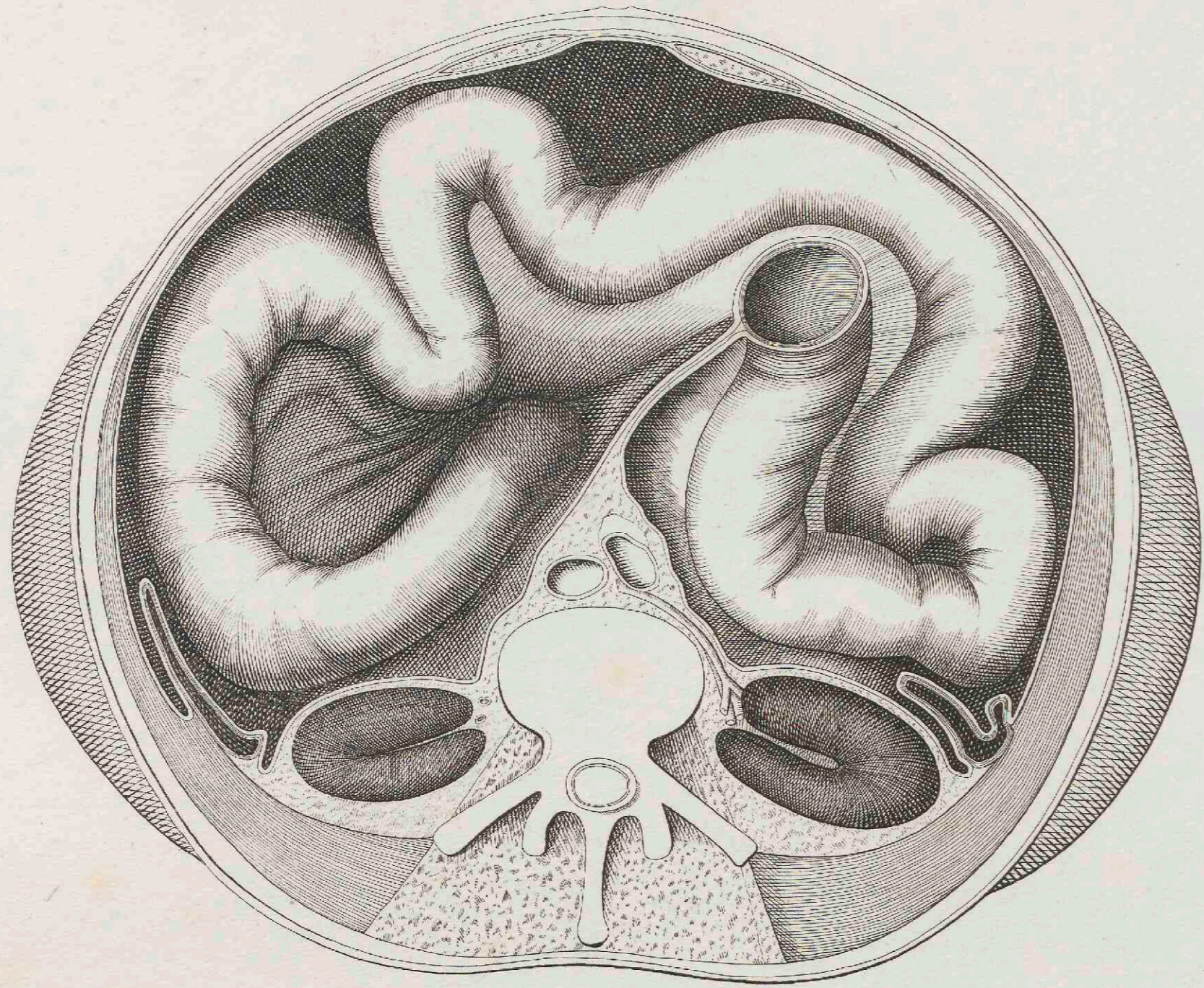


Querdurchschnitt des Unterleibs an der, horizontal auf den Rücken gelegten Leiche eines Erwachsenen (Stüchtige Zeichnung, 2/3 (S) verkleinert.)
 1. das Bauchfell, wie es die Wände der Unterleibshöhle vorn u. zur Seite auskleidet, 2. vor den Nieren sich weschleigt, 3. wie es, von hinten Seiten herkommend, vor der Wirbelsäule und den, mit Fettgewebe umgebenen, großen Gefäßen sich an einanderlegt, und 4. dadurch, daß die Blätter des Peritonäums sich am Darms von einander begeben, die äußere Haut des Darmkanals bilden.

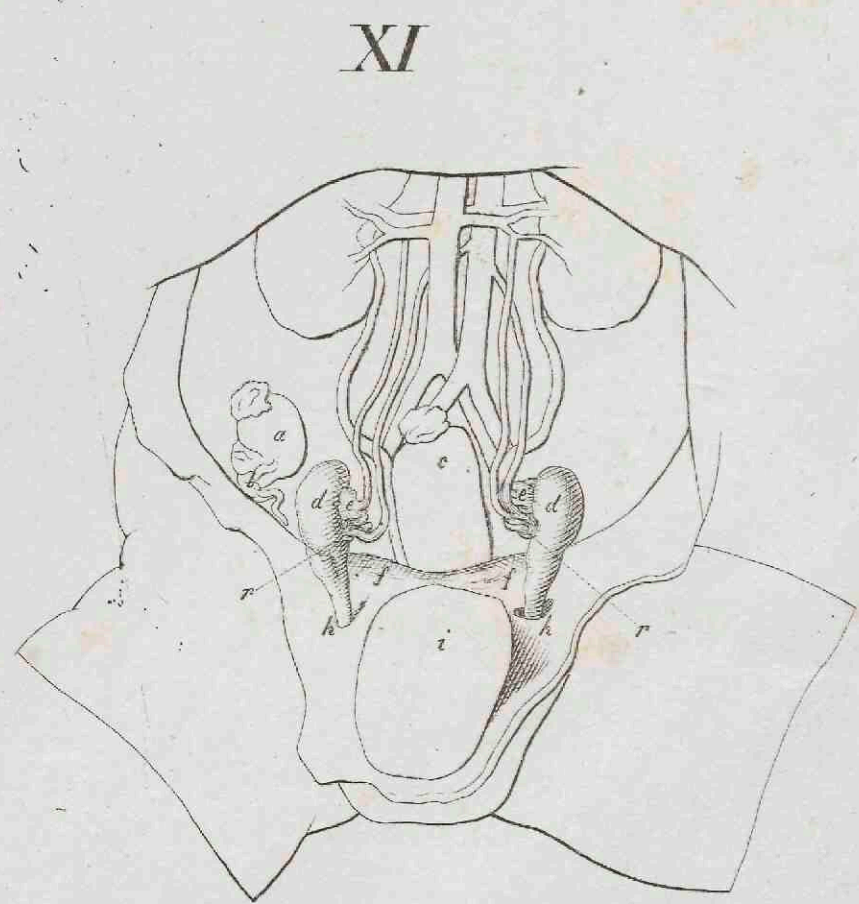
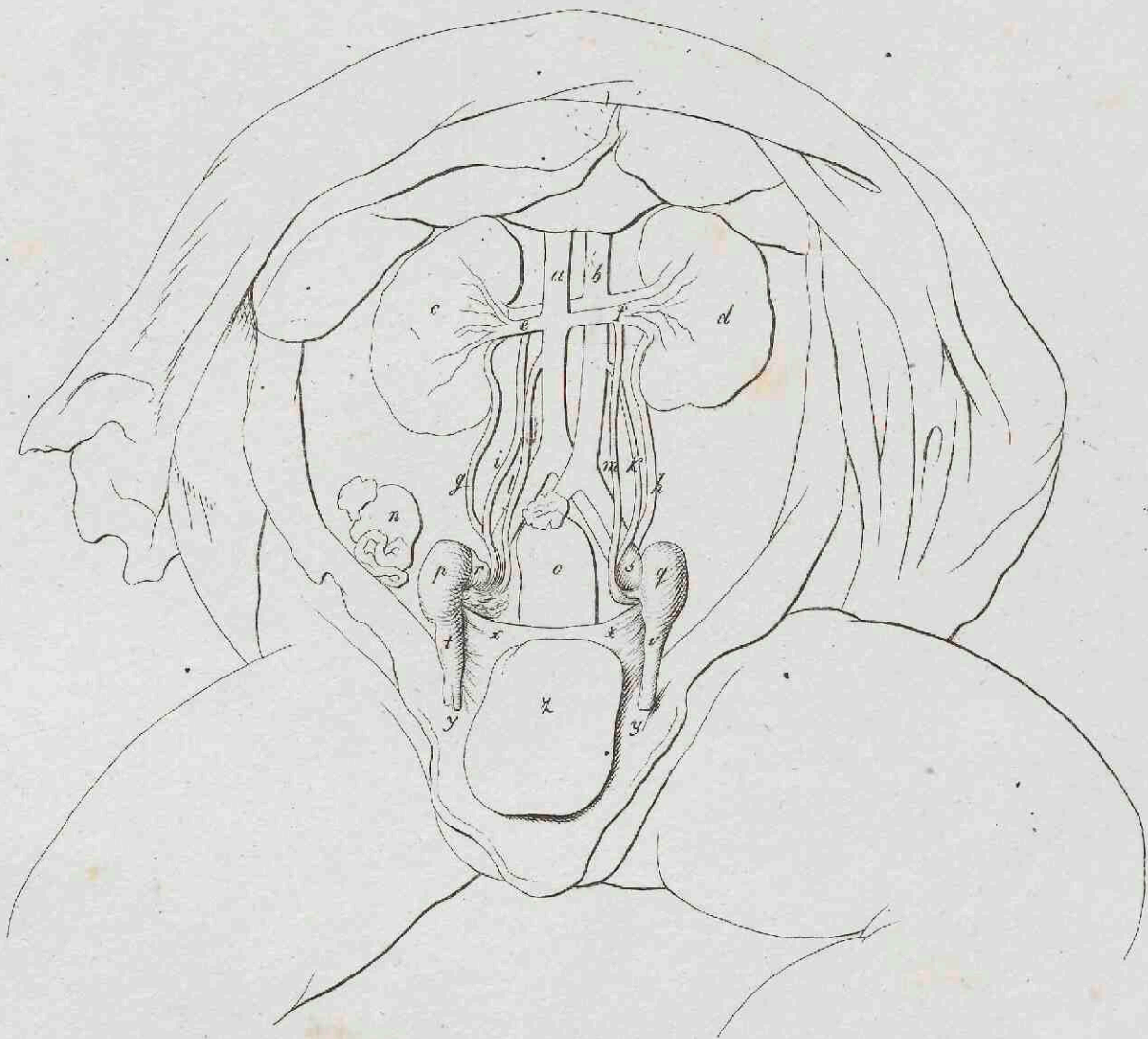
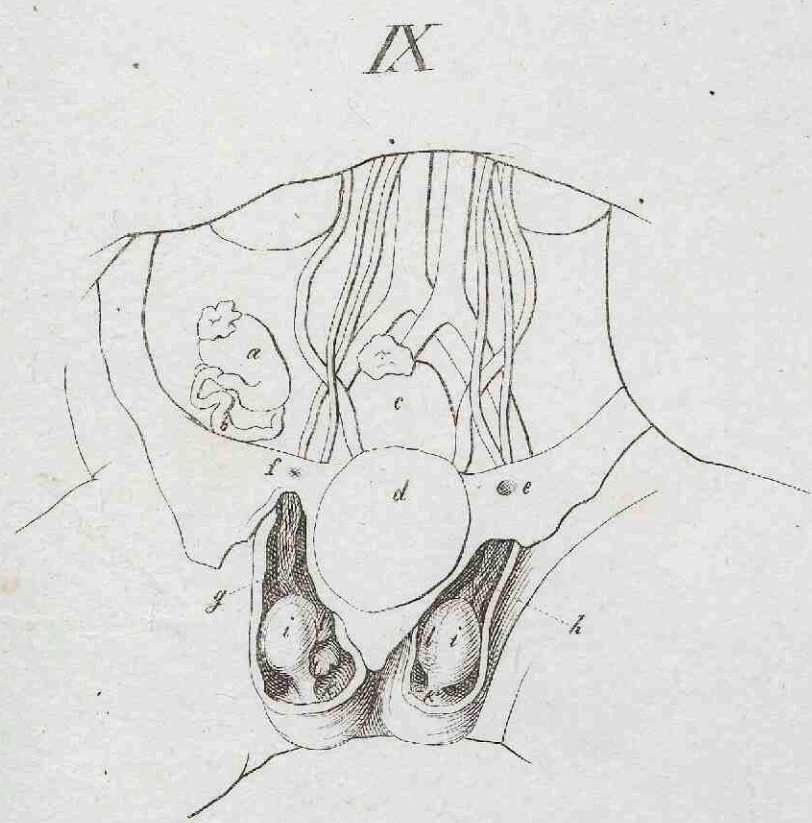
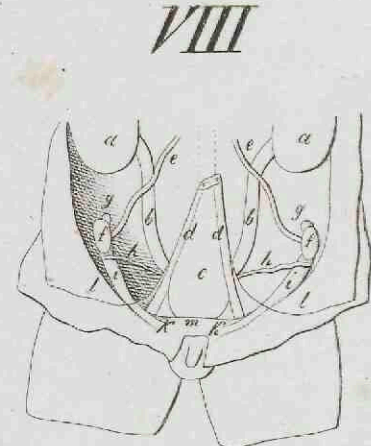
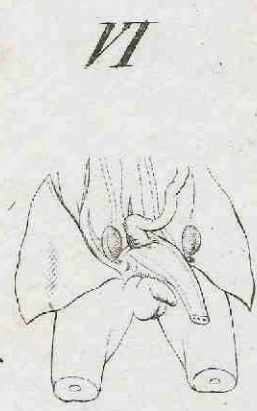
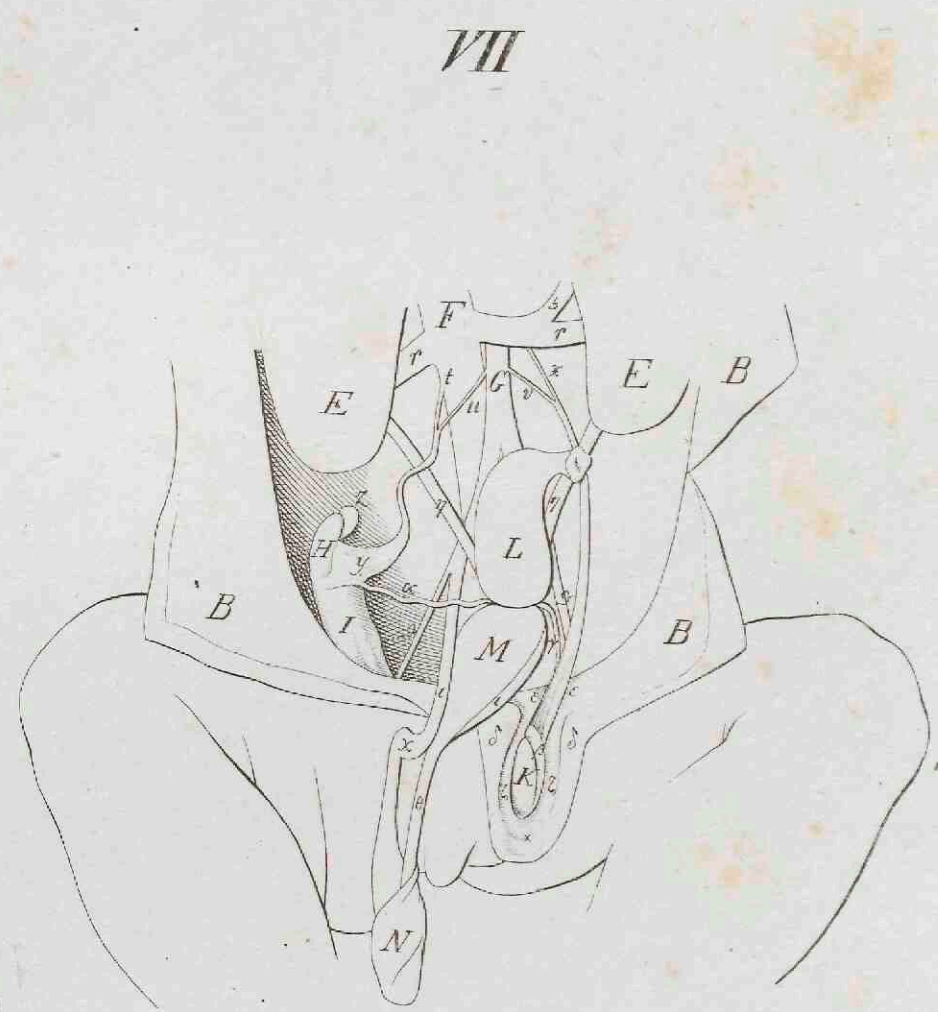
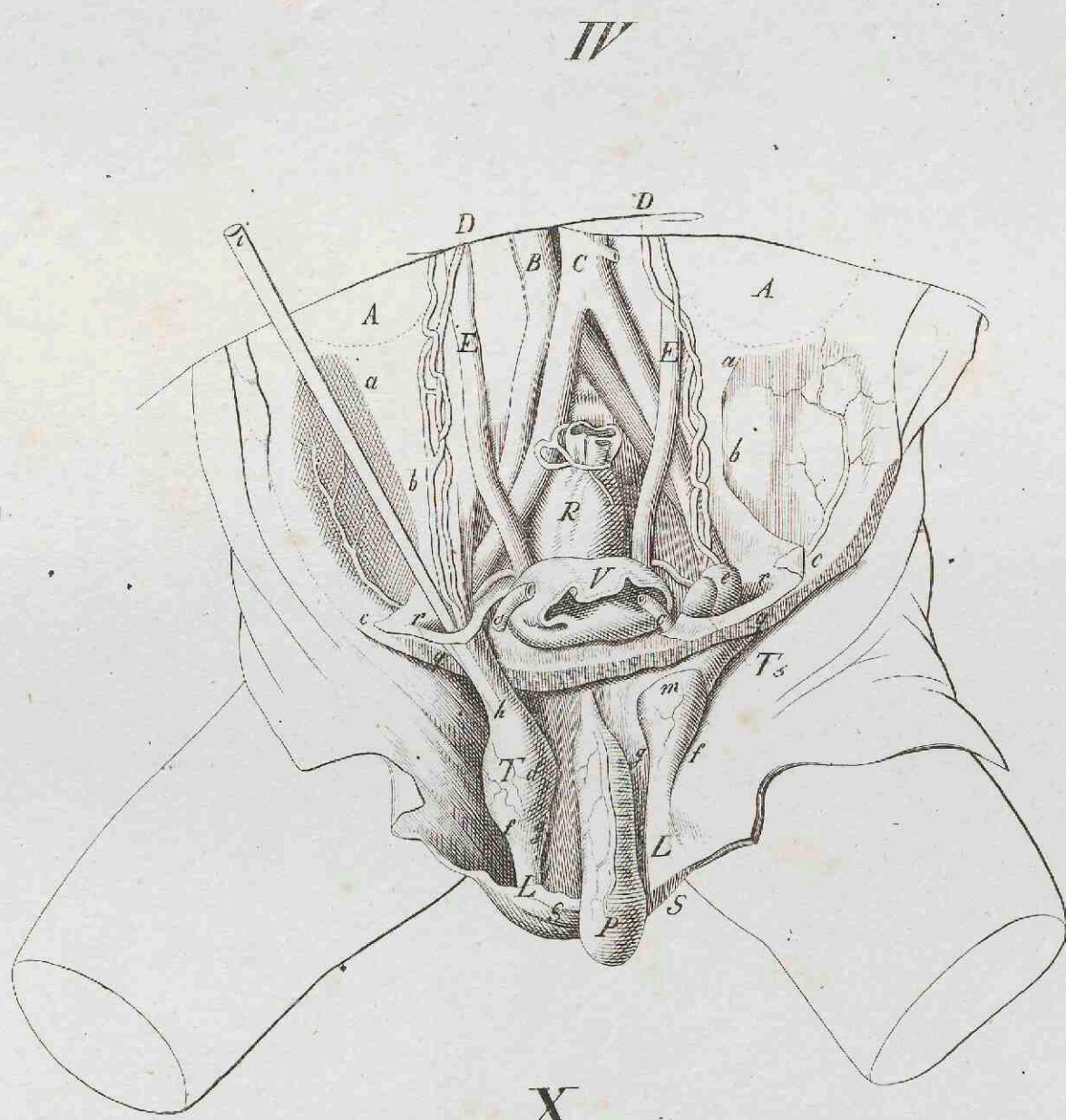
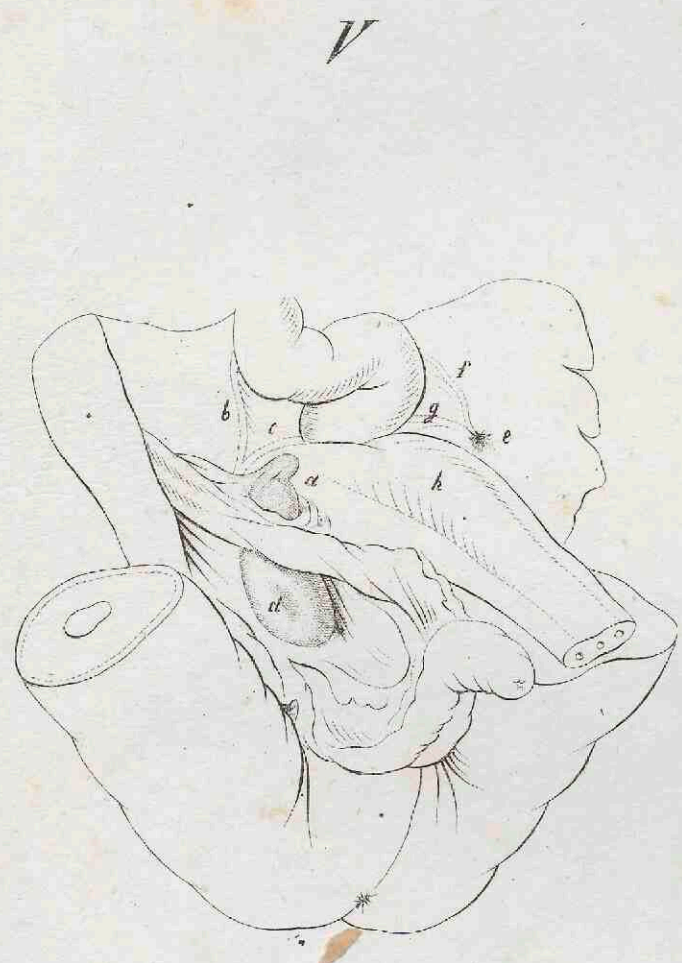
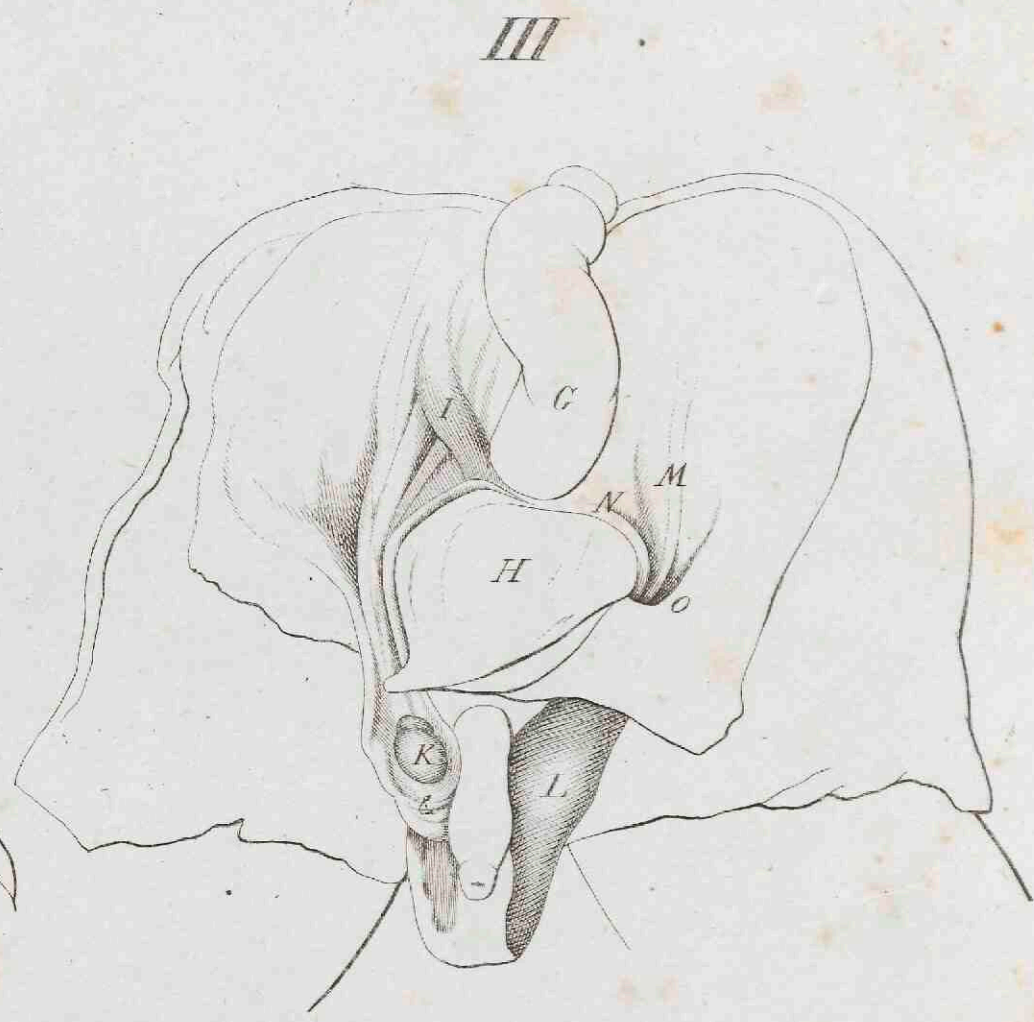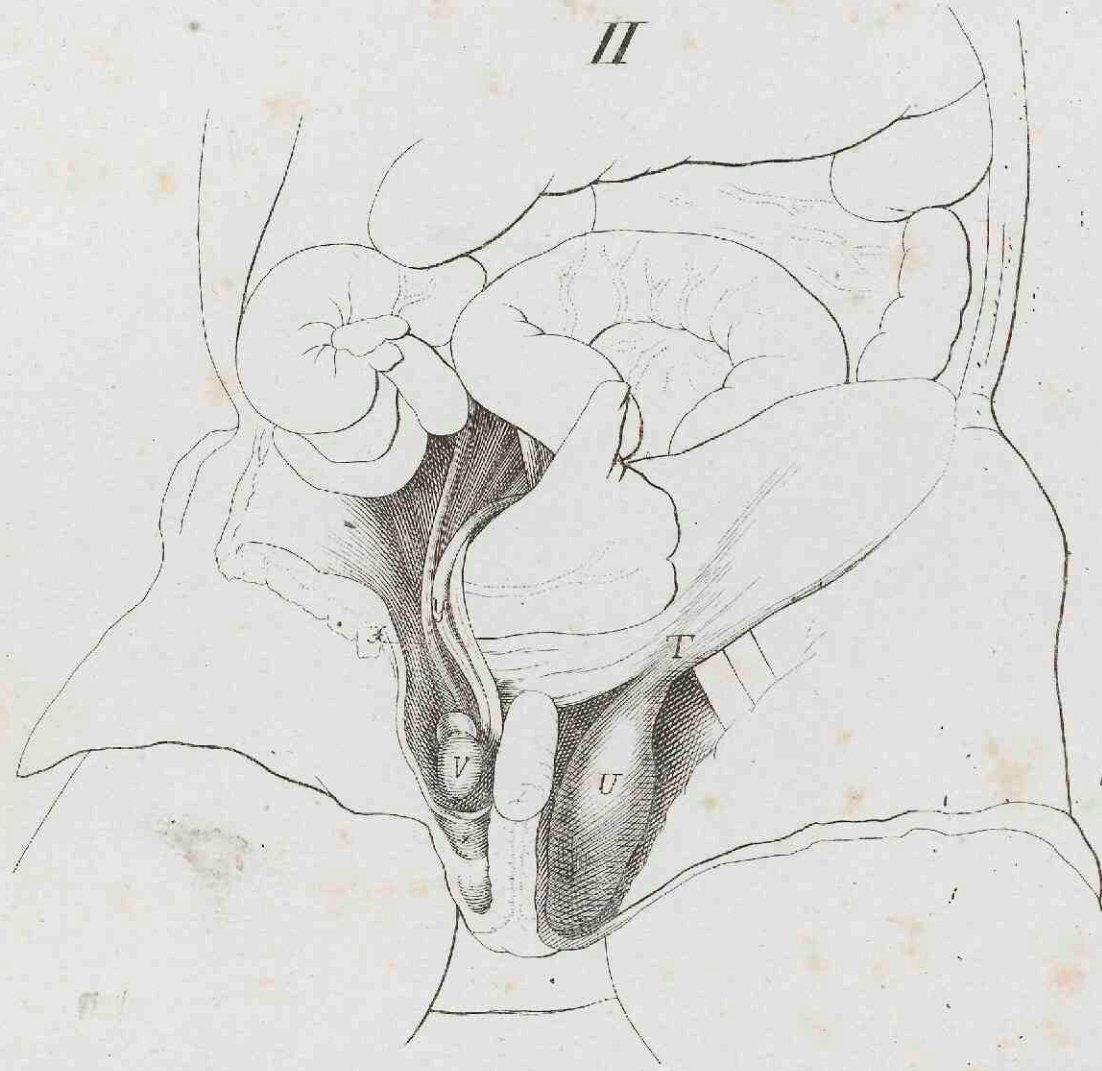
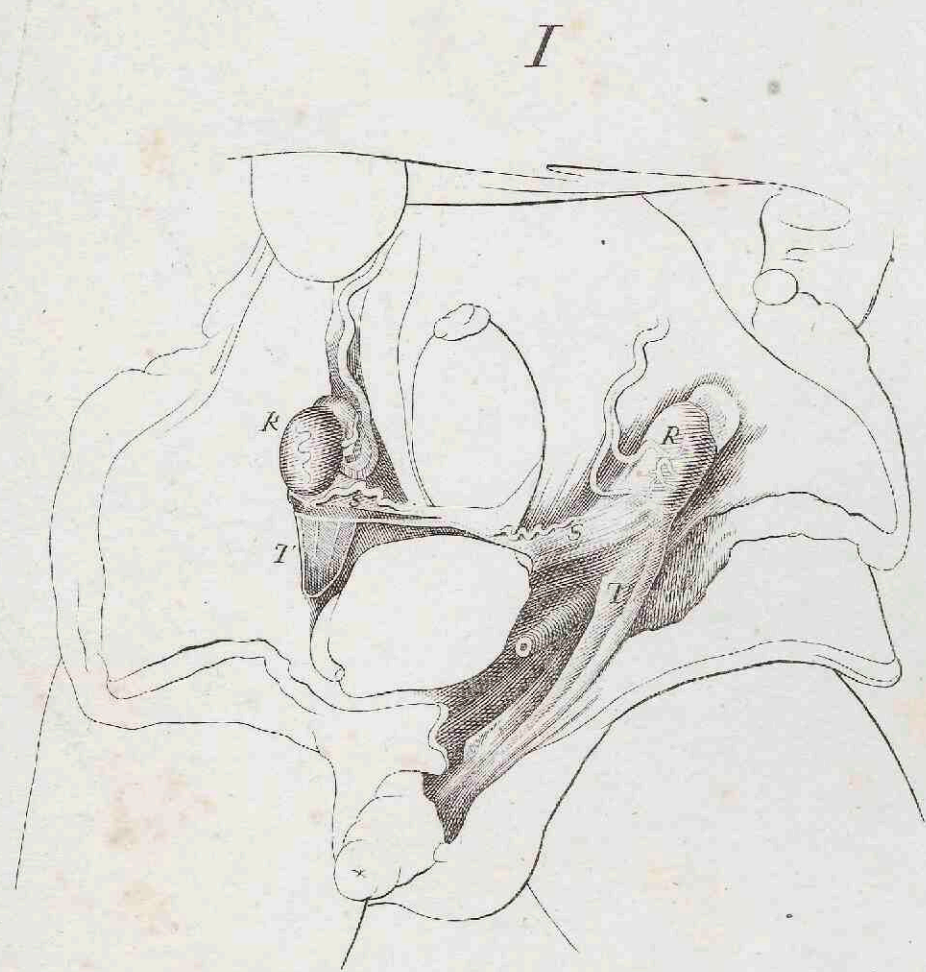


Längendurchschnitt des Unterleibs eines kaum jährigen Kindes: 1. das Bauchfell an der vorderen Wand, 2. wie es die convexe Leberfläche umkleidet, 3. an der concaven Leberfläche, 4. wie es das vordere Blatt des kleinen Netzes bildet, 5. die vordere Fläche des Magens überzieht, 6. als vorderes Blatt des großen Netzes, 7. wie es die untere Seite des Quergründarms als dessen äußerste Haut überkleidet, 8. als unteres Blatt des Gefäßes für den Quergründarm, 9. wie es sich in das hier weggesechnittene Foramen Winslowii fortsetzt, 10. wie es den Spiegel-schen Lappen überzieht, 11. das hintere Blatt des kleinen Netzes bildet, 12. die hintere Fläche des Magens überzieht, 13. das hintere Blatt des großen Netzes bildet, 14. die obere Fläche des Quergründarms überzieht, 15. das obere Blatt des Gefäßes für den Quergründarm bildet, und 16. sich vor der Bauchspeicheldrüse in die Höhe schiebt.

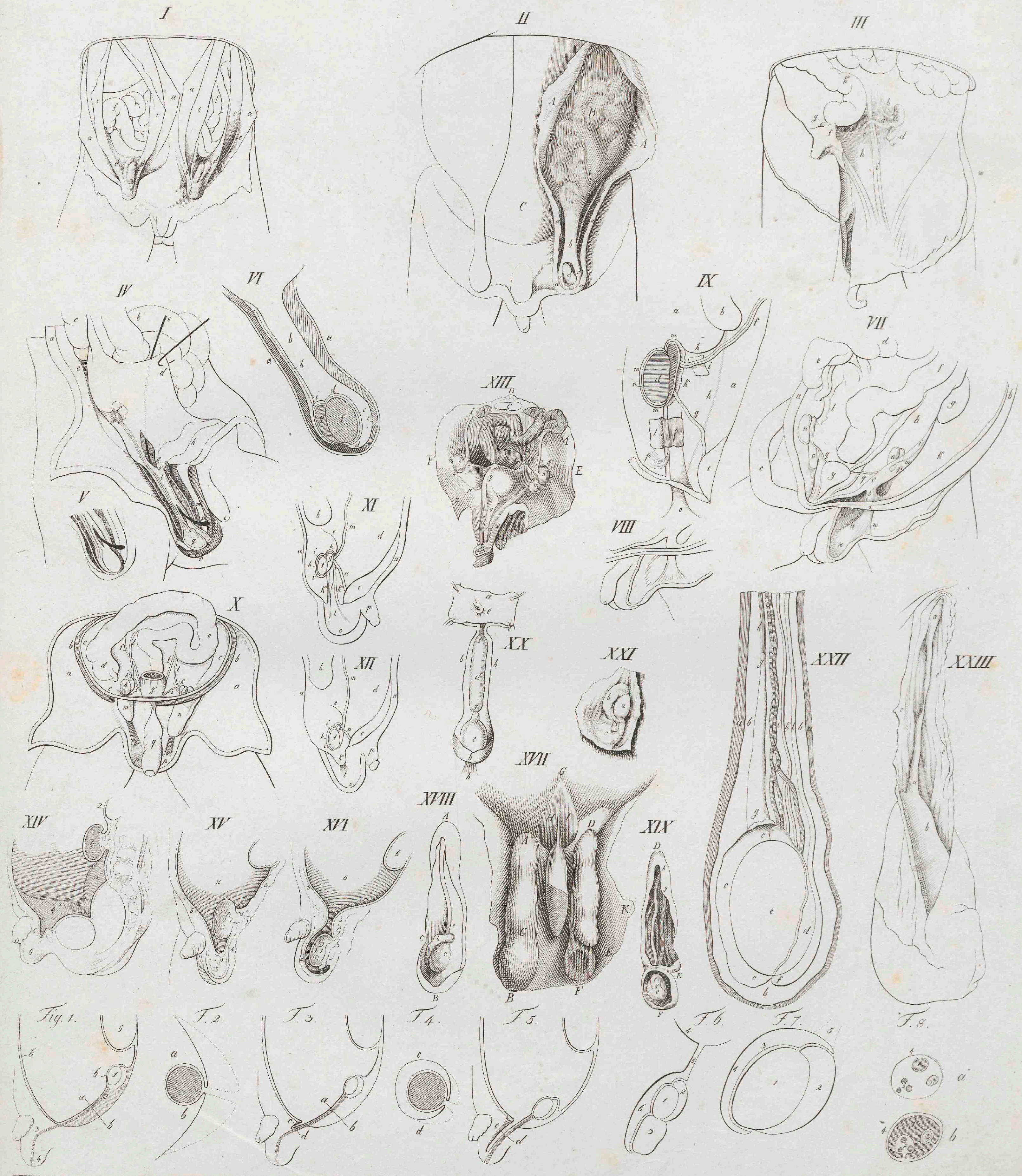Die Zahlen 10. 11. umschließen den Omentalsack, der bei mit der übrigen Peritonäalhöhle communicirt. — Wenn bei Erwachsenen die Flächen 12, 13 an einander geklebt sind, so ist zuwege gebracht, daß der vor dem Colon herabhängende Theil des großen Netzes aus vier Blättern besteht, die hier durch 6, 13, 13, 6, bezeichnet sind.



Ortsveraenderung der Hoden.



Ortsveraenderung der Hoden.



OESTERREICHER'S

Anatomische Steinstücke.

Fünfte Abtheilung

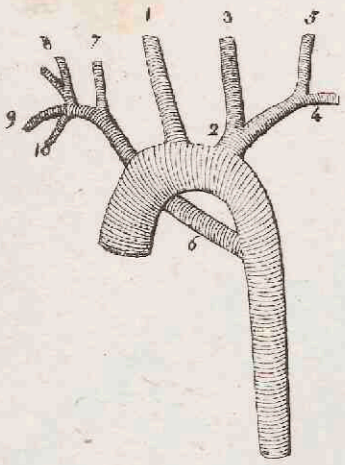
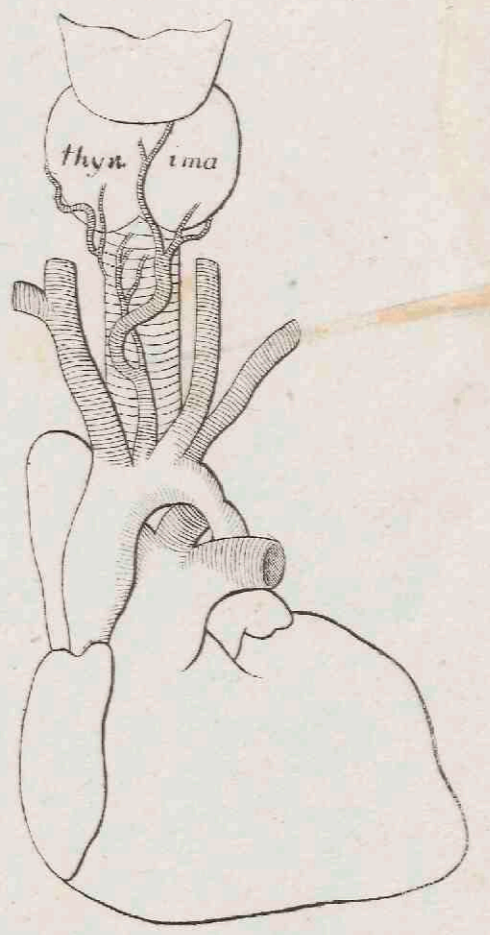
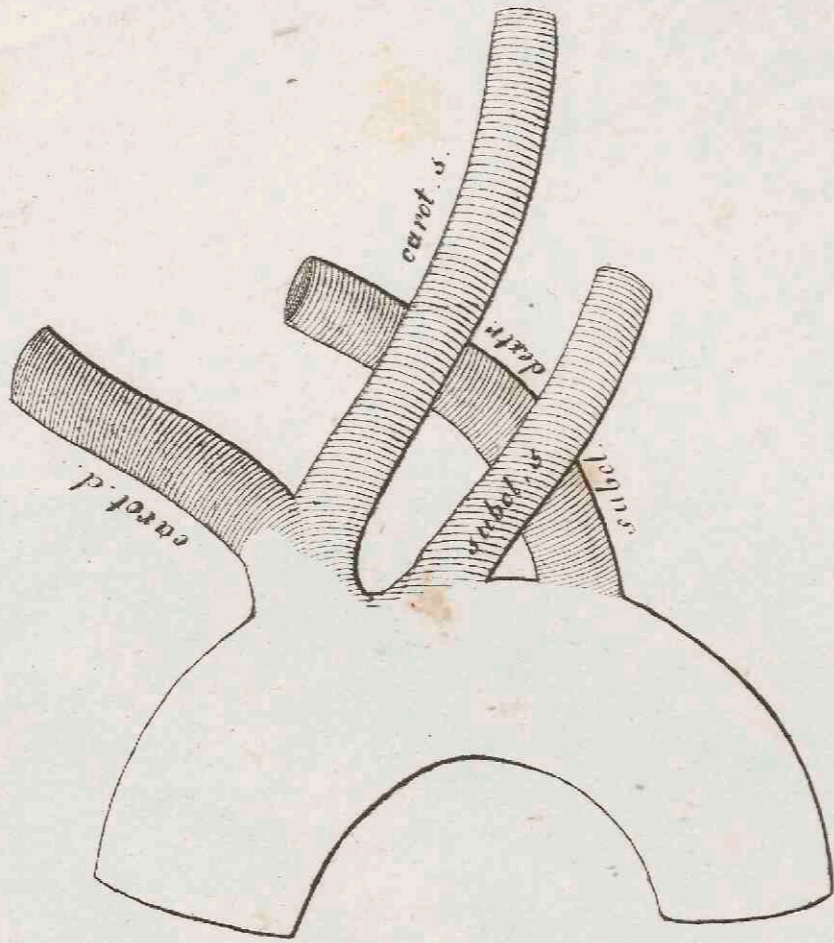
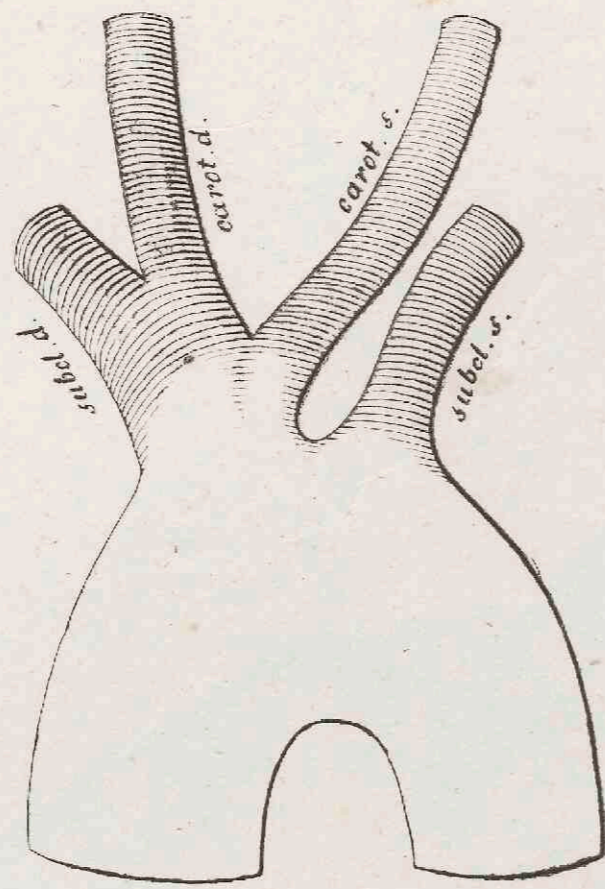
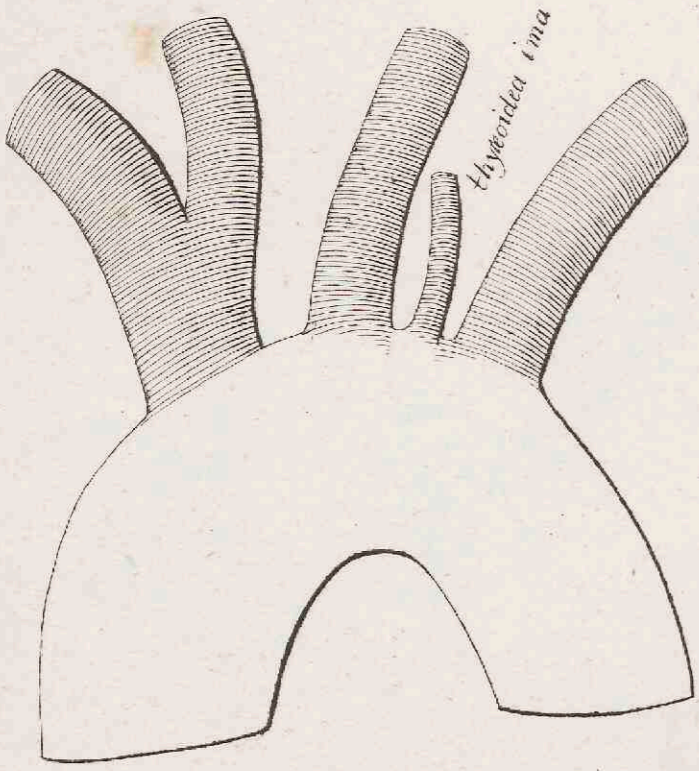
Gefäße
des
Menschlichen Körpers.

München

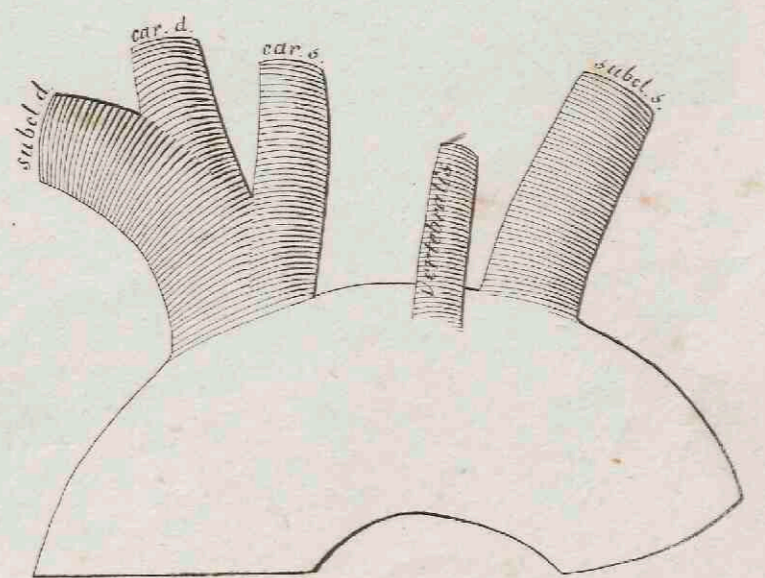
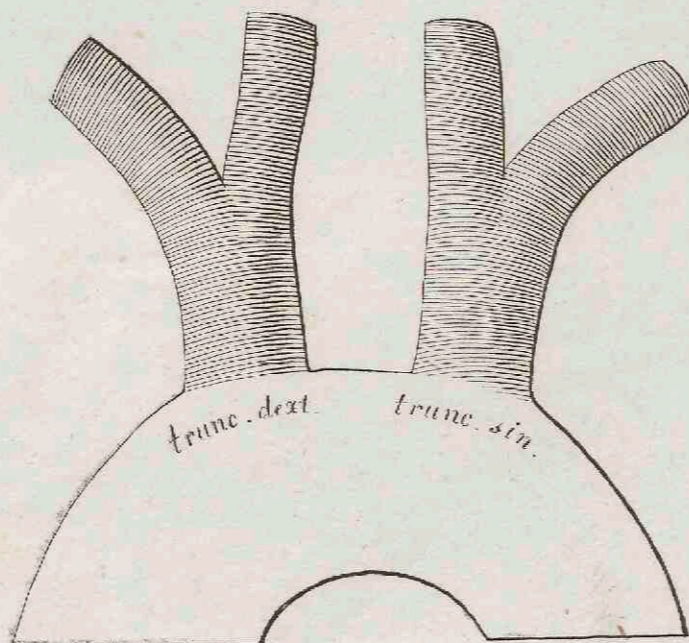

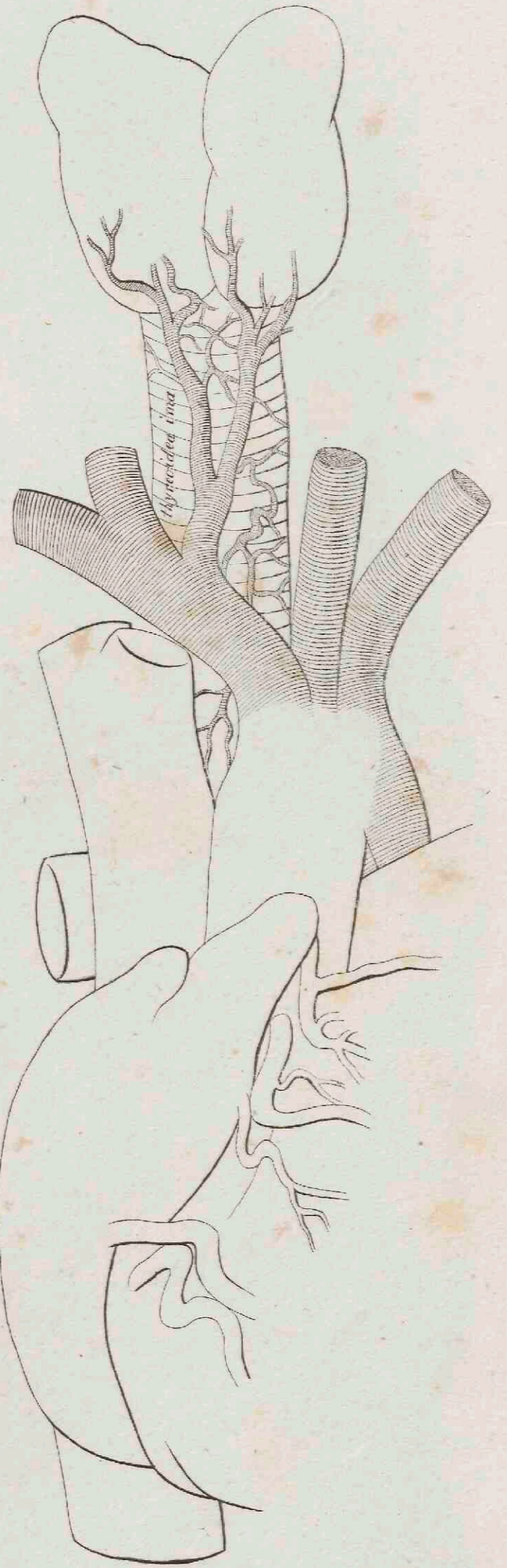
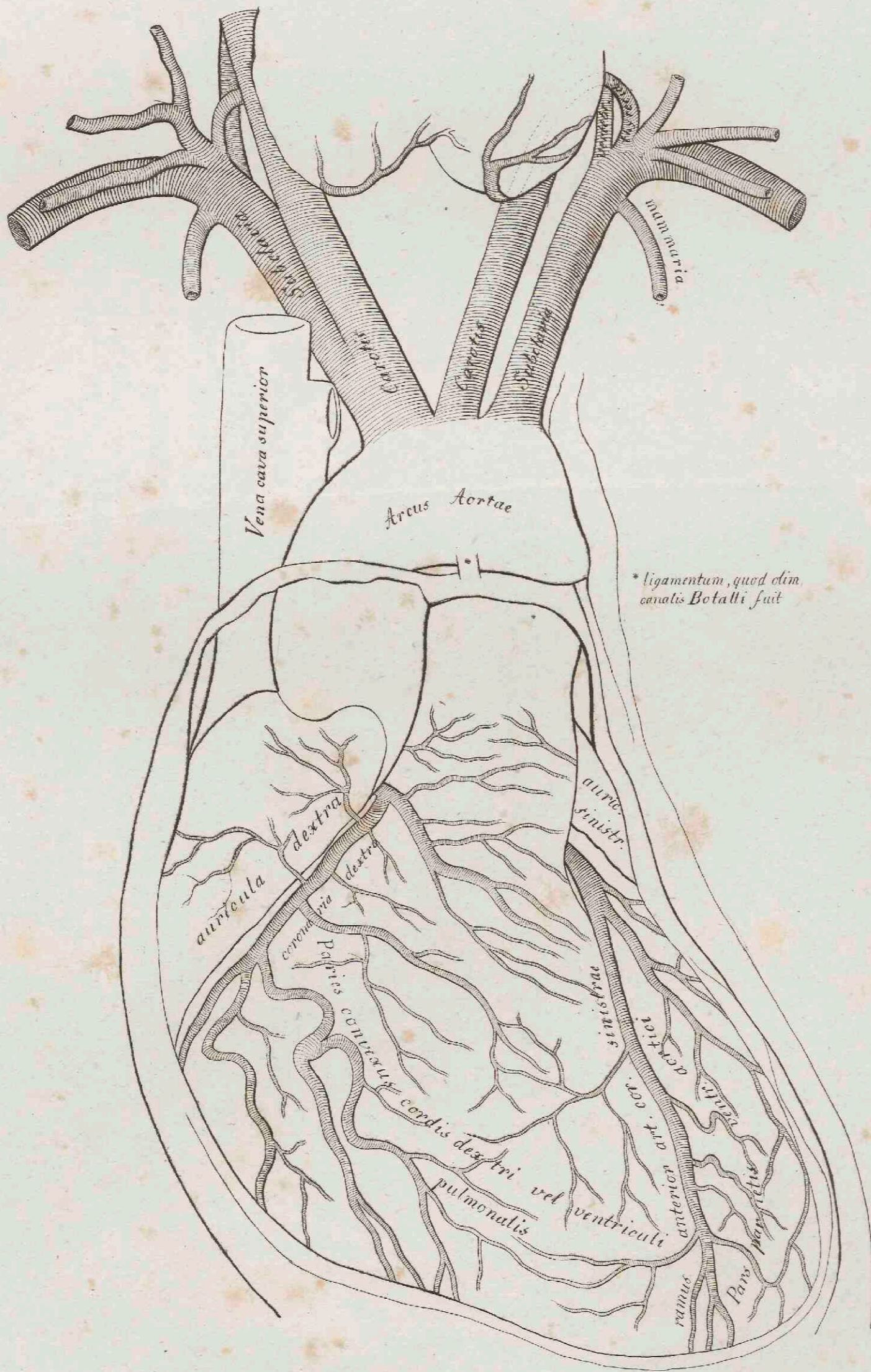
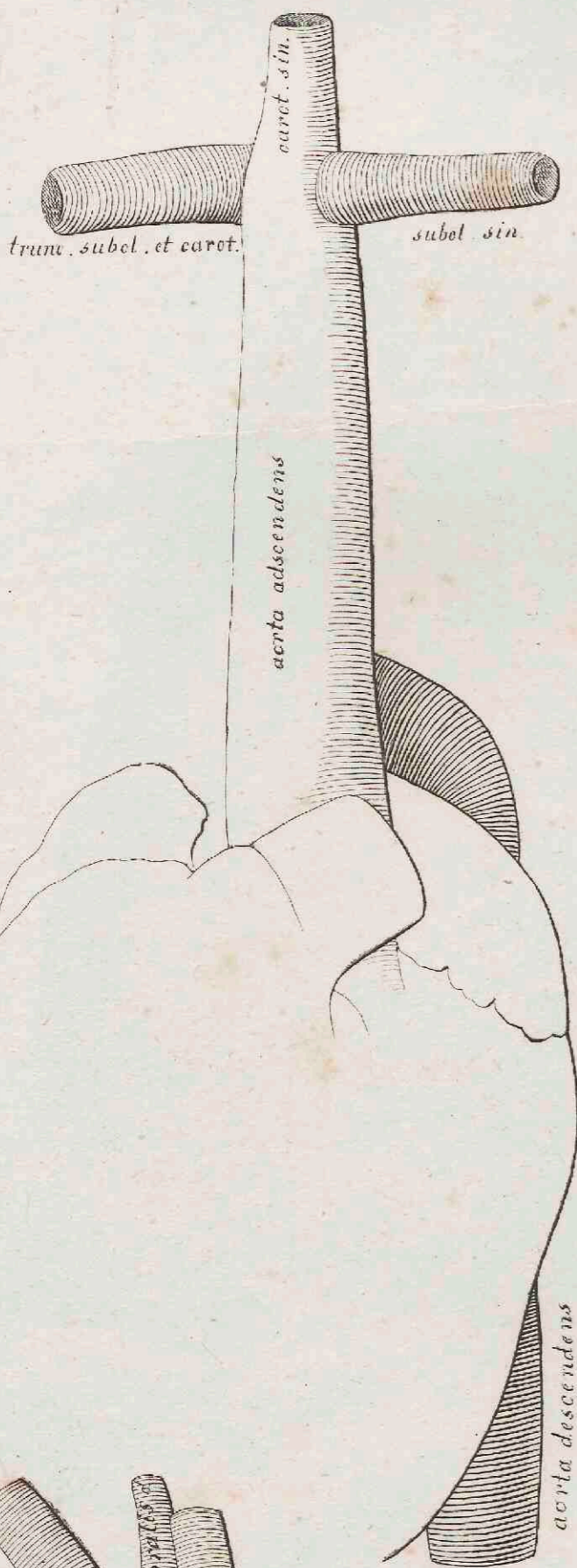
1829

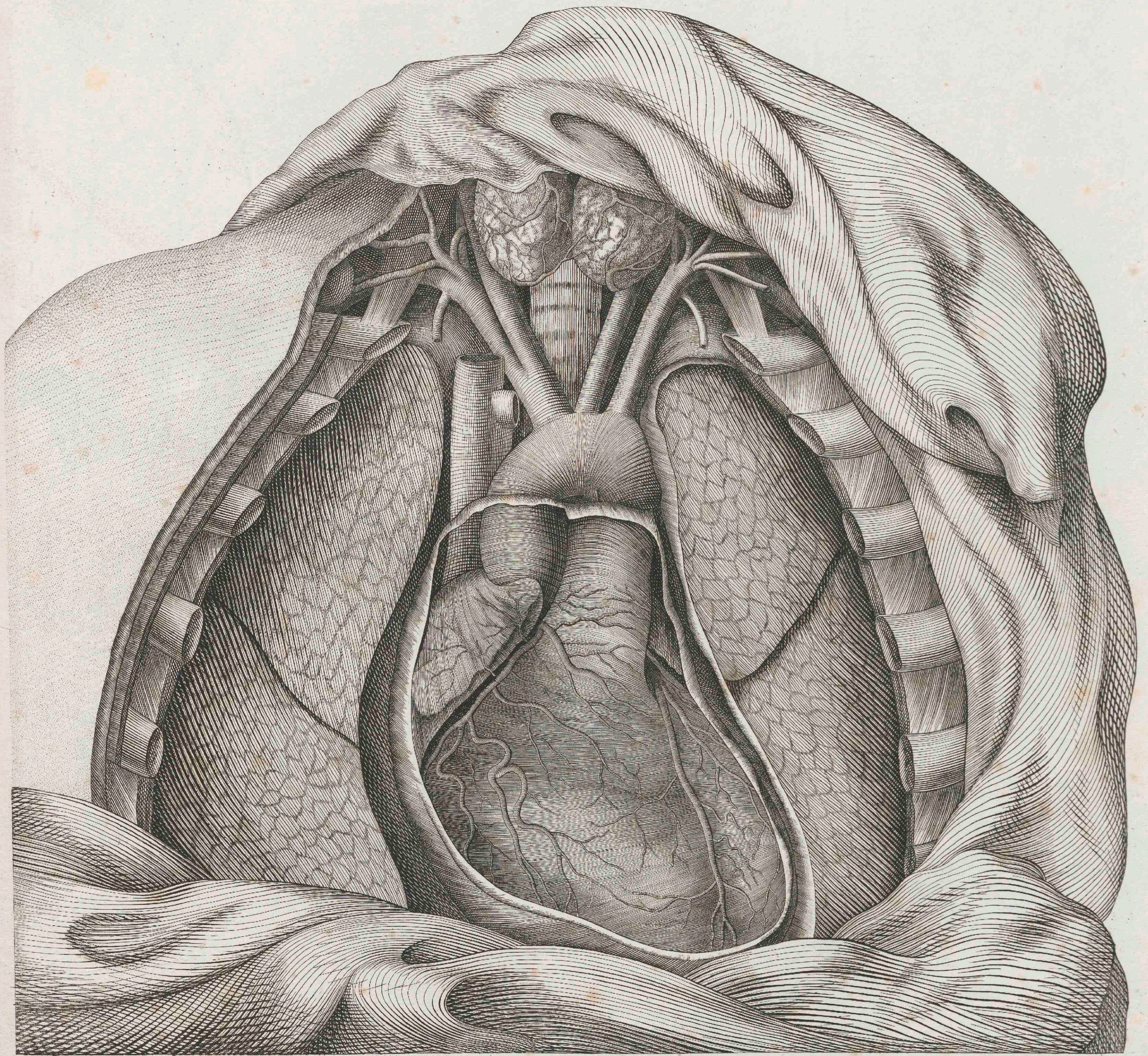
Herz und Arterienstämme

nach Neubauer, Scherer u. Tiedemann.



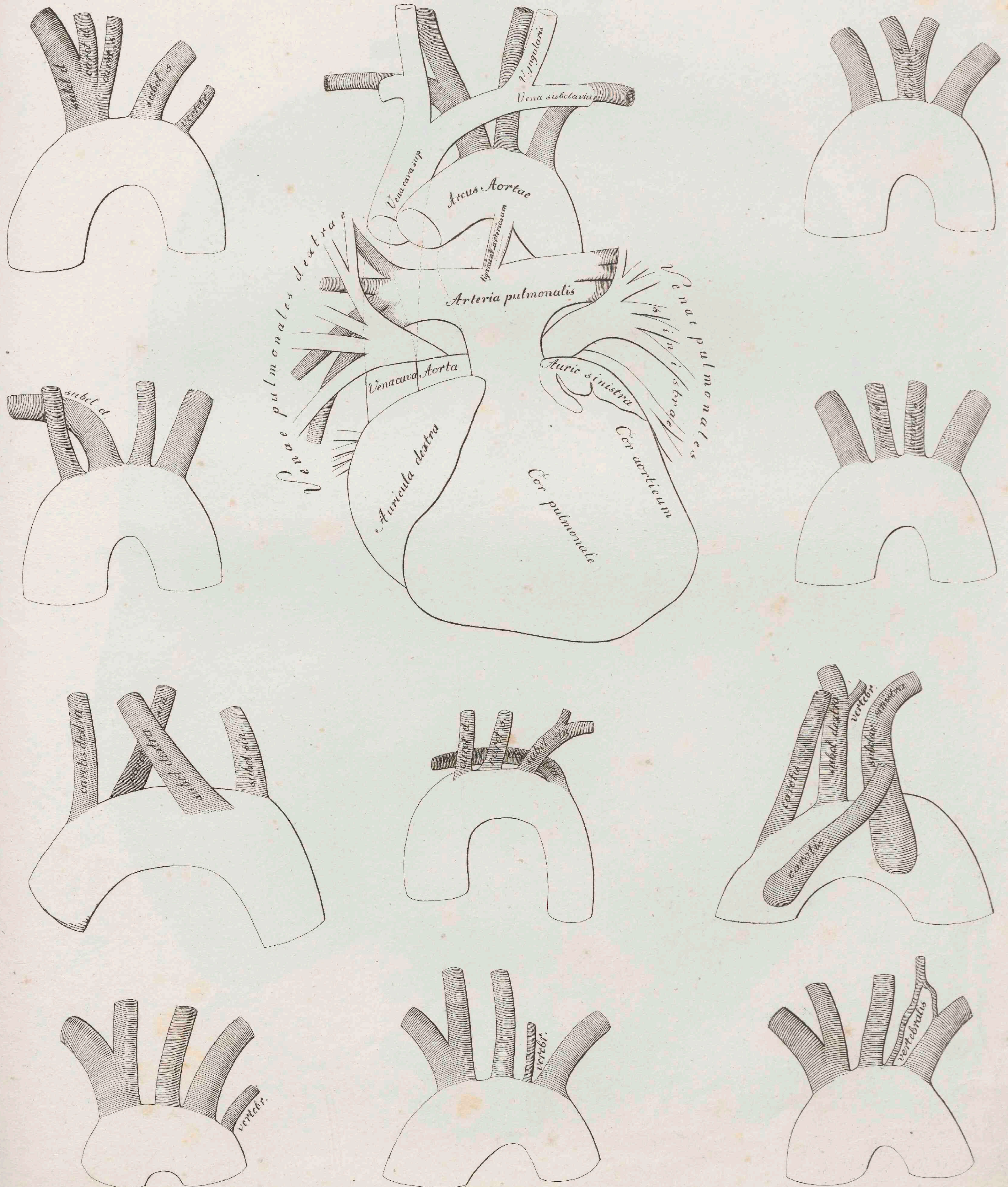
- 1. carotis dextra
- 2. truncus
- 3. carotis sinistra
- 4. subclavia sin.
- 5. vertebralis s.
- 6. subclavia dextra
- 7. vertebralis d.
- 8. thyroidea ima
- 9. transversa colli
- 10. mammae

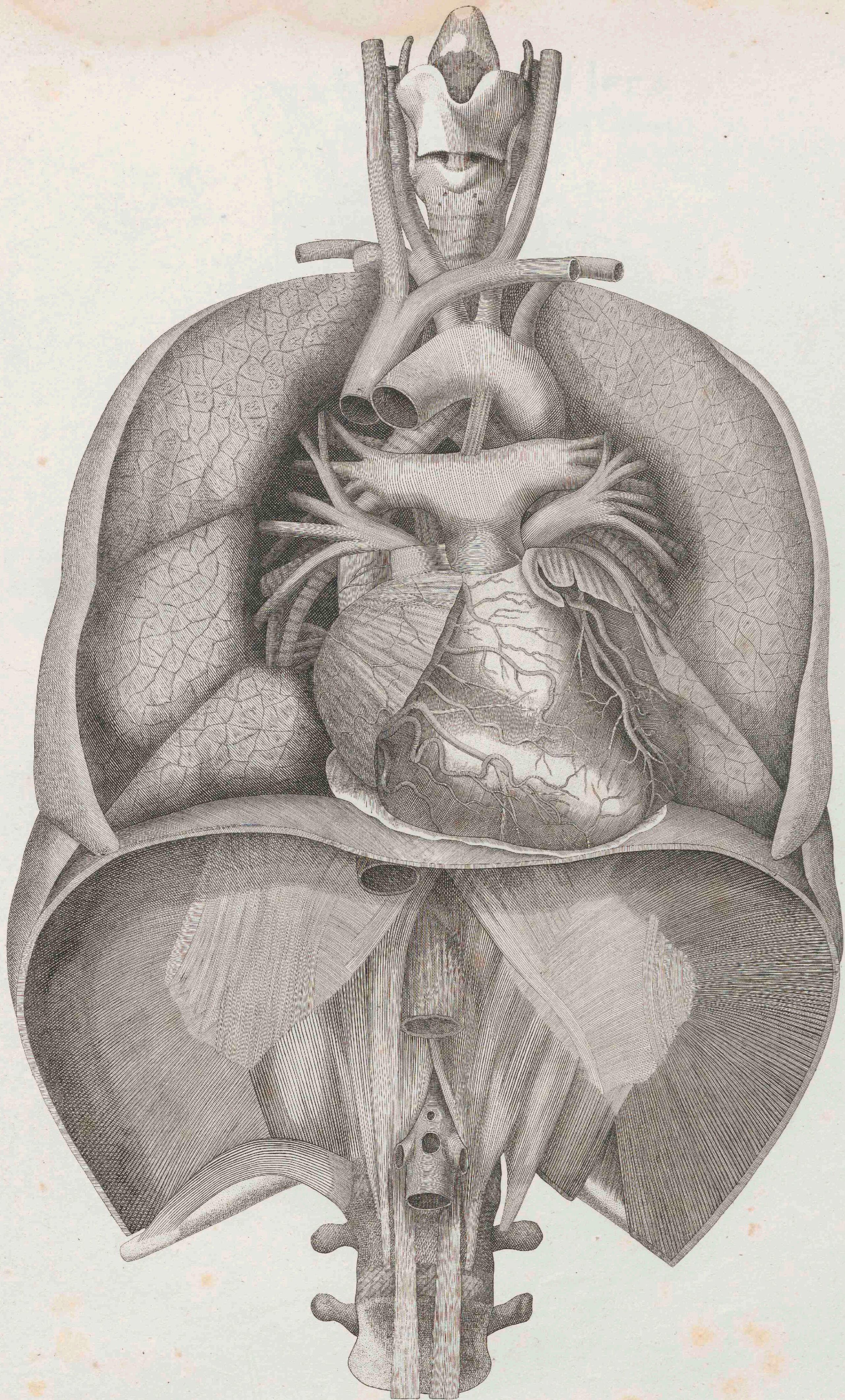




Herz und Arterienstaemme



nach Scherer u. Tiedemann.

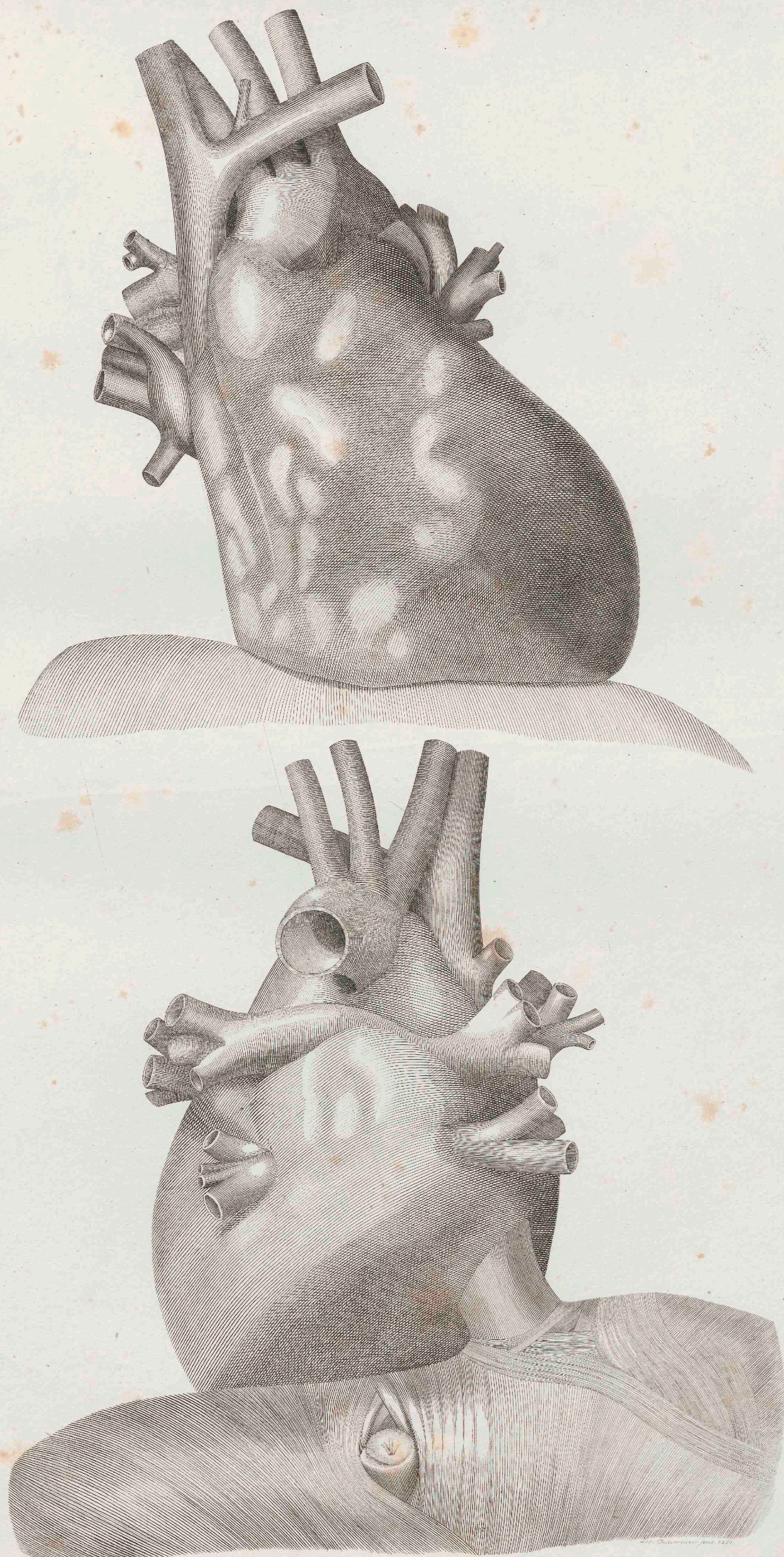



Herz

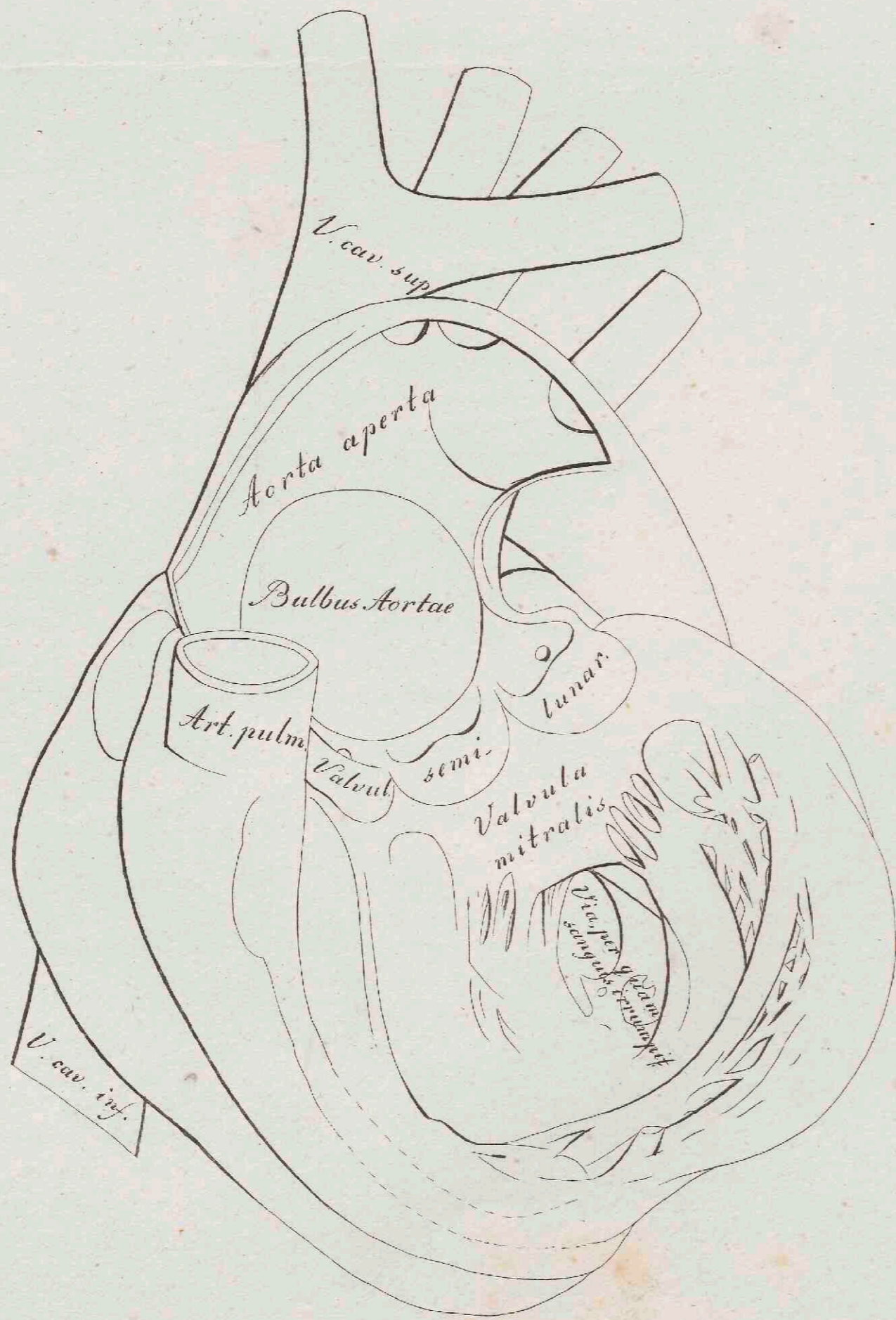
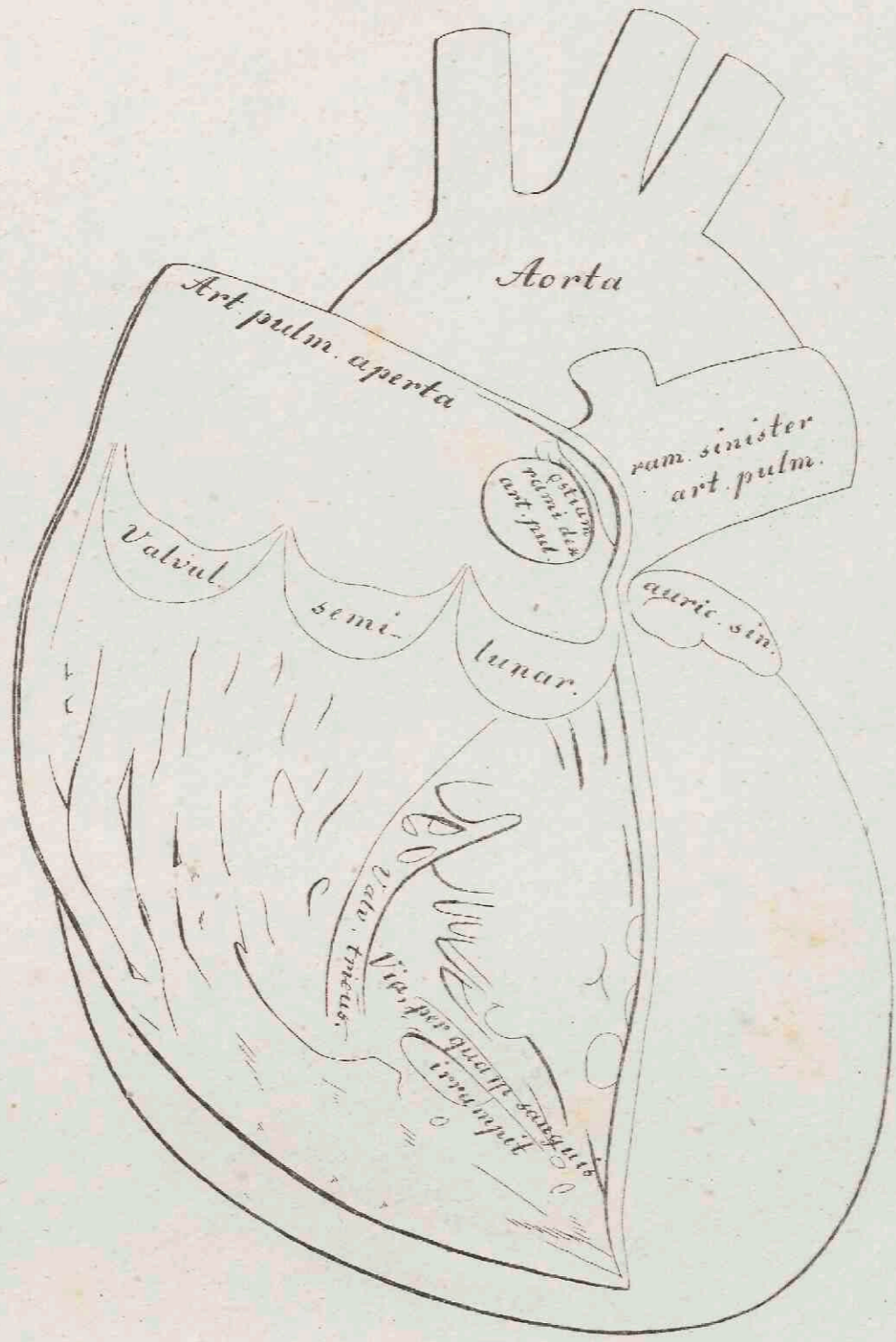
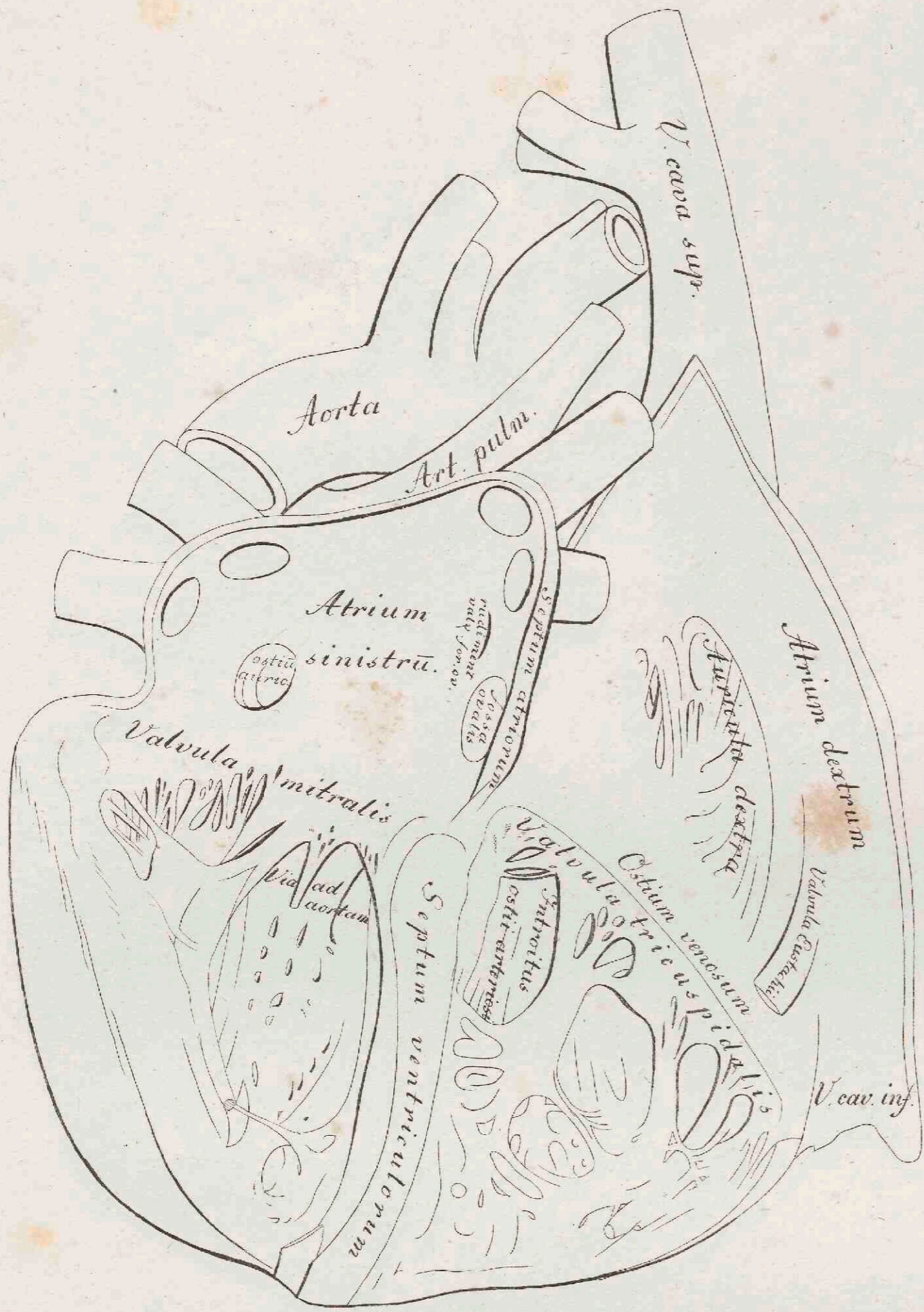
nach Caldani.

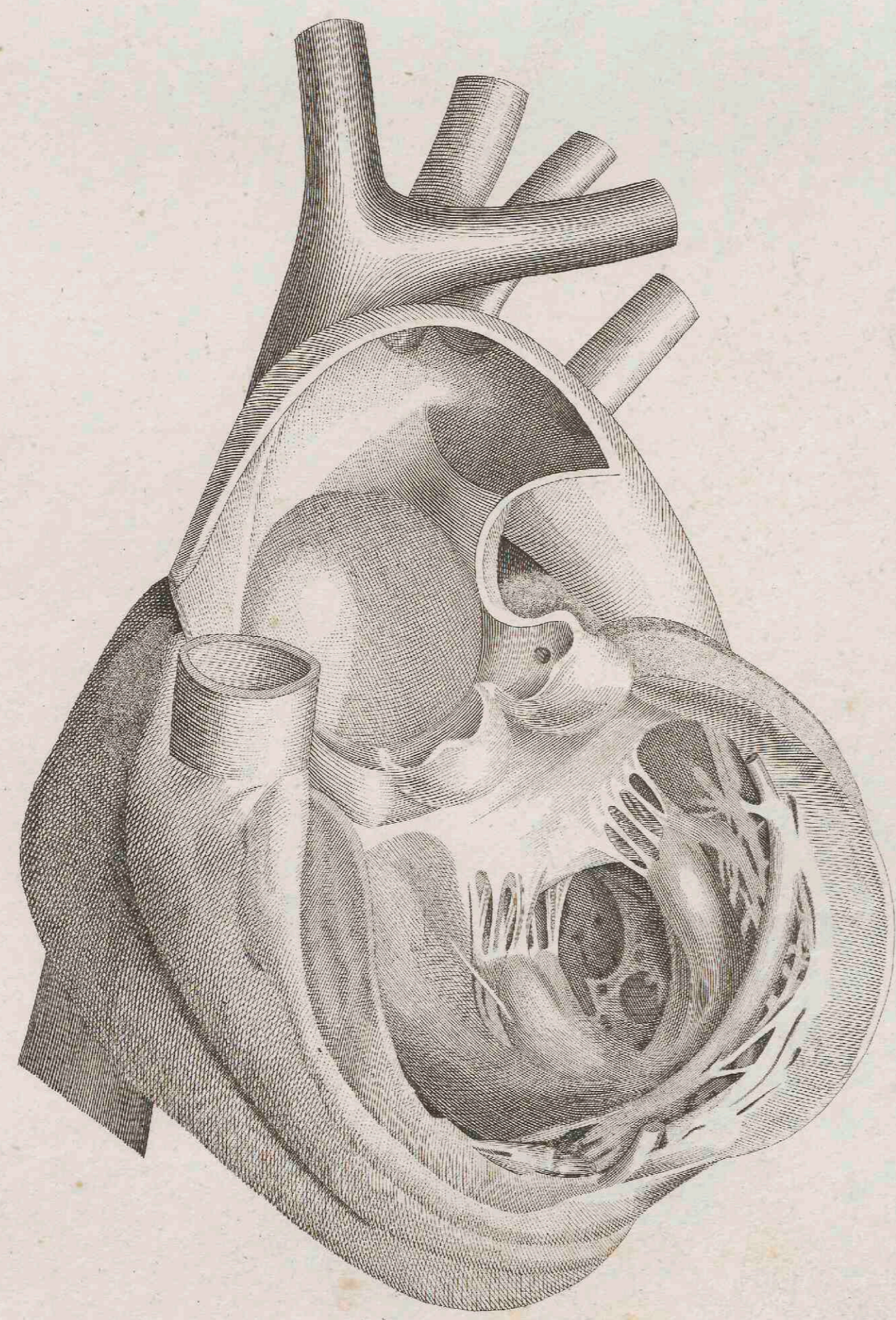
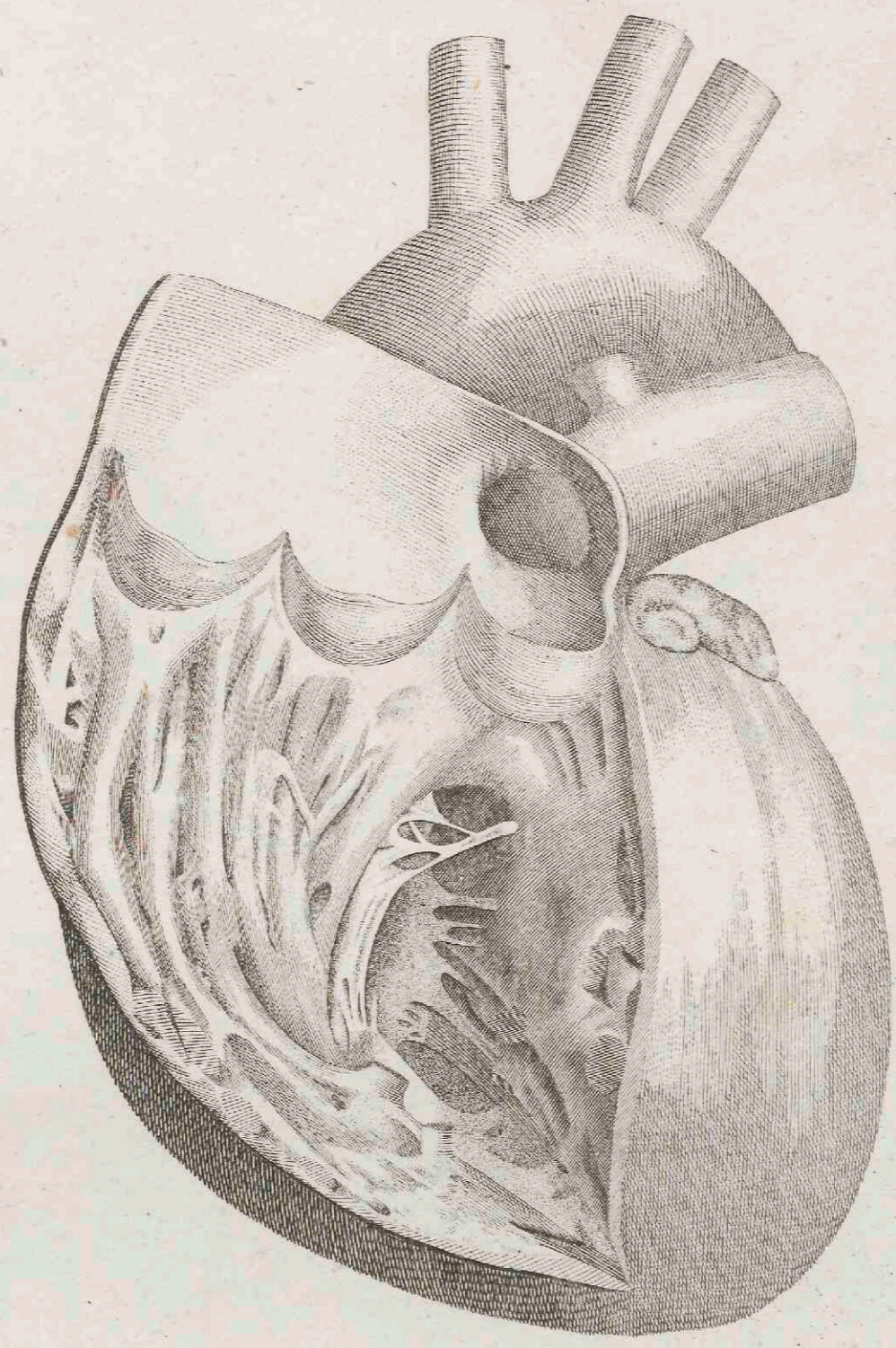
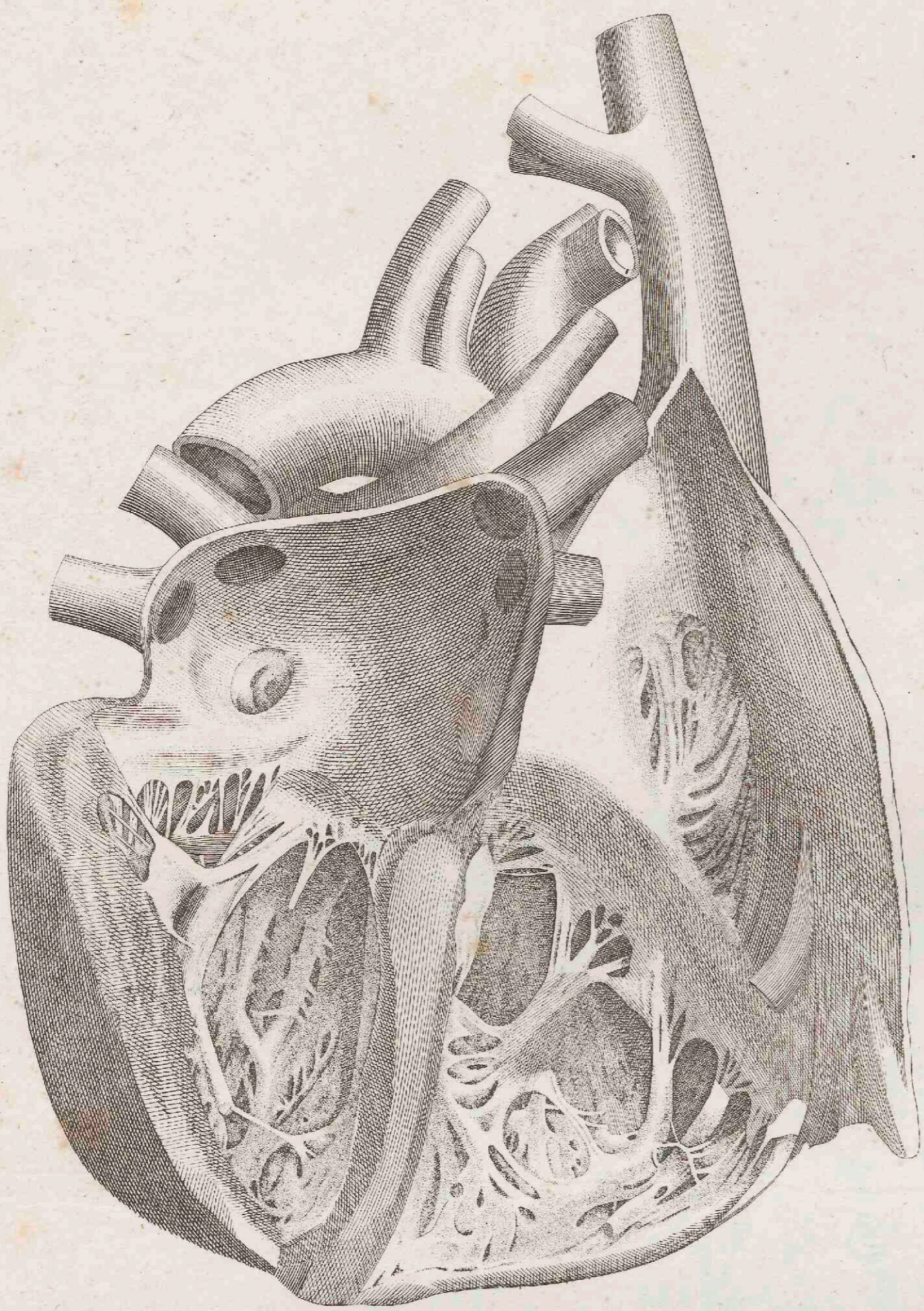




Innerer Bau des Herzens.

nach Caldani.





Pulsadern des Kopfes.

umgearbeitet nach Tiedemann.

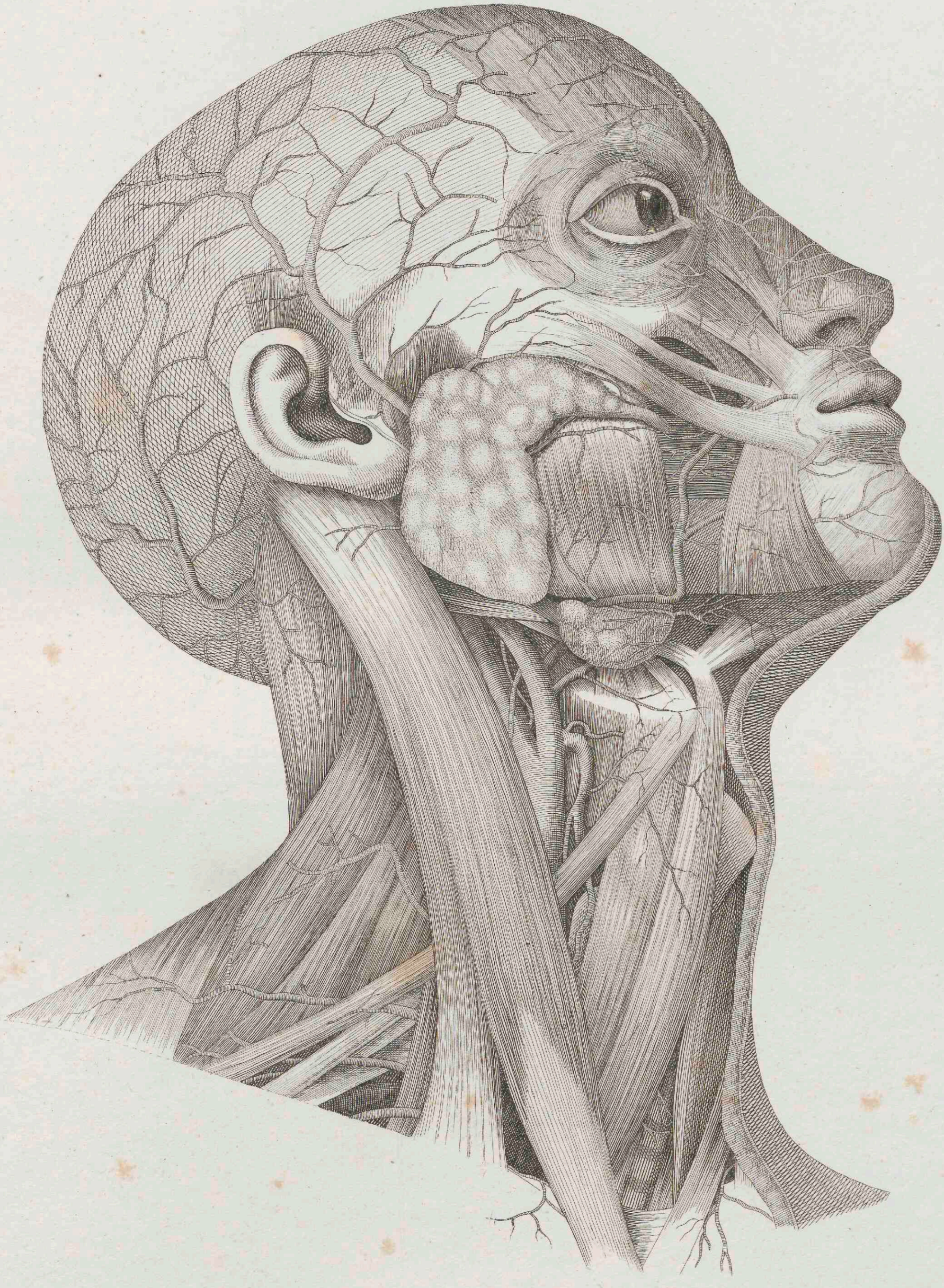


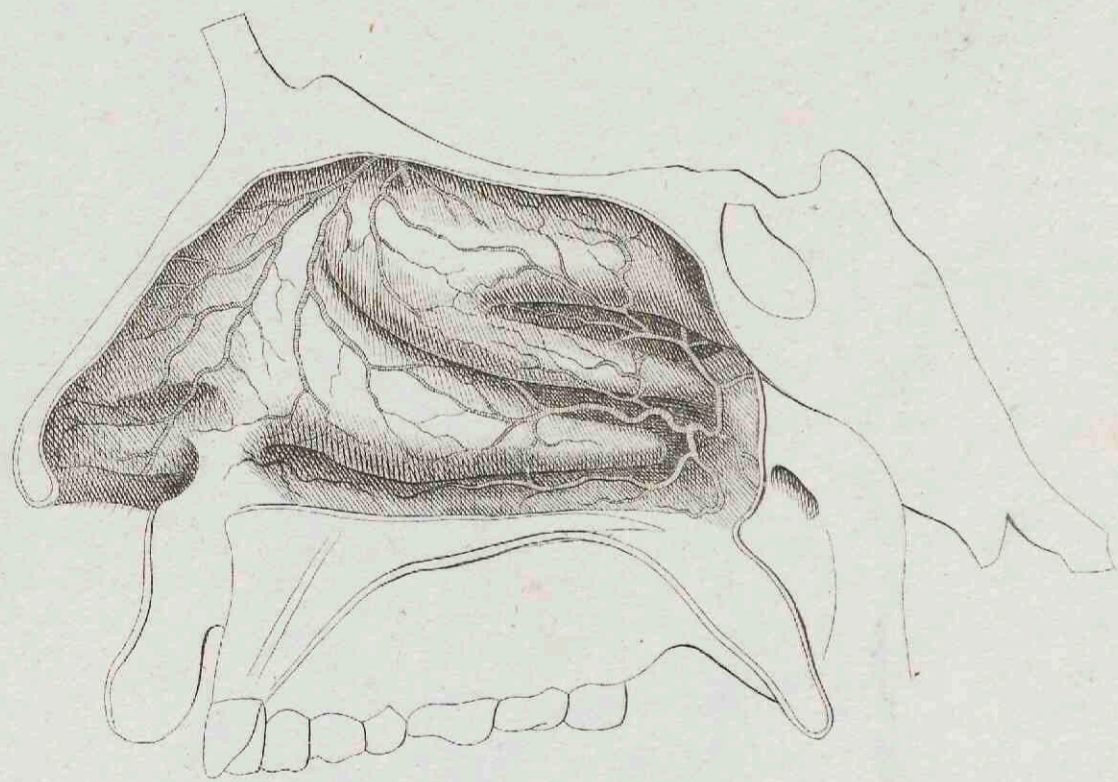
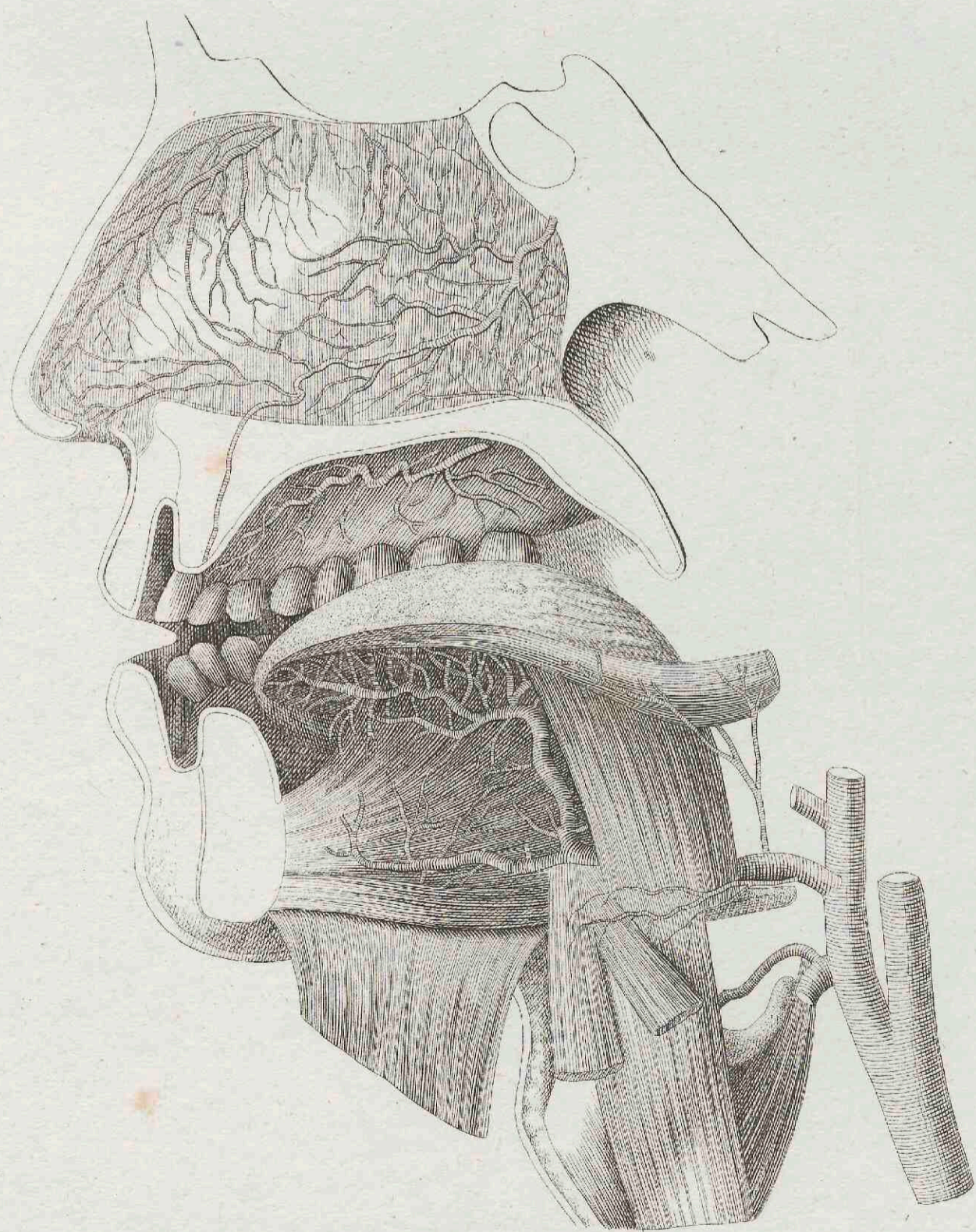
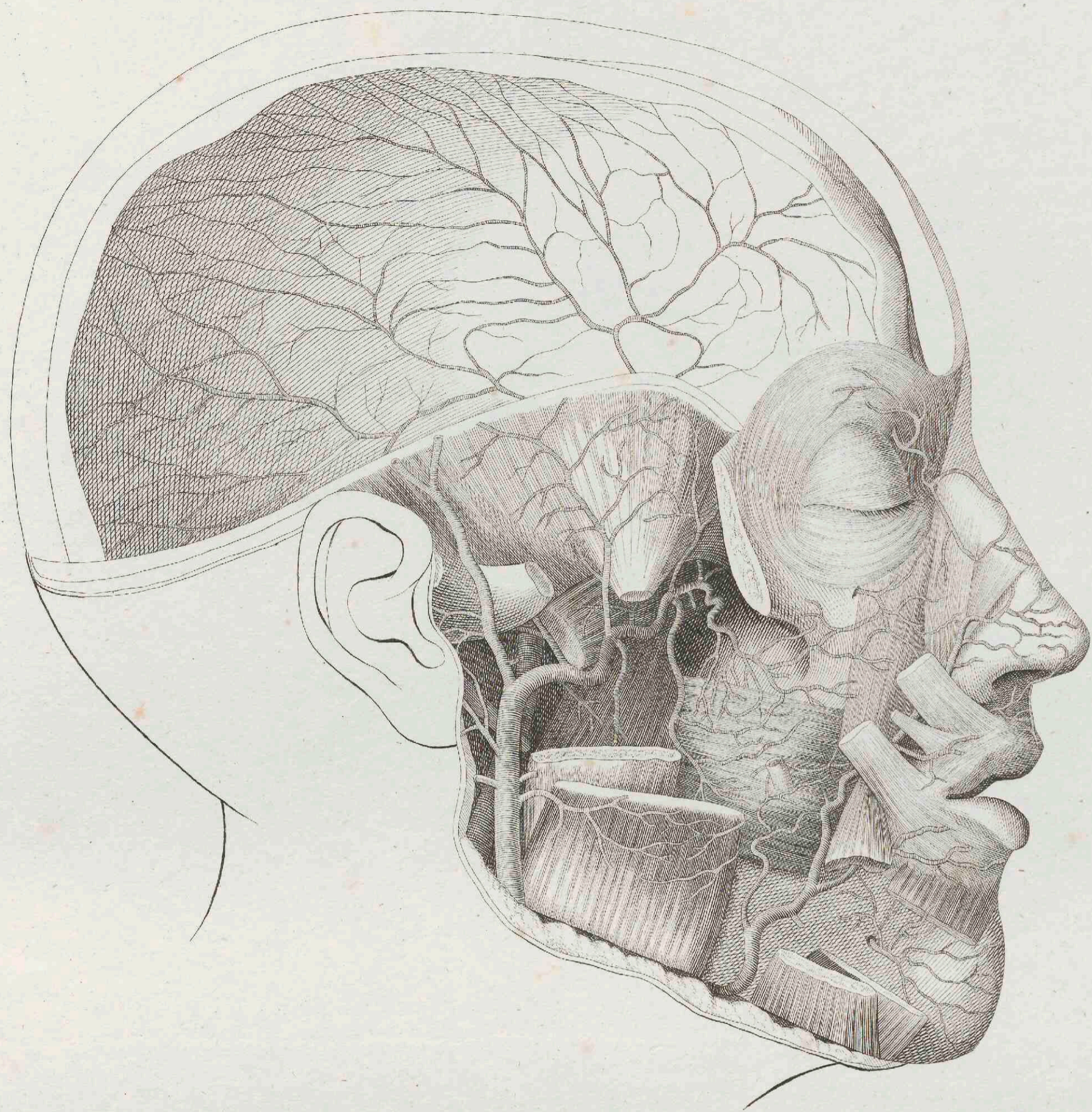
CAROTIS COMMUNIS, I

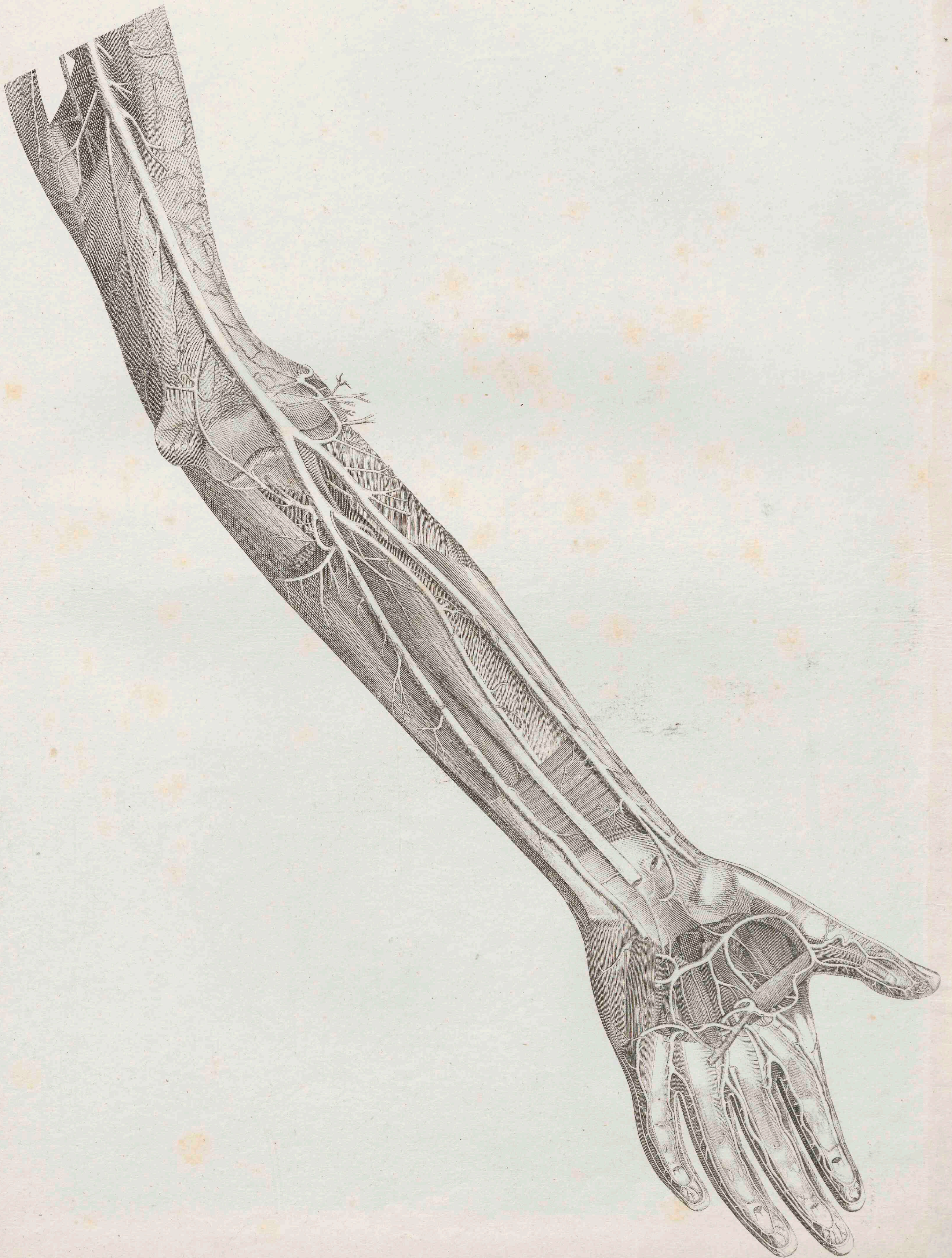
2. carotis externa

3. ——— interna

- | | |
|---------------------------|---------------------------------------|
| 4. thyreoidea superior | 5. Ramus laryngeus |
| 6. lingualis | 7. dorsalis linguae |
| | 8. sublingualis |
| | 9. profunda s. ranina |
| 10. maxillaris externa | 11. palatina ascendens |
| | 12. rami glandulares |
| | 13. submentalis |
| | 14. coronaria labii inferioris |
| | 15. ——— superioris |
| | 16. nasalis septi |
| 17. angularis | |
| 18. pharyngea ascendens | |
| 19. occipitalis | 20. nuchinea postica |
| 21. auricularis posterior | 22. stylomastoidea |
| 23. temporalis | 24. auriculares anteriores inferiores |
| | 25. transversa faciei |
| | 26. temporalis profunda |
| | 27. anterior |
| | 28. posteriores |
| | 29. auricularis anterior superior |
| 30. maxillaris interna | Conf. Tab. 34 |

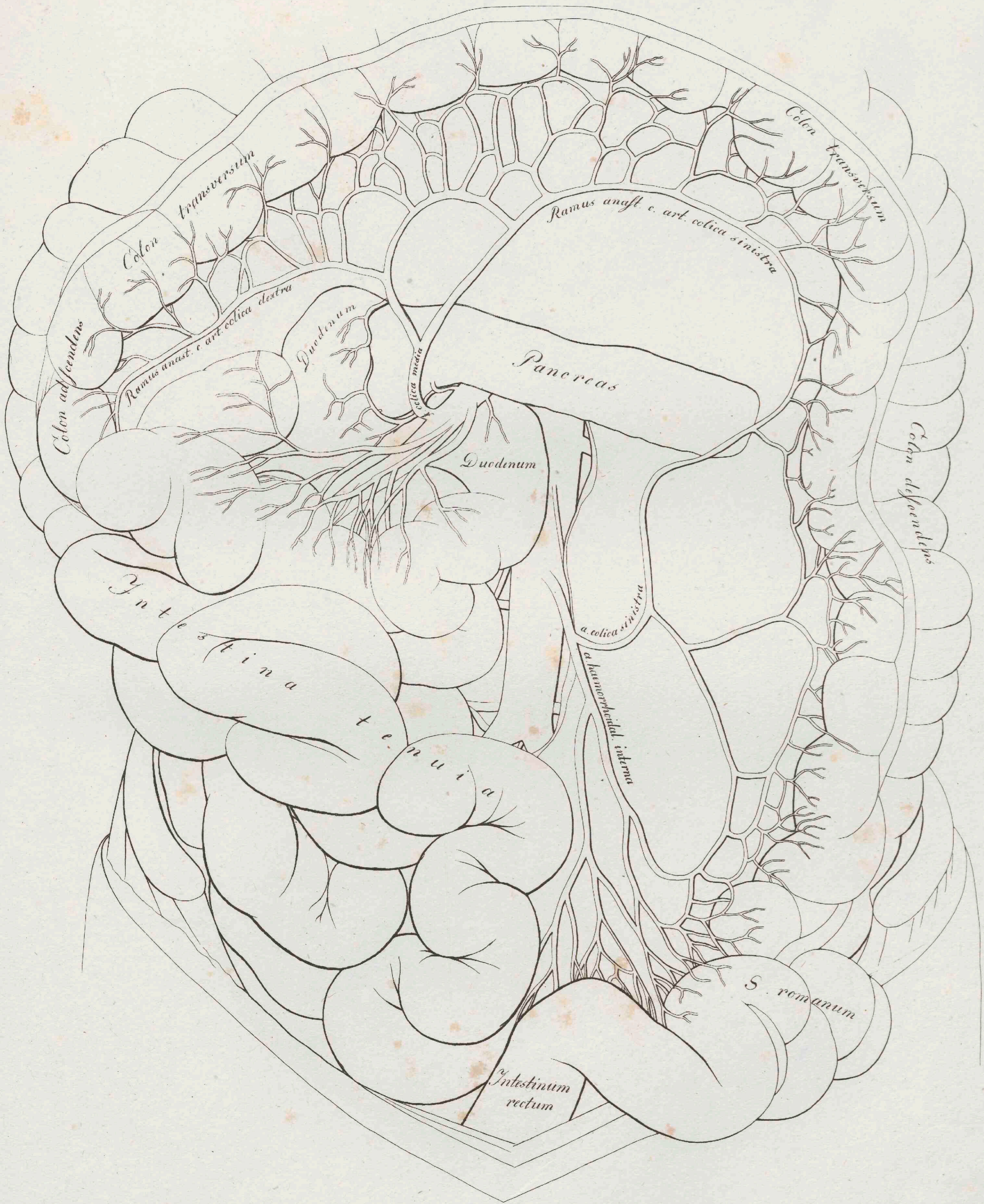



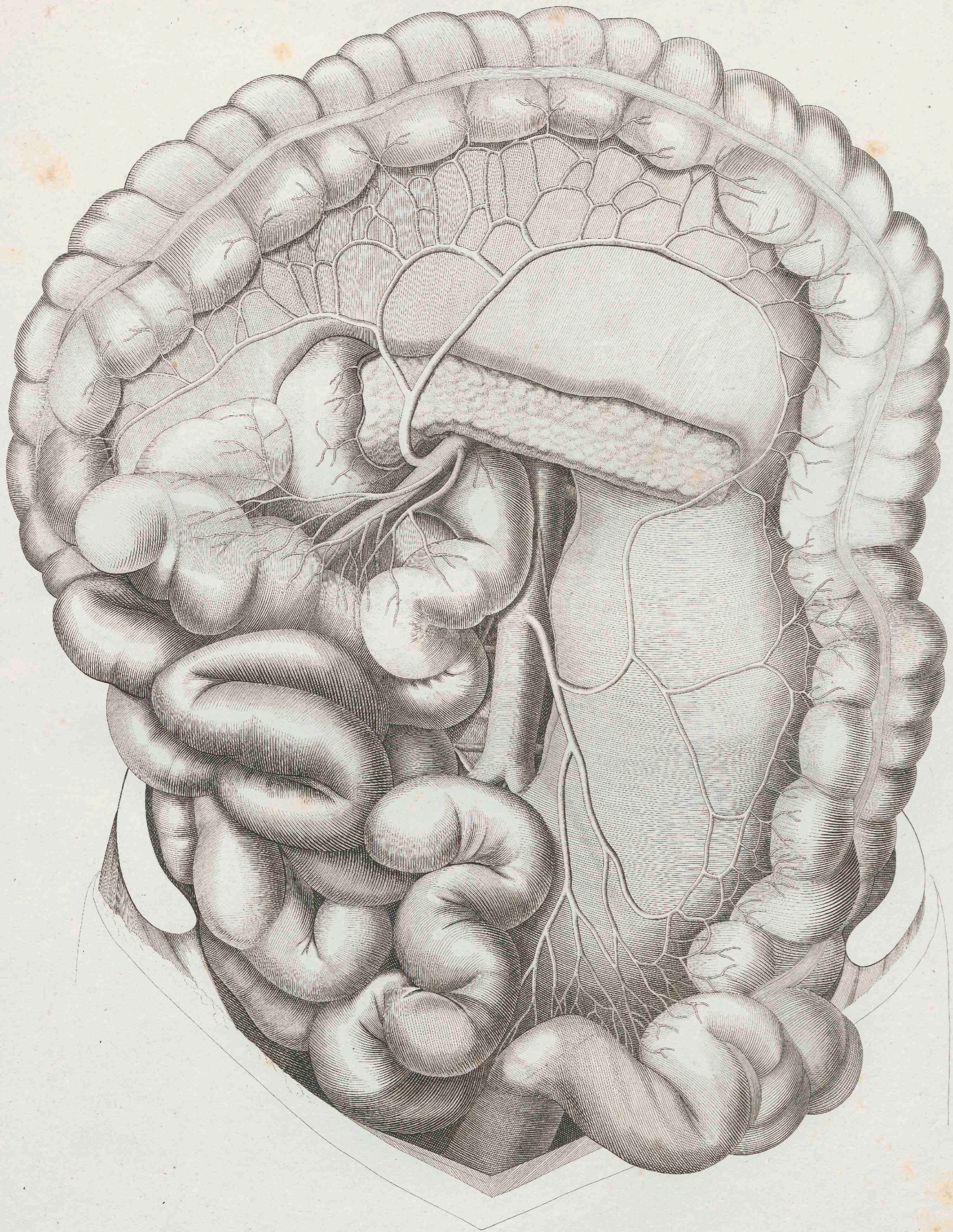


Pulsadern des Darms

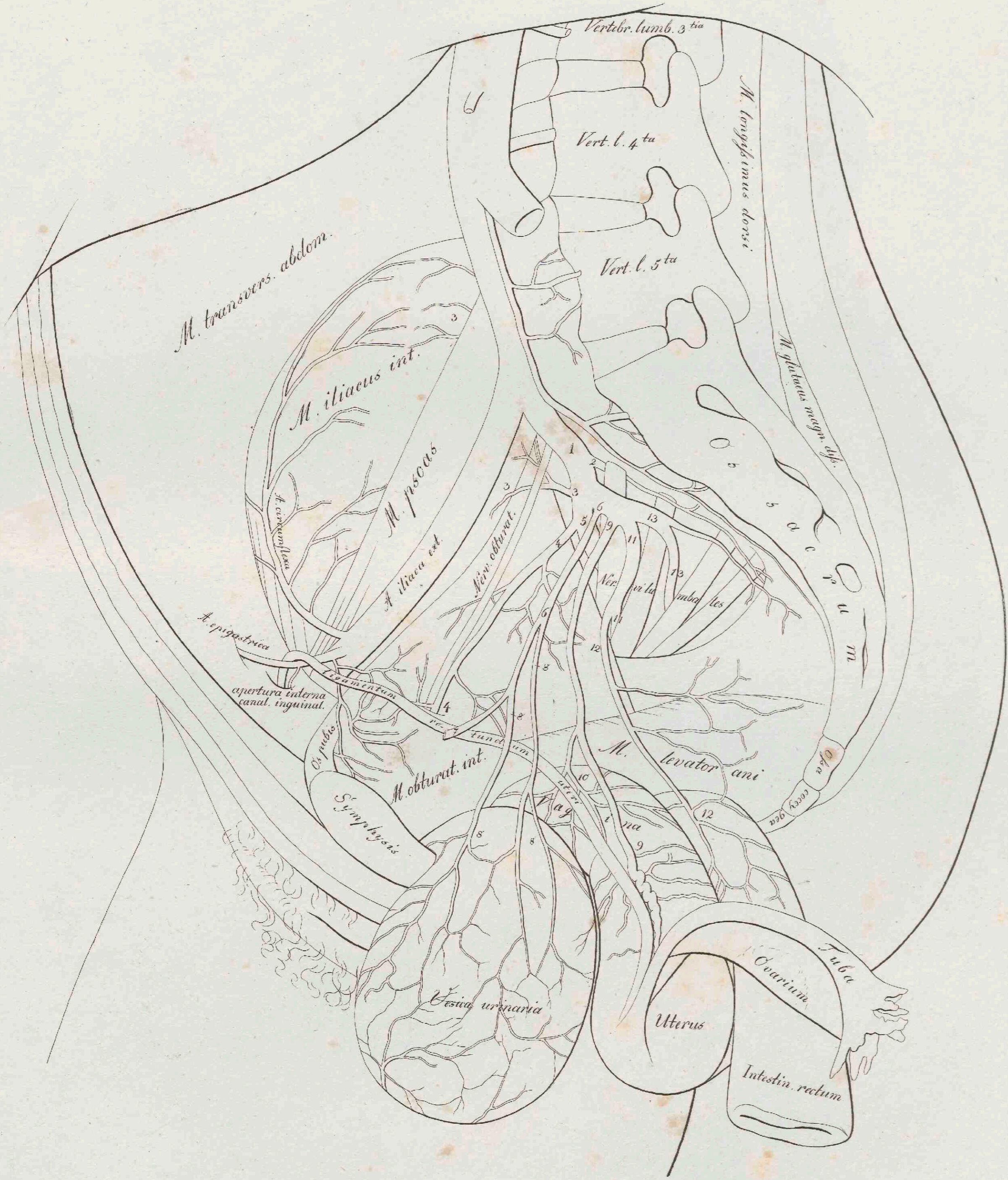umgearbeitet nach Tiedemann.



Arteria mesenterica superior et inferior.

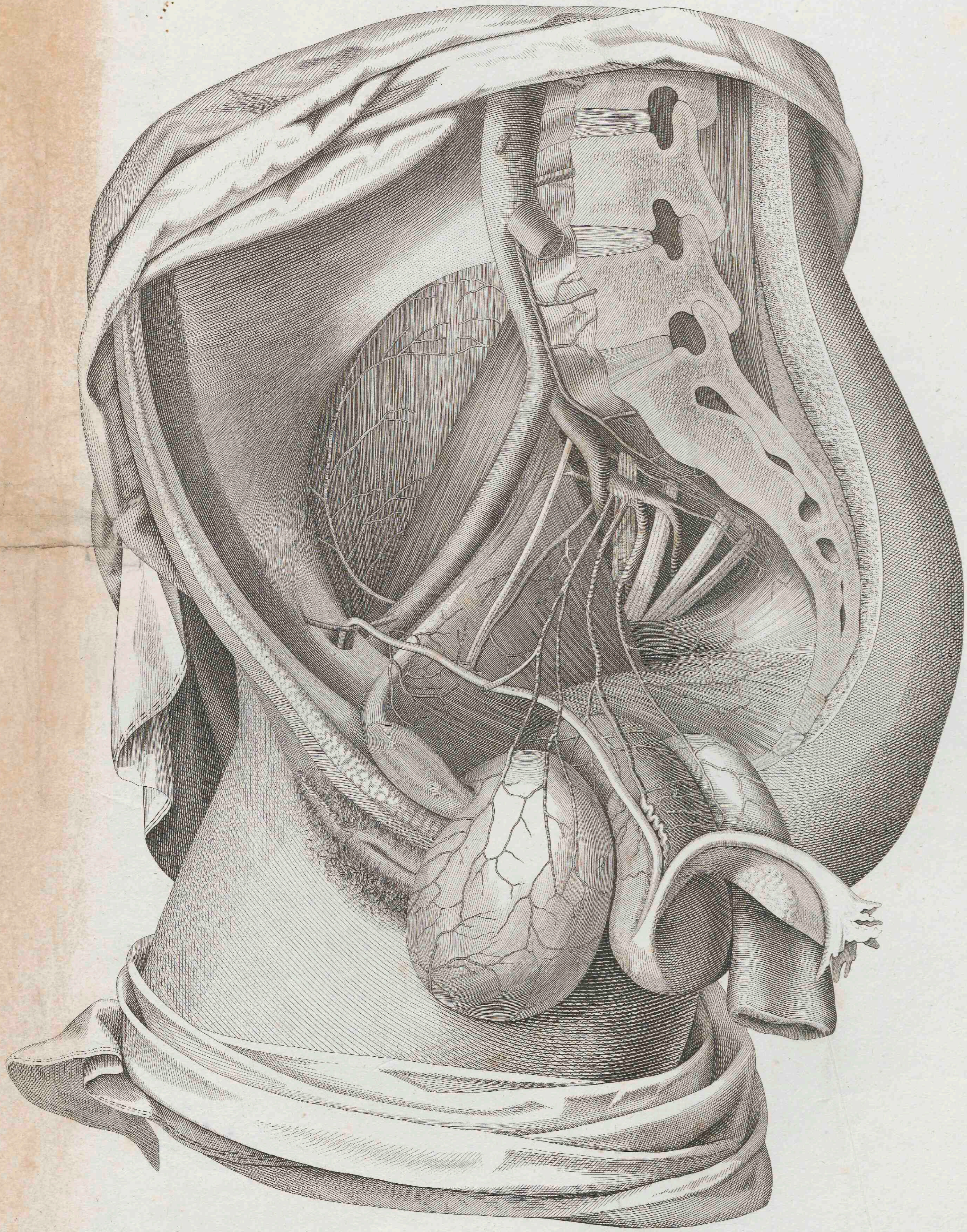


Pulsadern des Beckens, umgearbeitet nach Tiedemann.



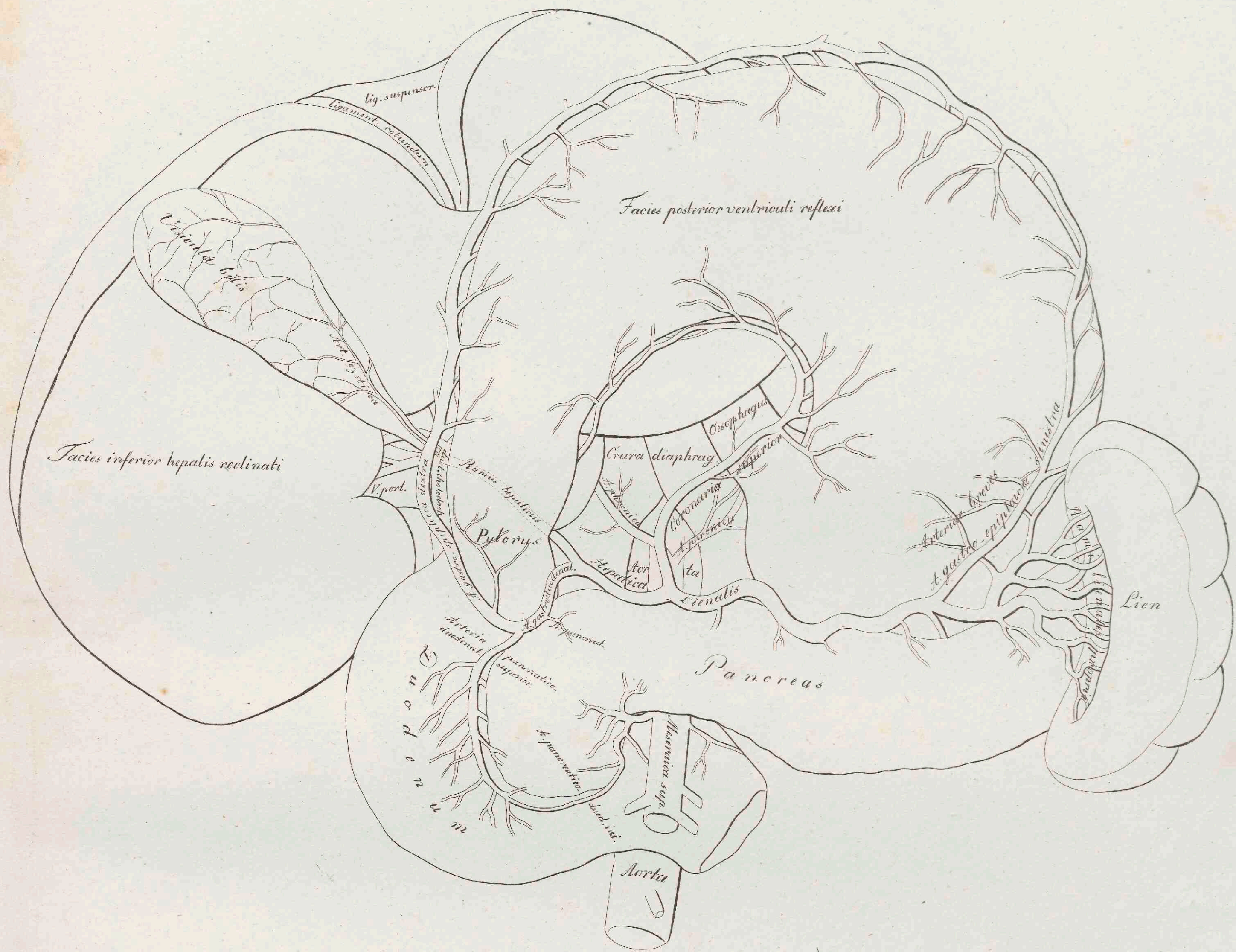
Arteria hypogastrica in femina.

- 2 sacra lateralis
- 3 ileolumbalis
- 4 obturatoria
- 5 glutea
- 6 umbilicalis
- 7 lig. umb. s. a. vesicales
- 8 a. vesicales
- 9 uterina
- 10 vaginalis
- 11 pudenda communis
- 12 haemorrhoidalis media
- 13 ischiadica

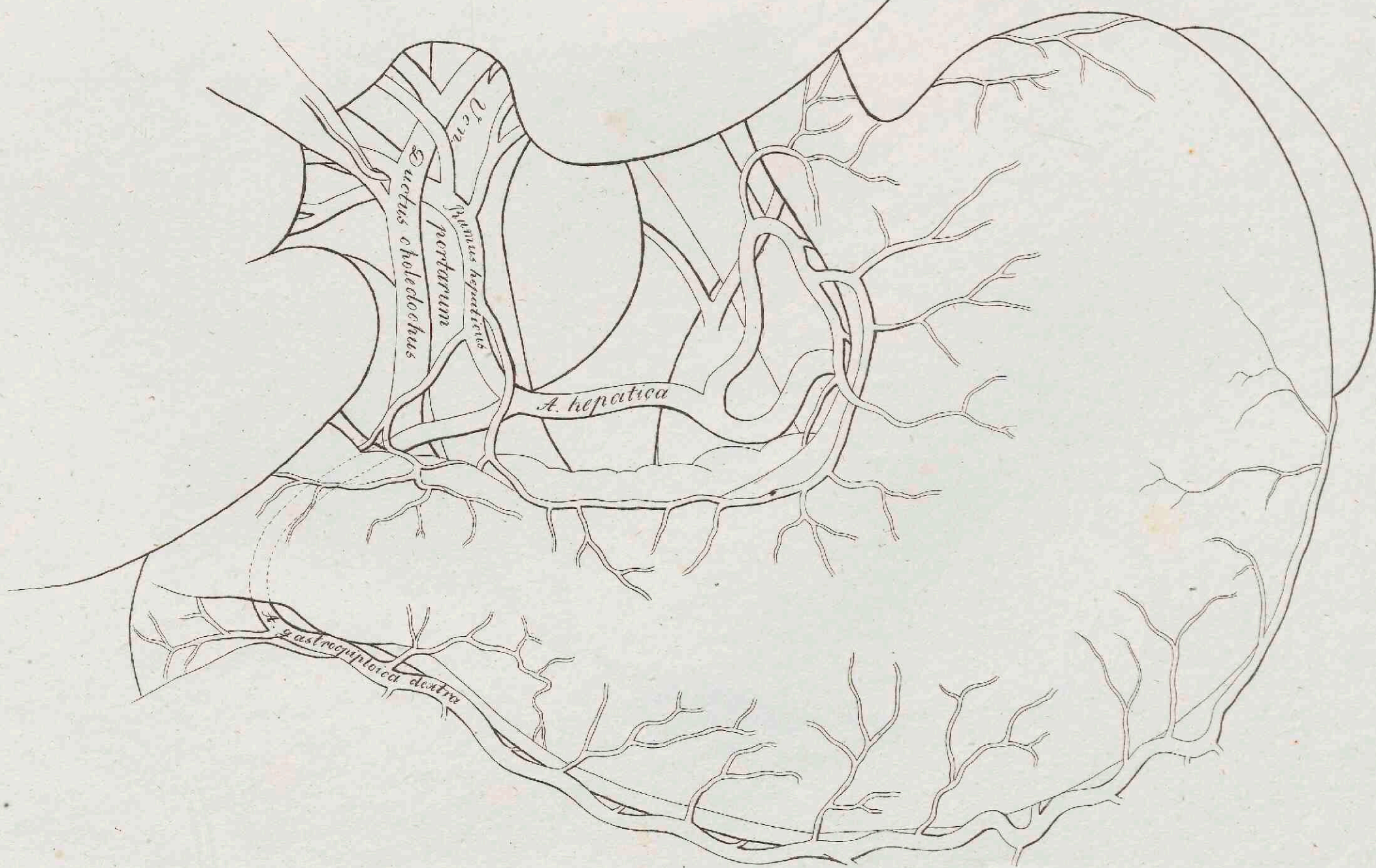


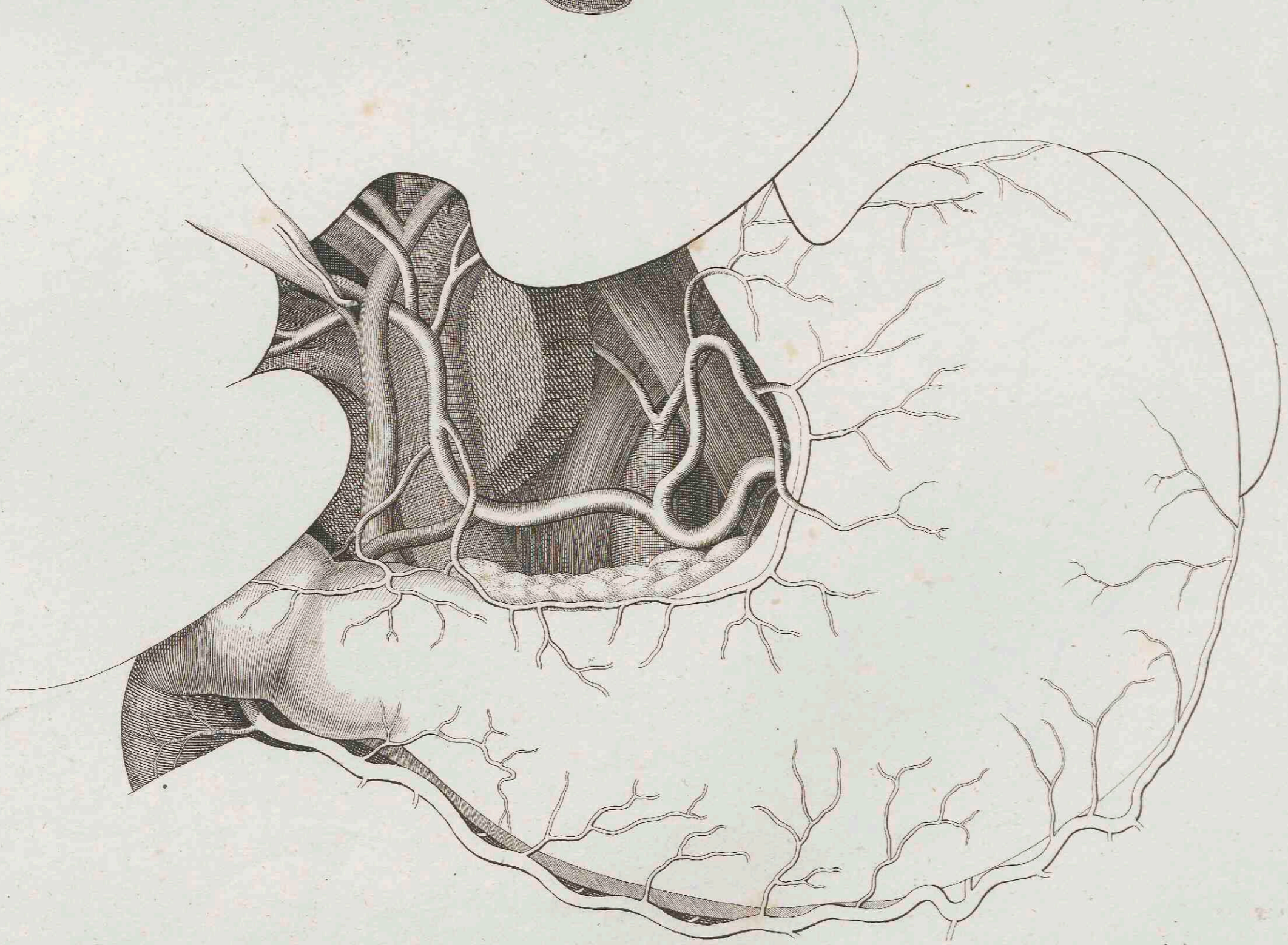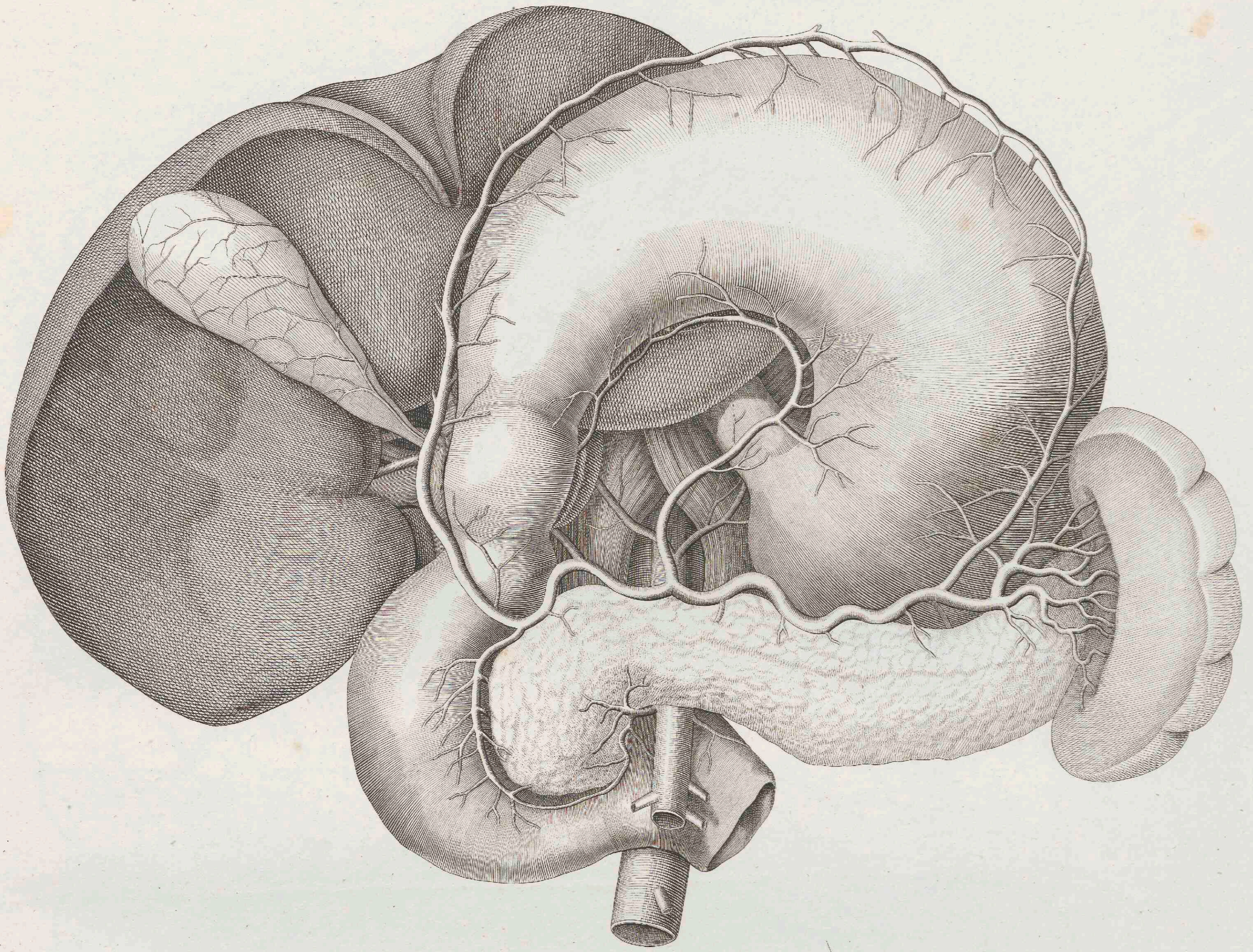
Dreigetheilte Bauchpulsader

umgearbeitet nach Tiedemann.



Arteria coeliaca

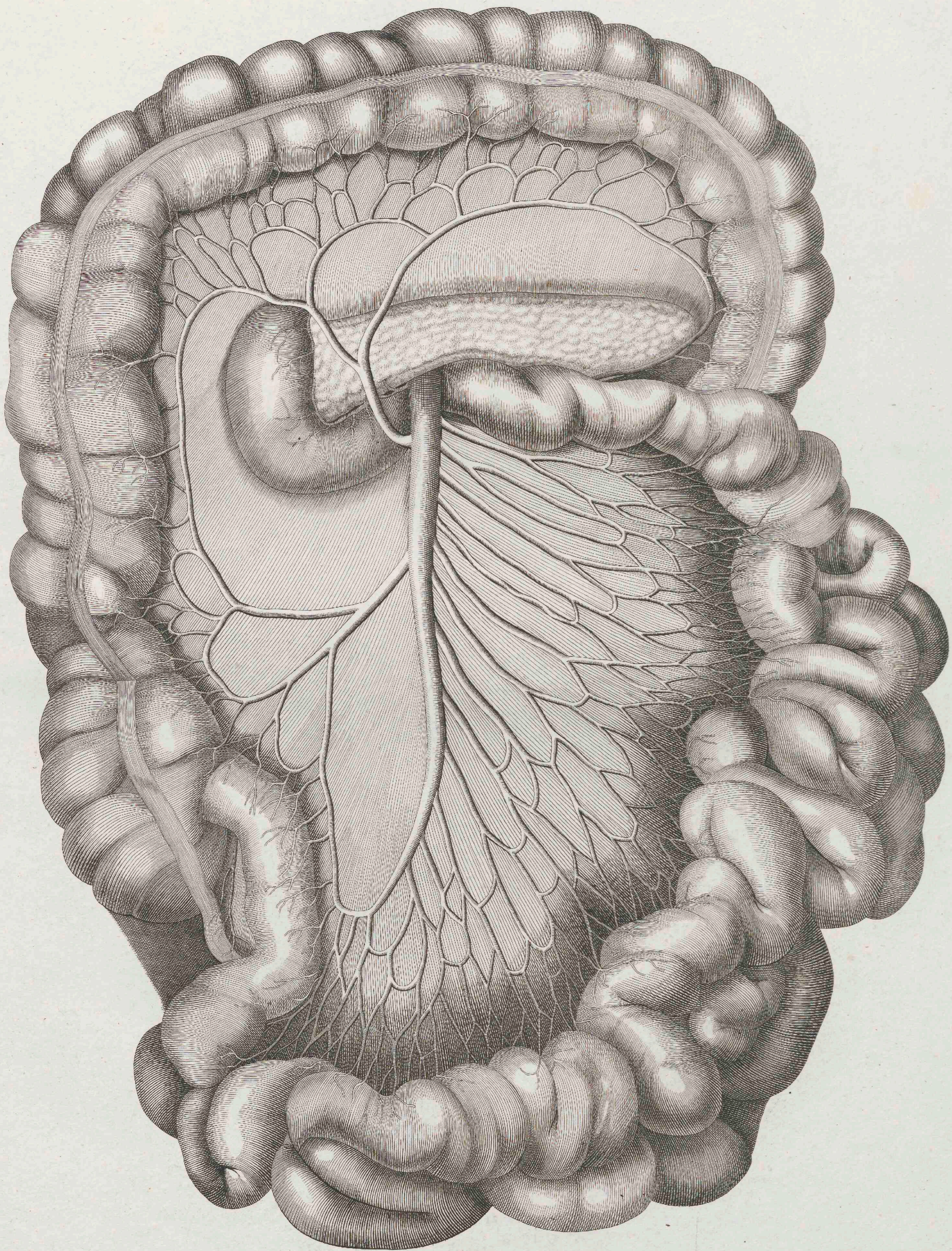




Pulsadern des Darms, umgearbeitet nach Tiedemann.

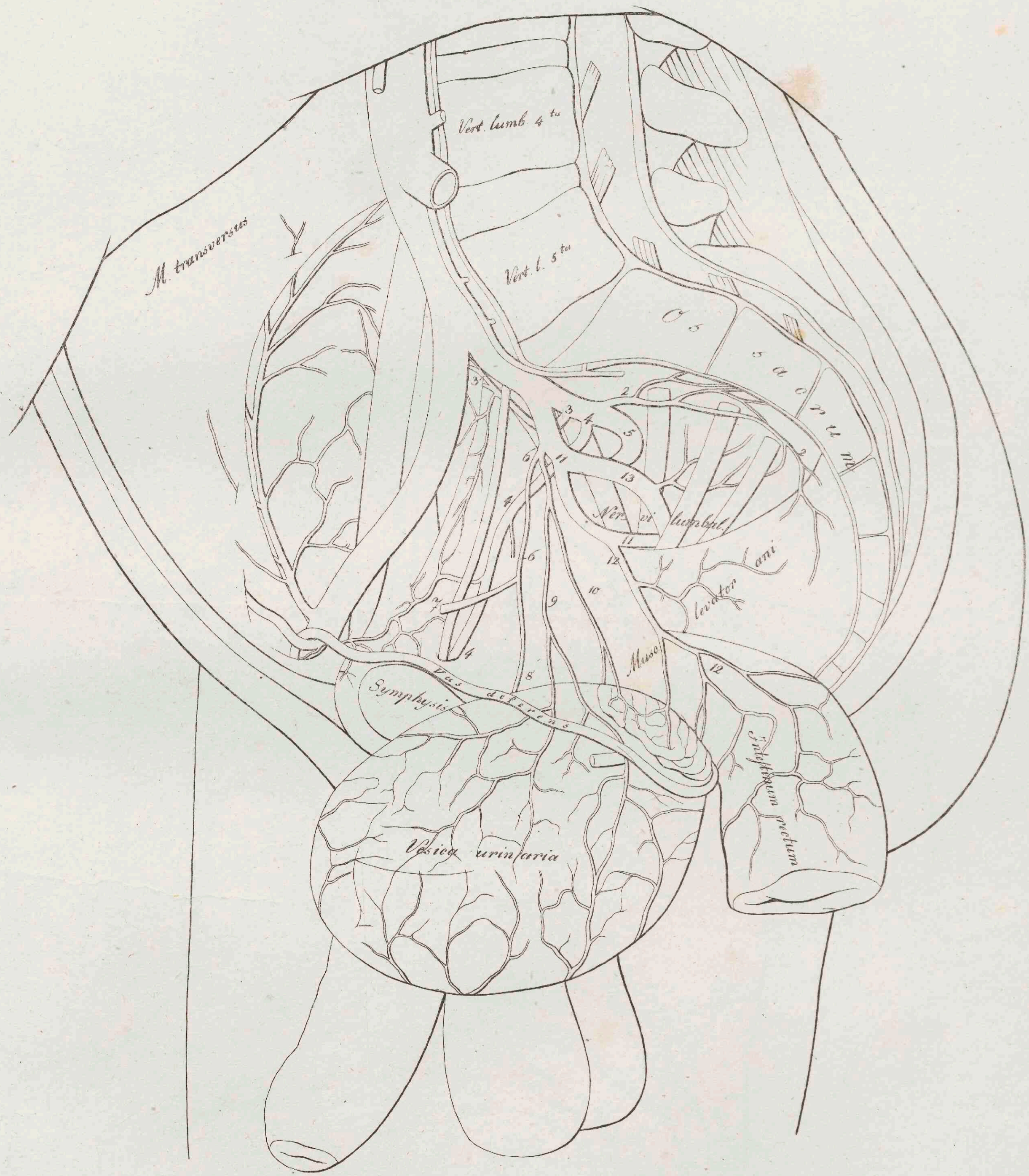

Arteria mesenterica superior



Pulsadern des Beckens,

umgearbeitet nach Tiedemann.

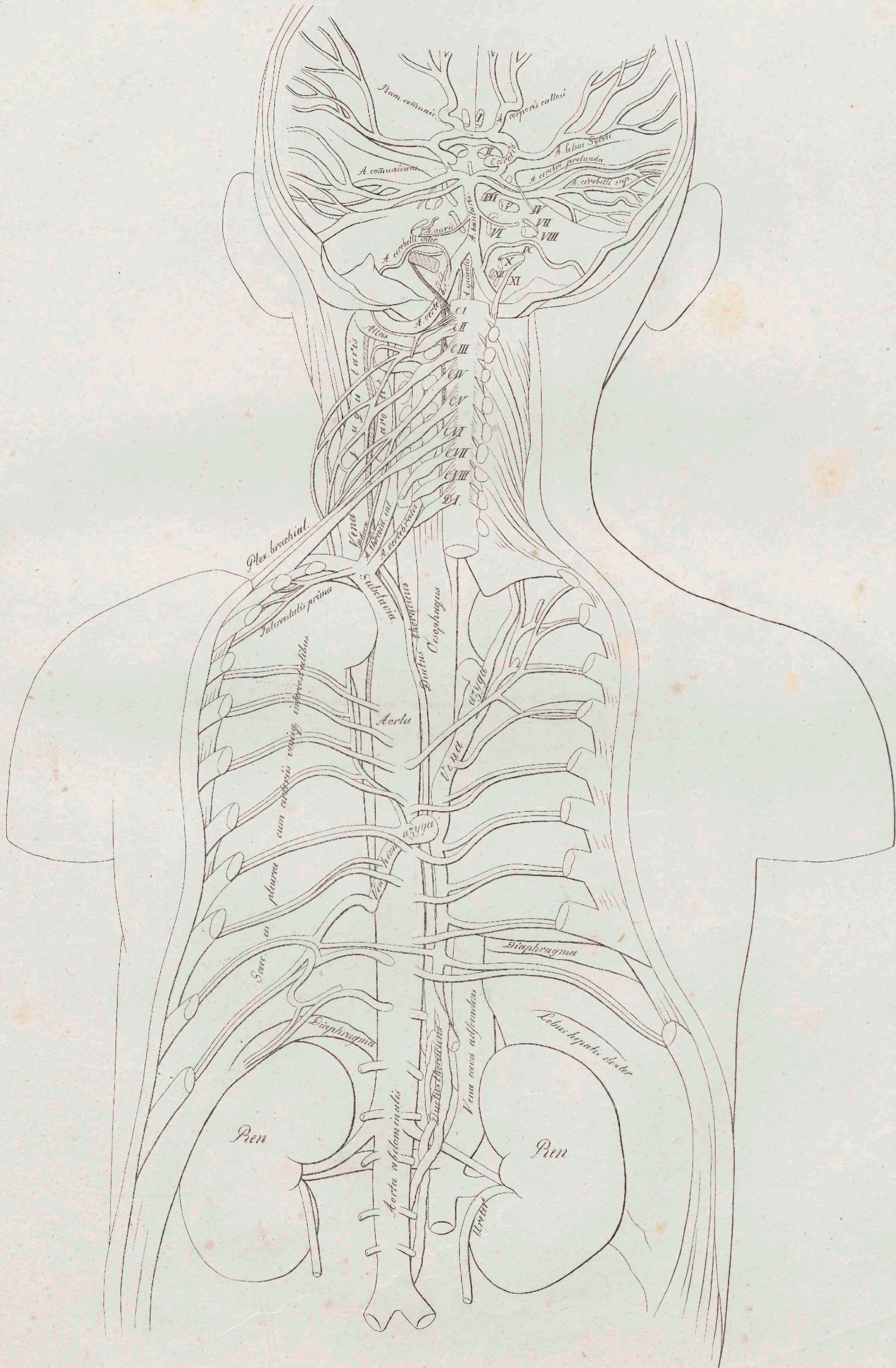


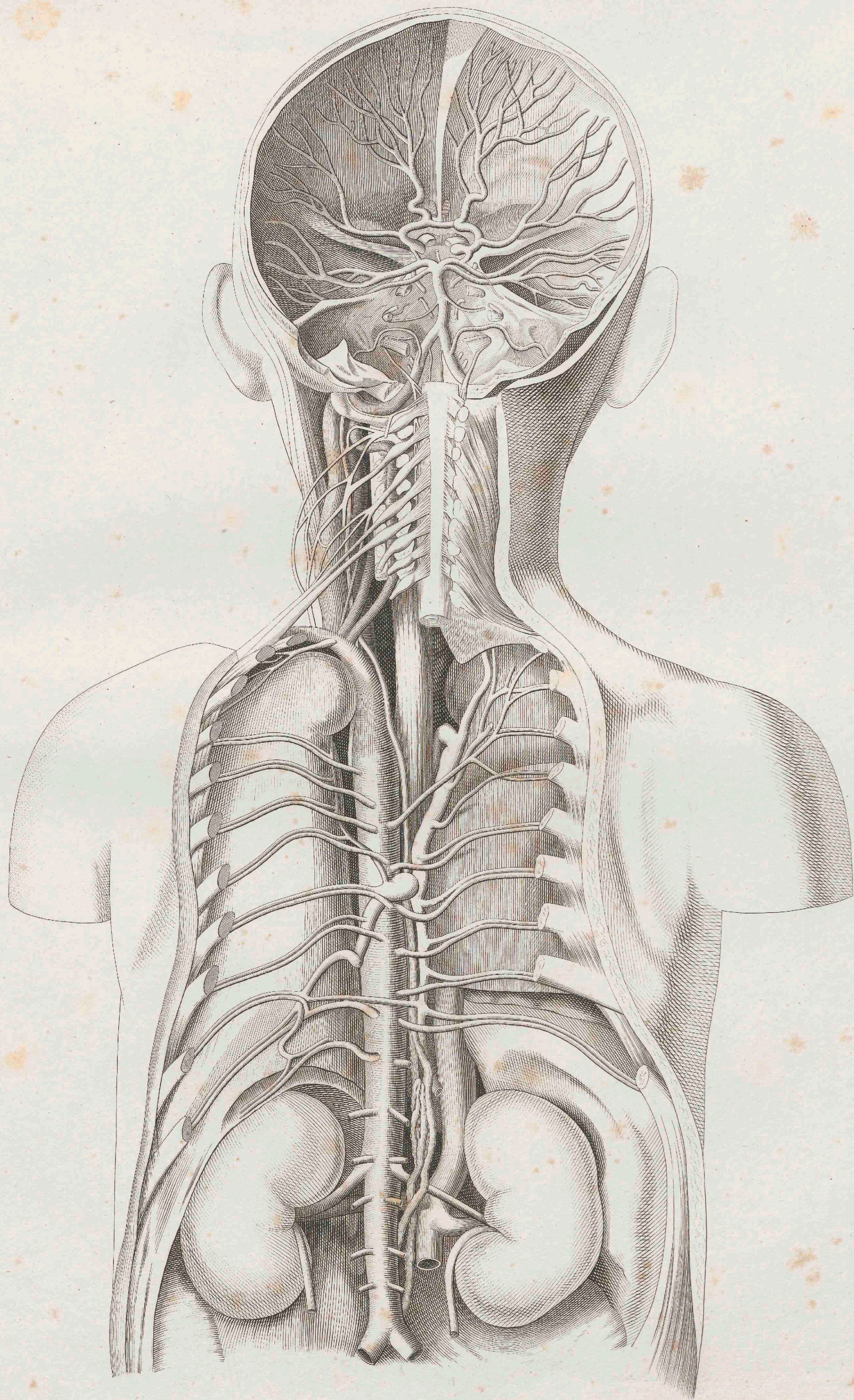
Arteria hypogastrica in viro.

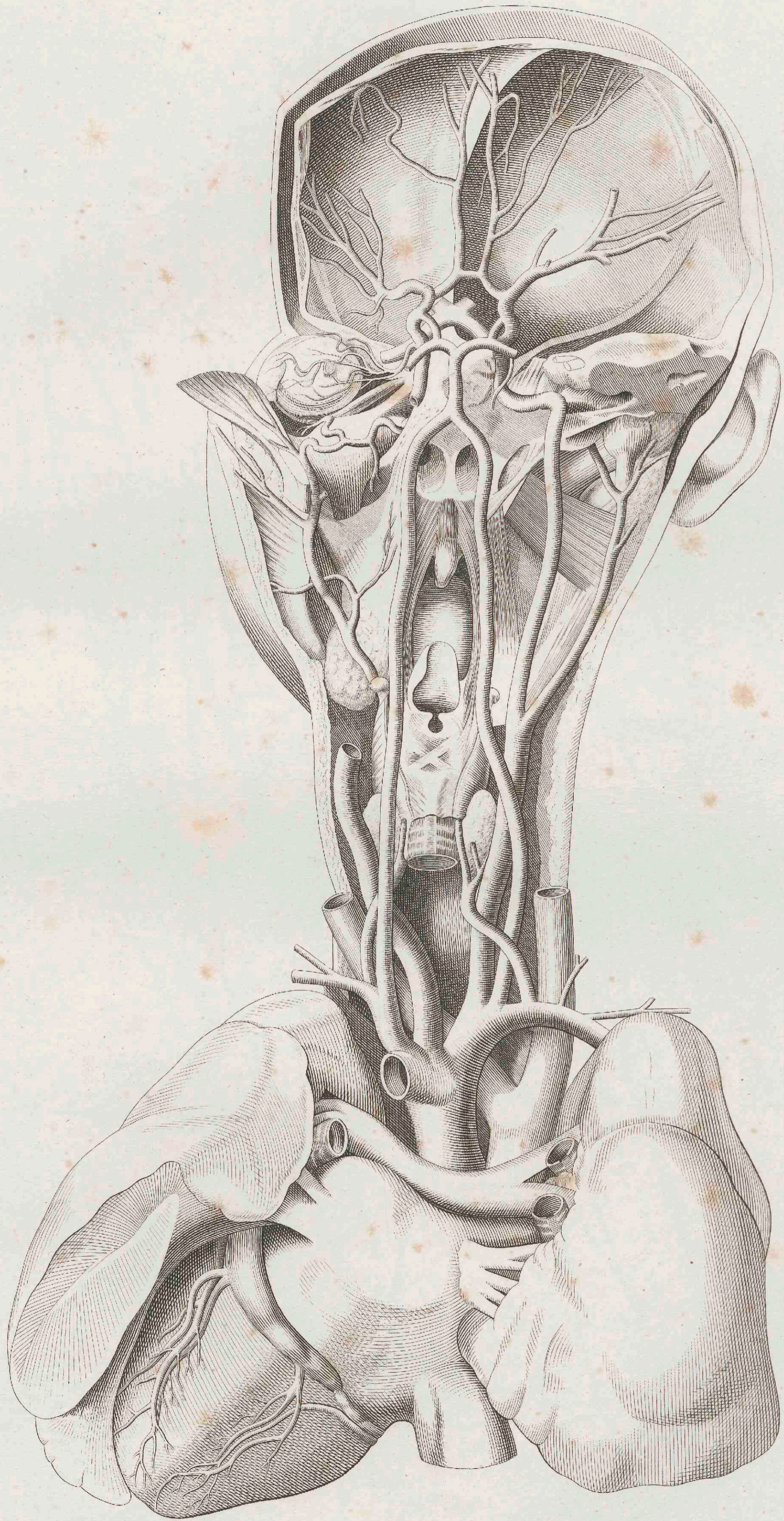
- | | | | | |
|-------------------|----------------------------|----------------------|---------|-------------------------------|
| 2. sacrolateralis | 7. lig. umb. | 8. a. vesicalis sup. | 9. inf. | 10. ram. ad vesicul. seminal. |
| 3. ileolumbalis | | | | |
| 4. obturatoria | | | | |
| 5. glutea | | | | |
| 6. umbilicalis | | | | |
| 11. pudenda | 12. haemorrhoidalis media. | | | |
| 13. ischiadica | | | | |

Pulsadern des Kopfs, Halses, u. der Brust.

nach Langenbeck.

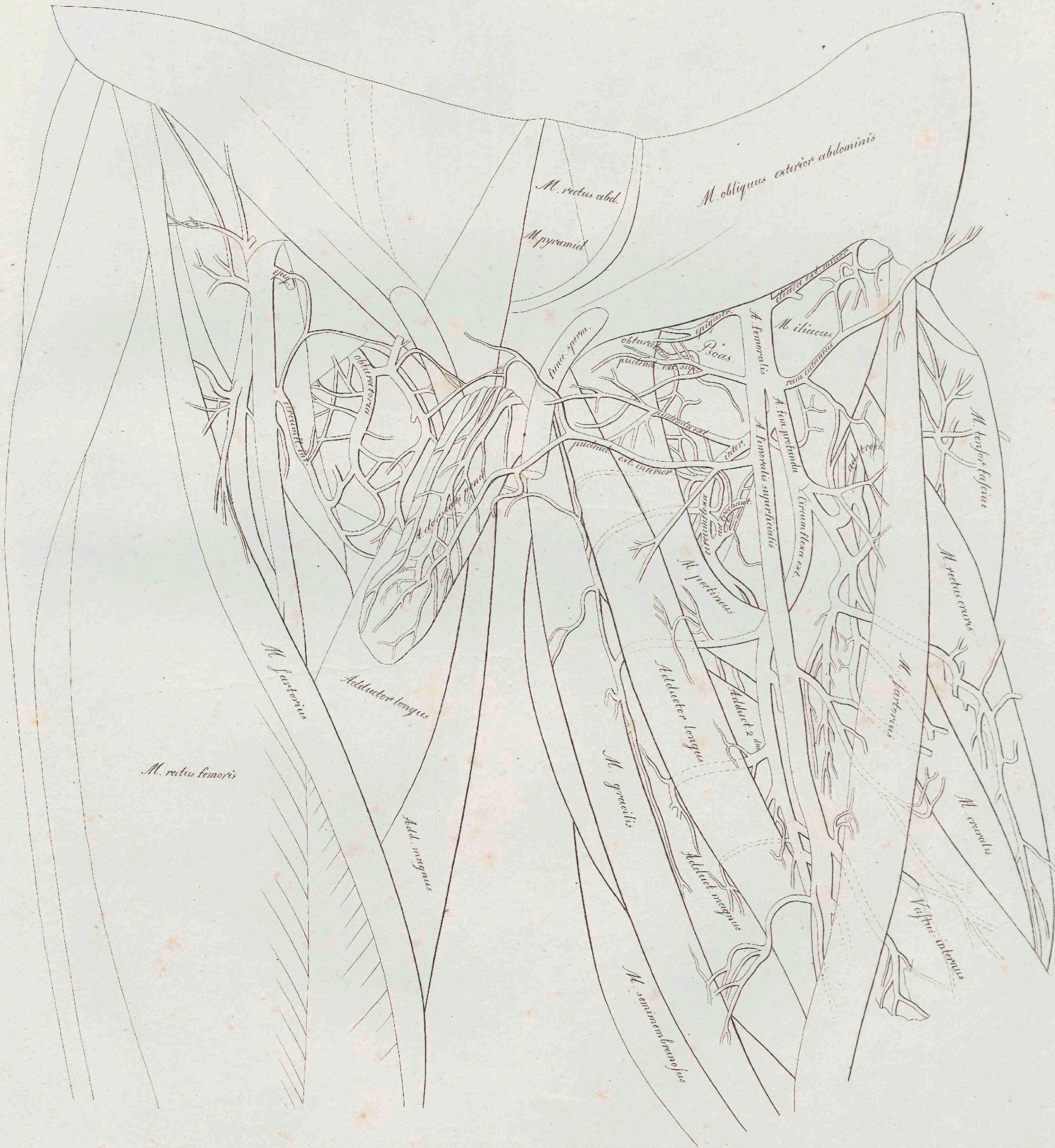


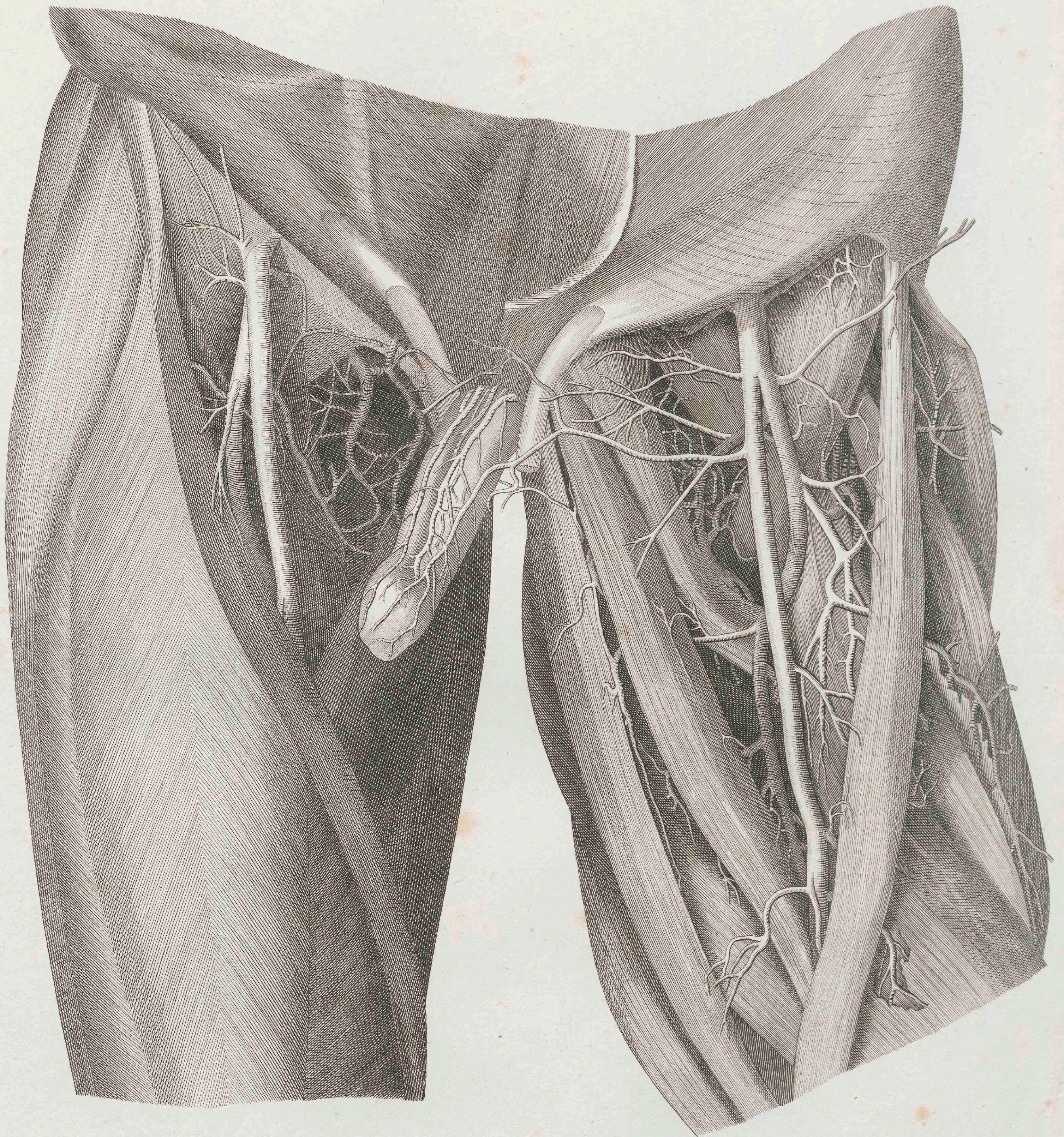




Pulsadern des Schenkels,

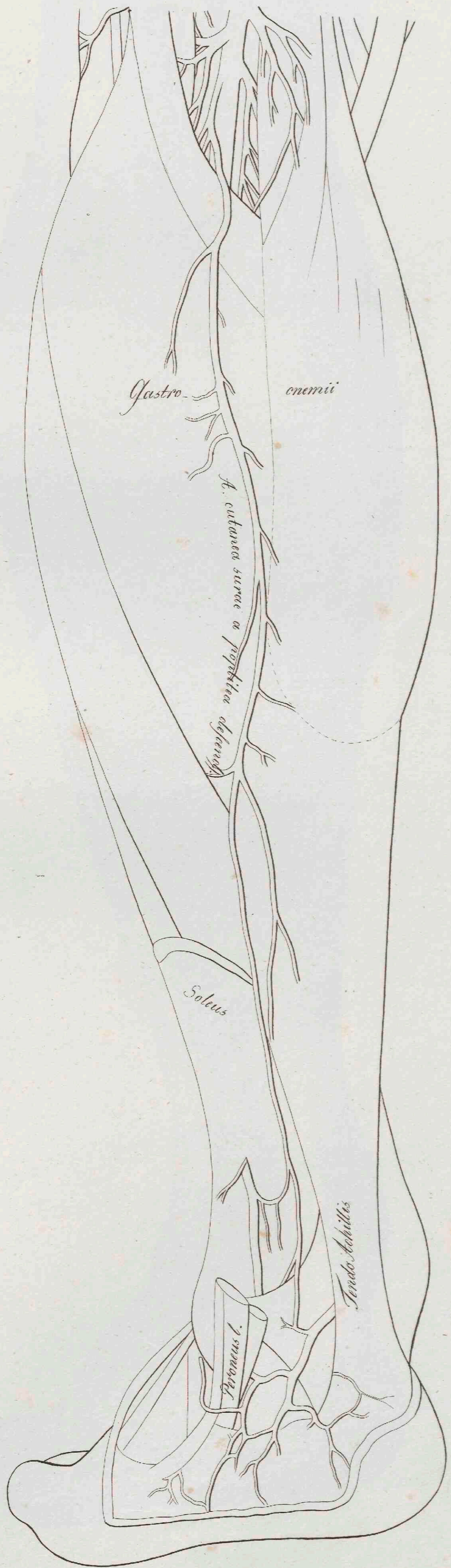
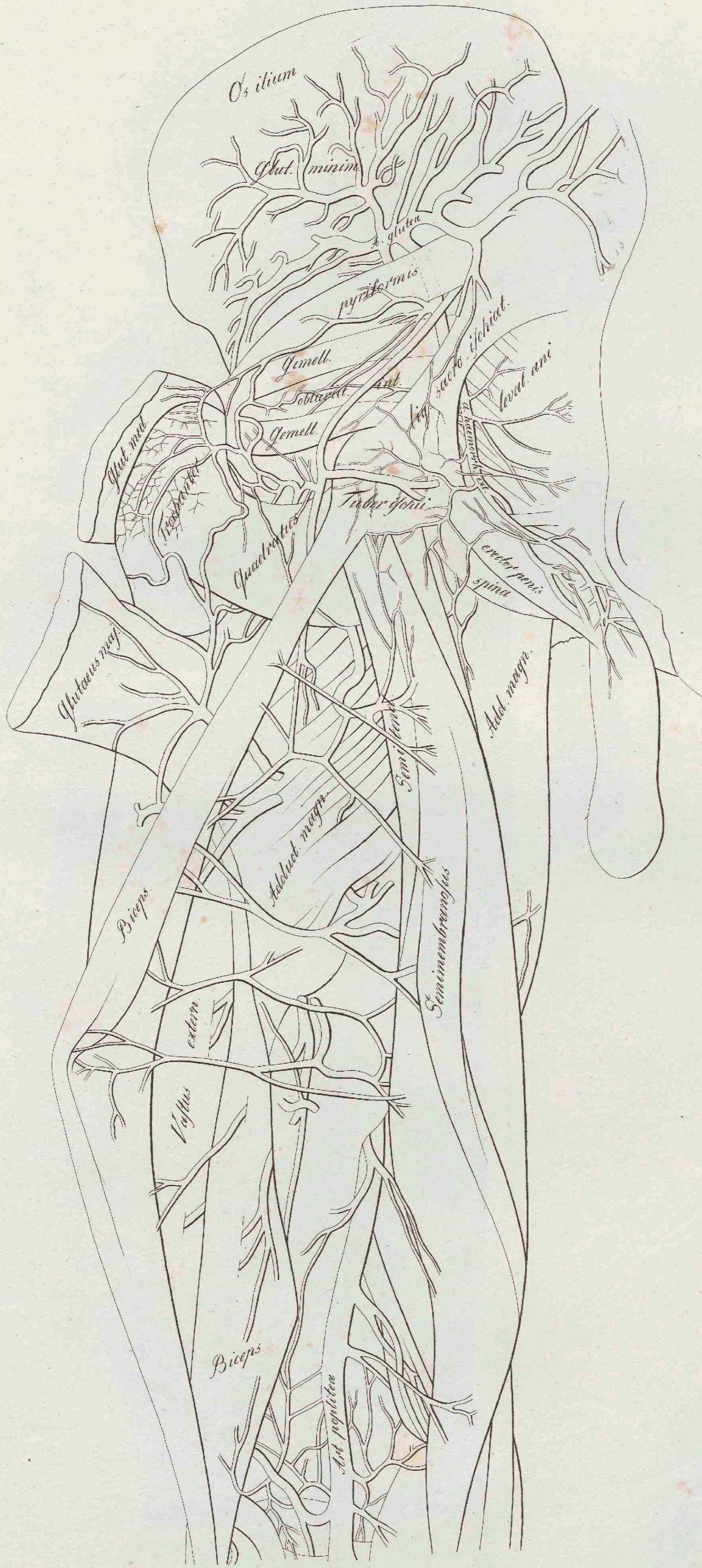
nach Caldani - Scarpa -

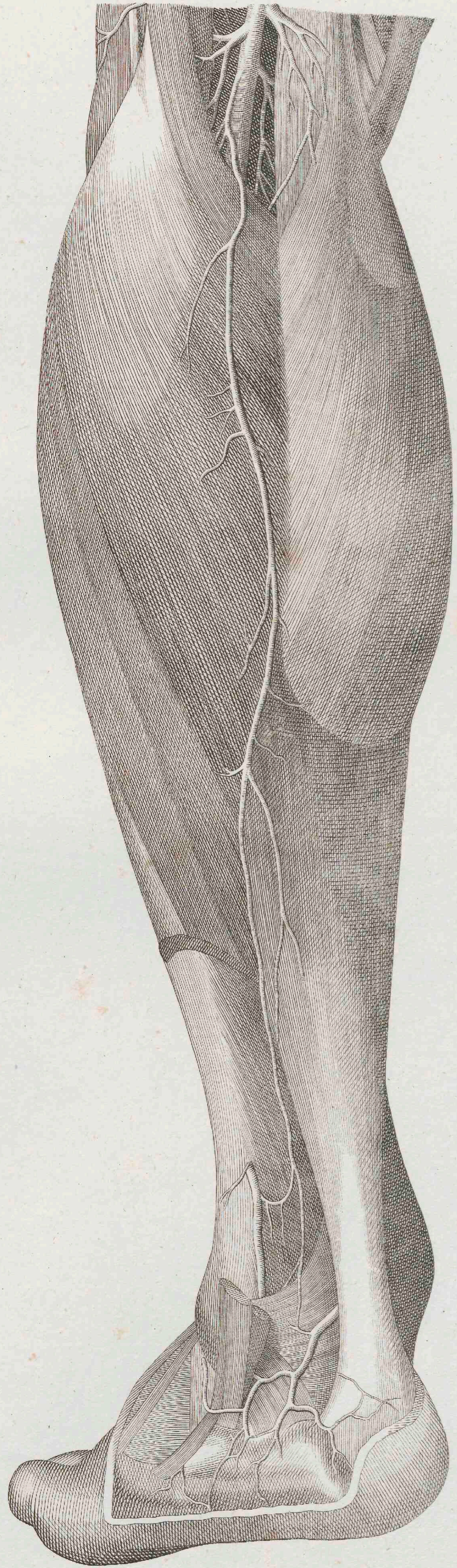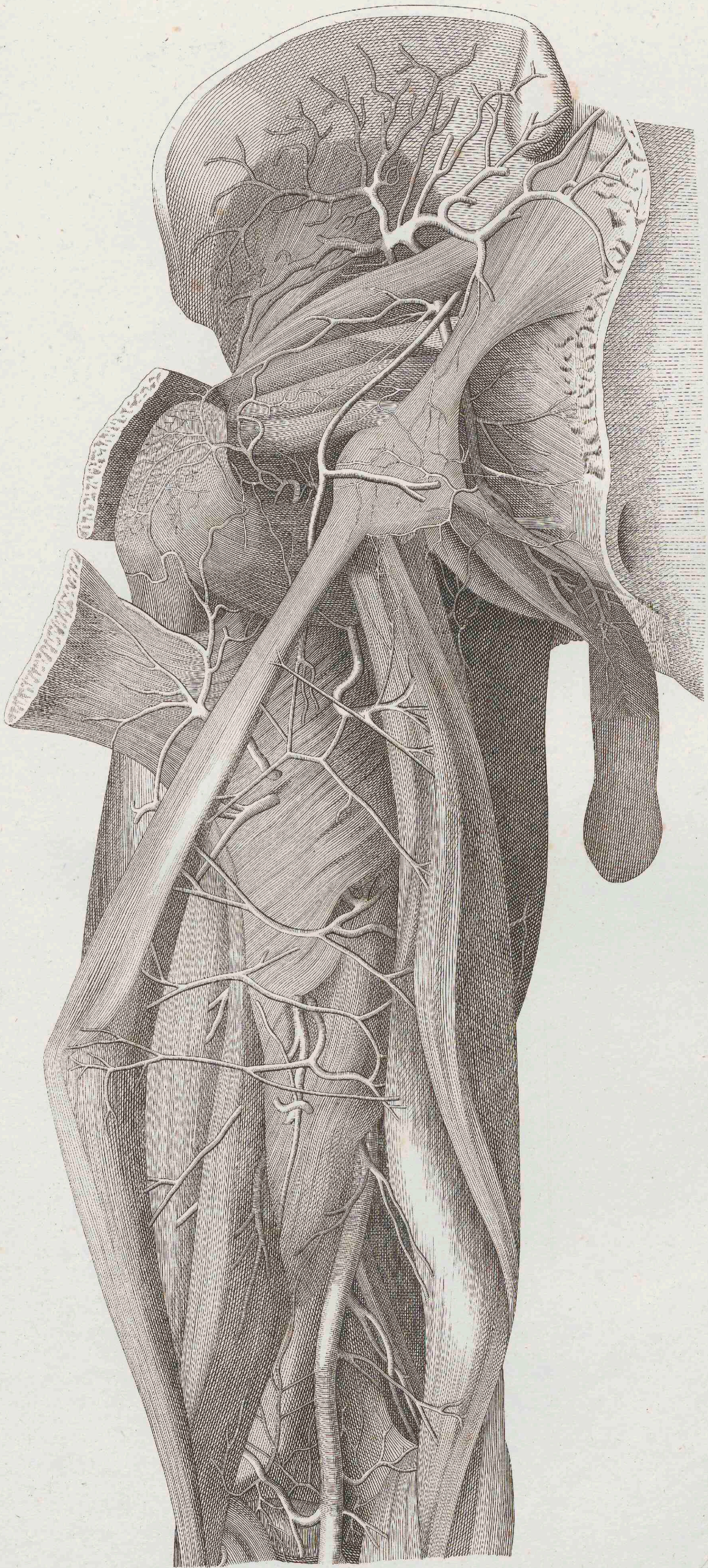




Pulsadern des Schenkeis,

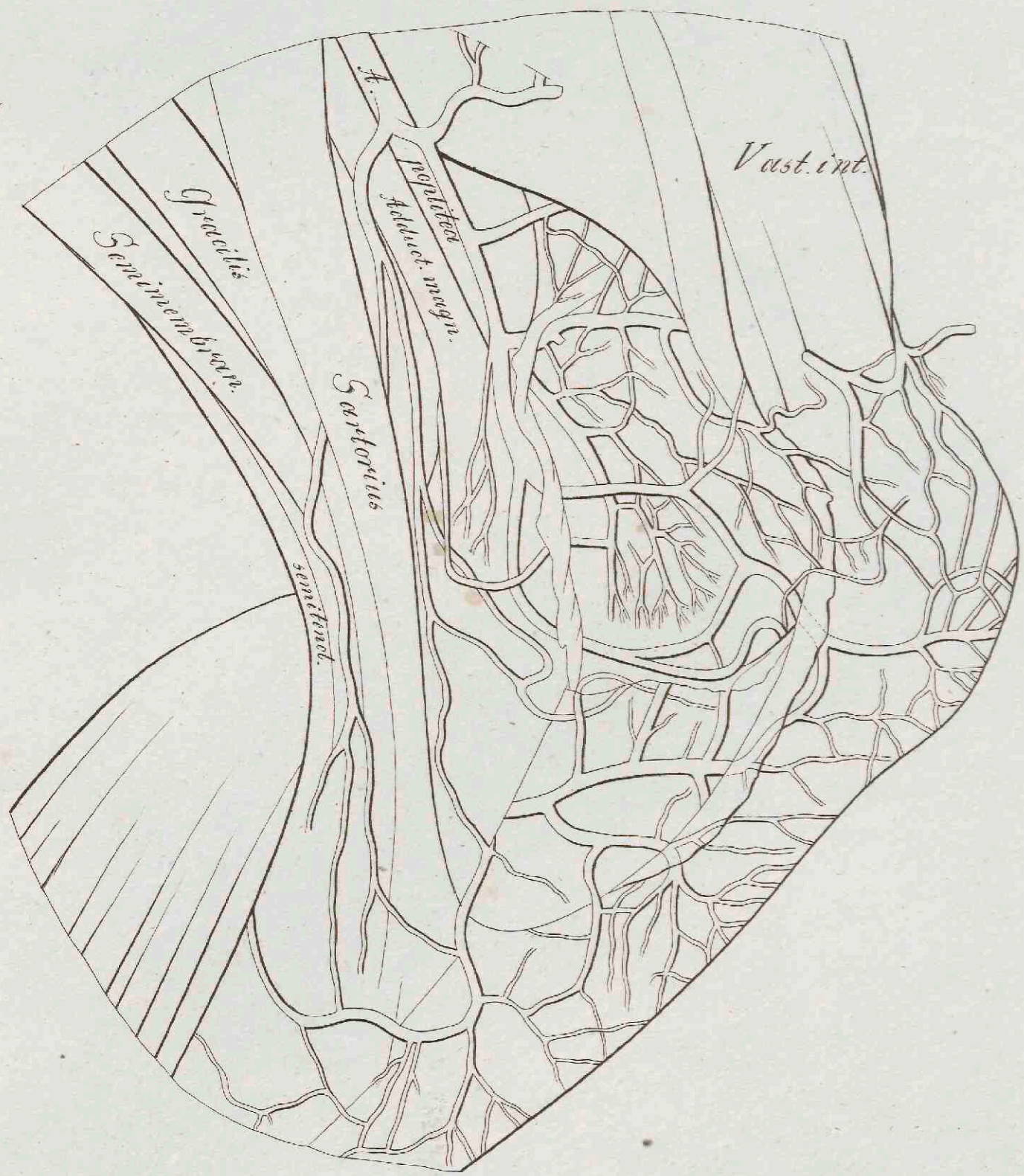
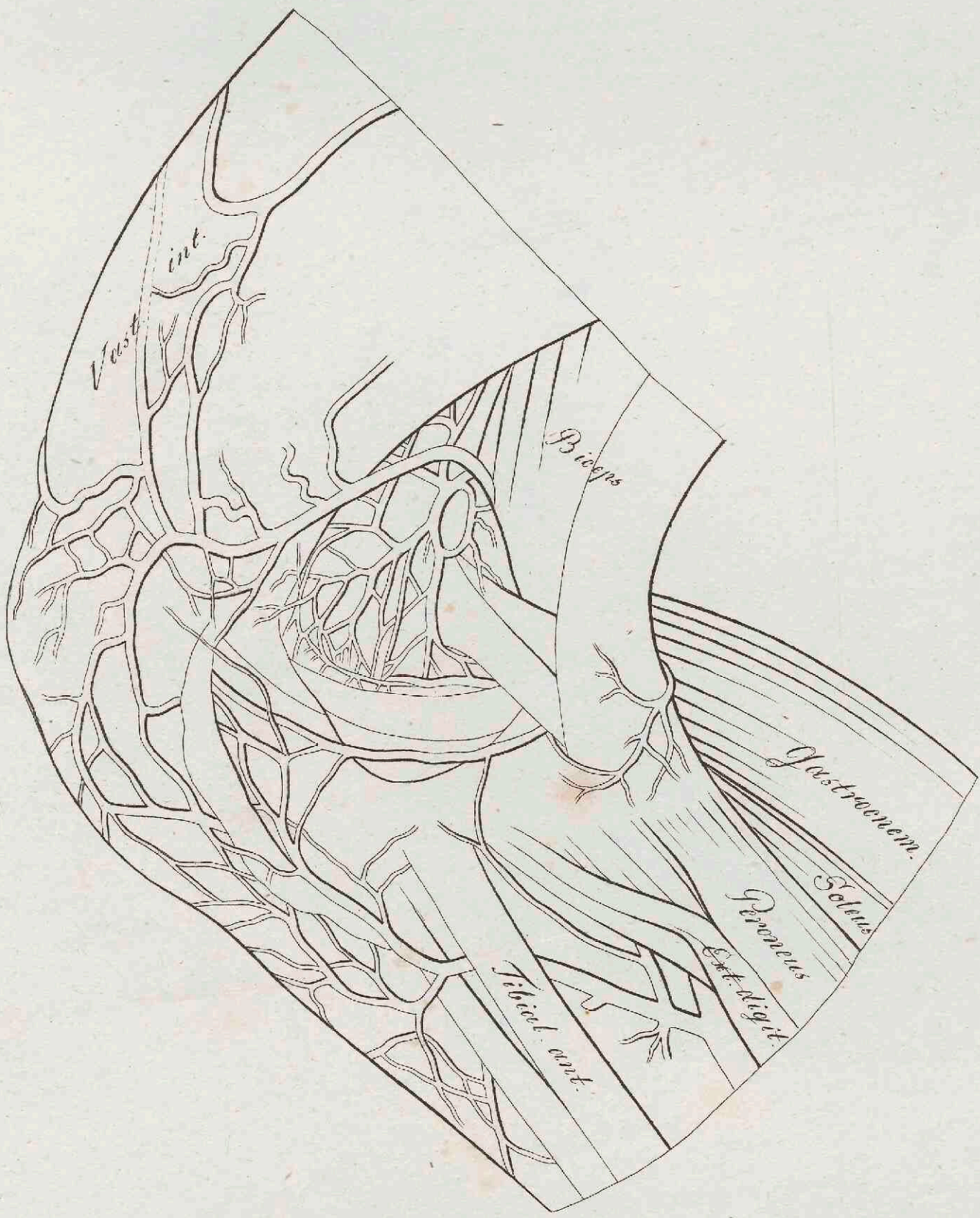
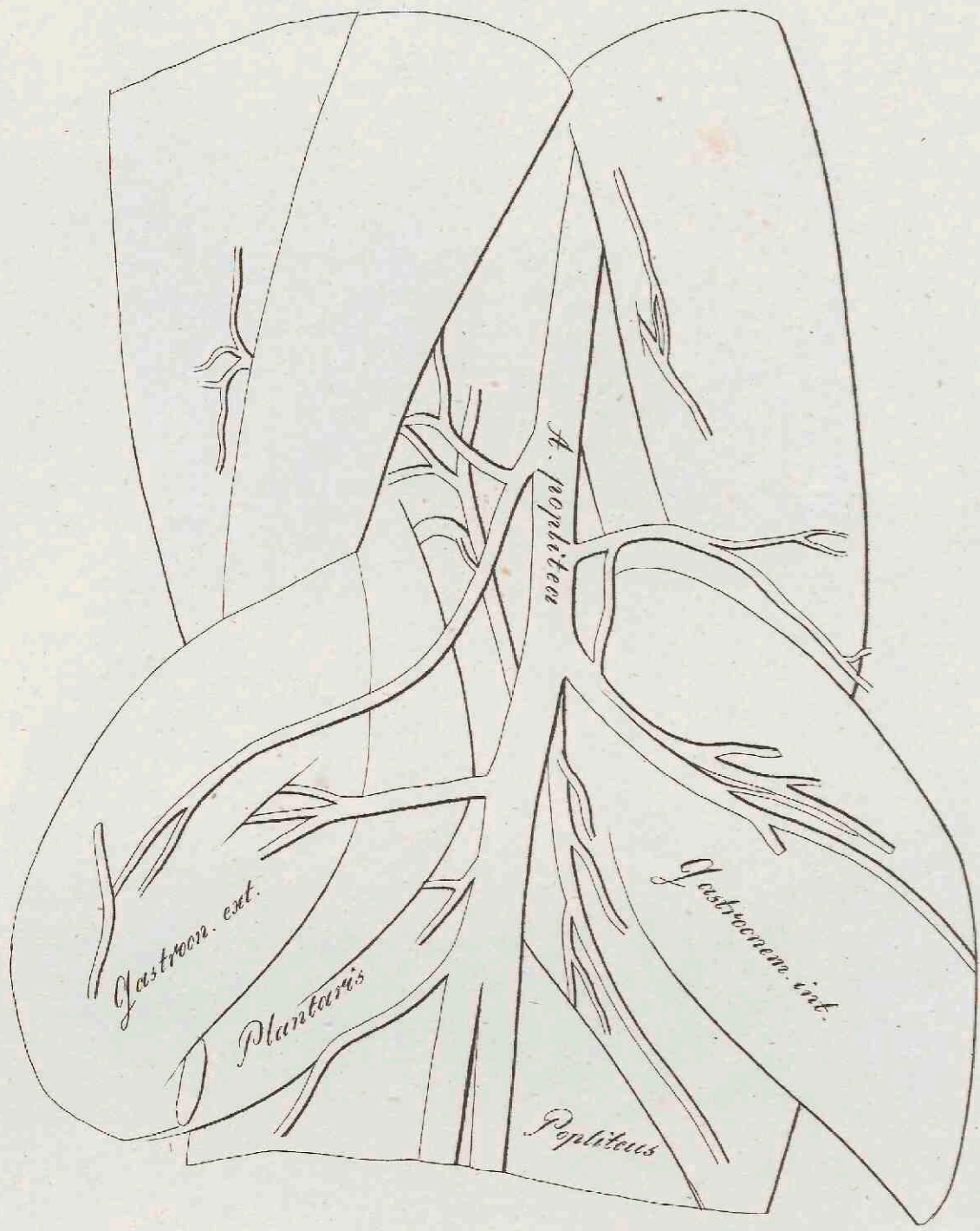
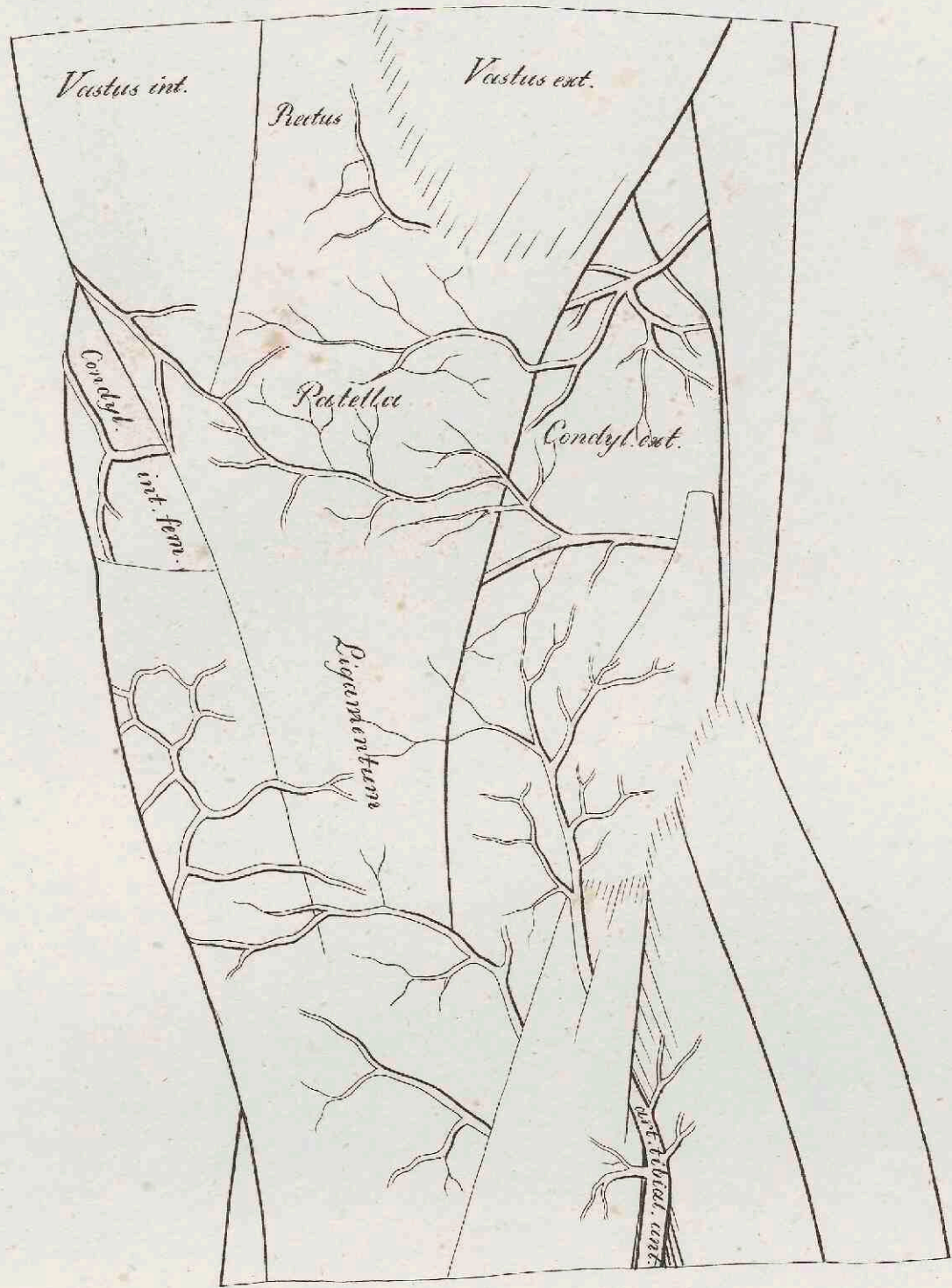nach Caldani - Scarpa.



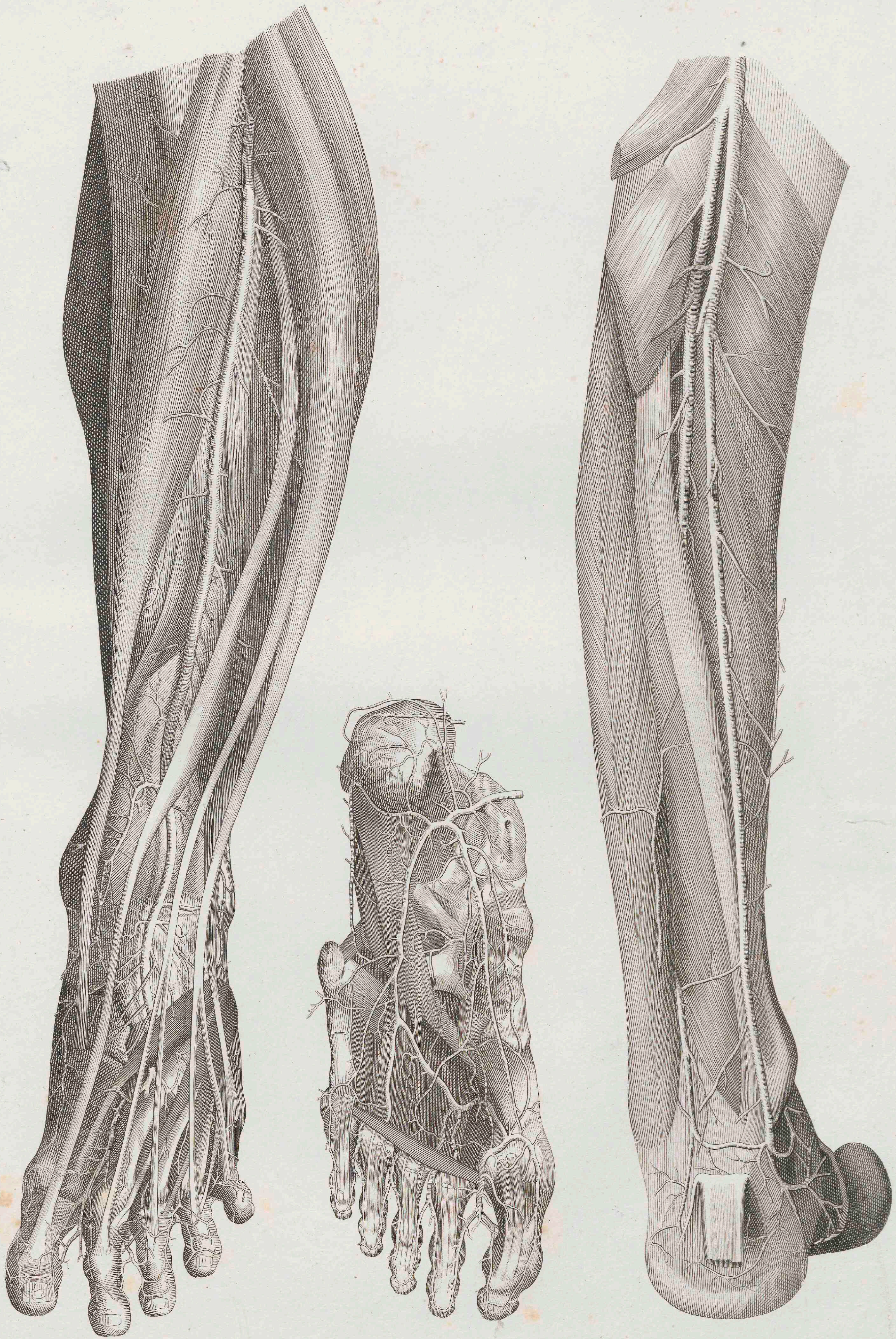


Pulsadern des Knie's,

nach Caldani.



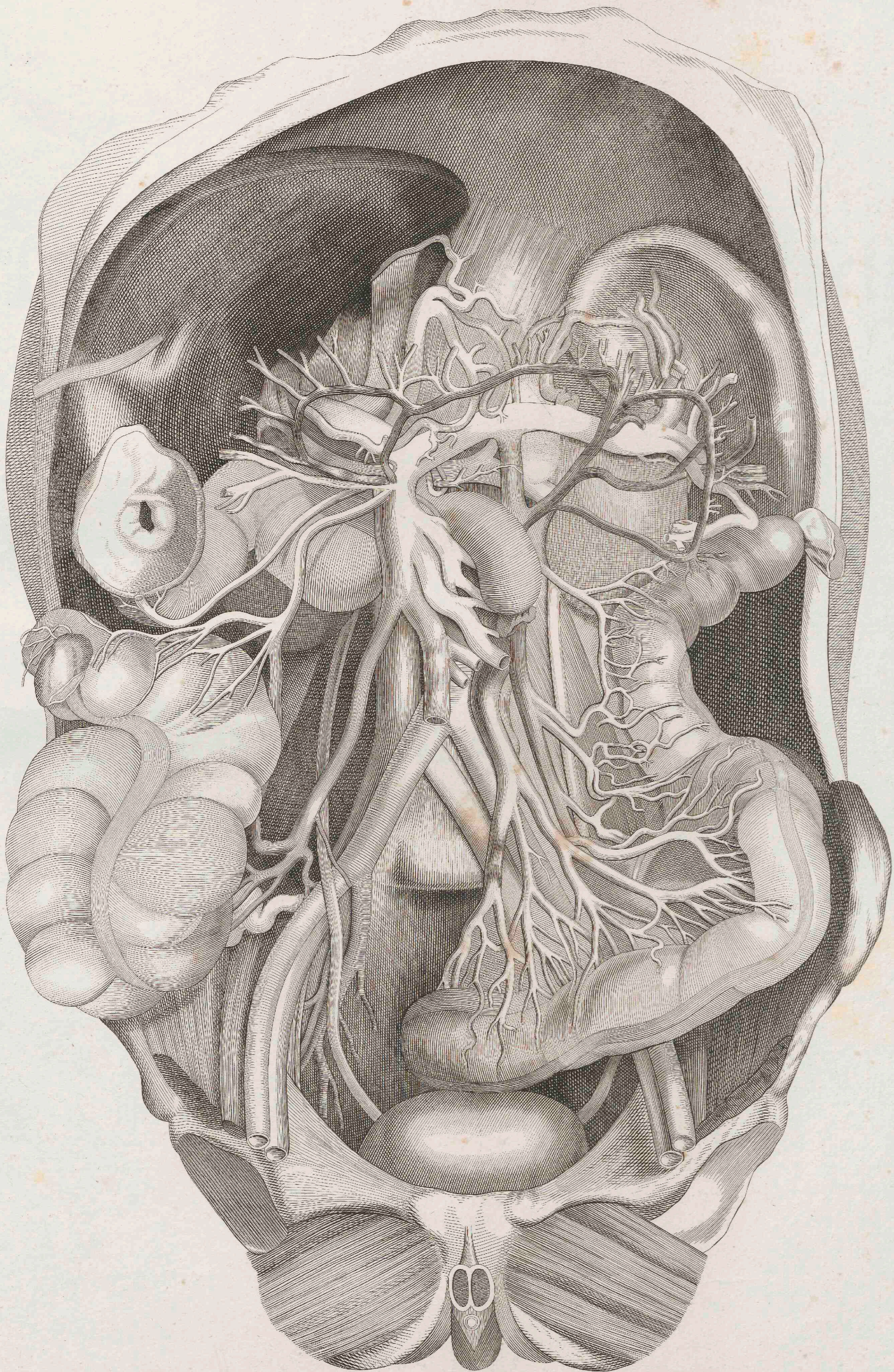
Arteriae articulares.



Pfortader

nach Caldani.





OESTERREICHER'S

Anatomische Steinstücke.

Sechste Abtheilung

Nerven

des

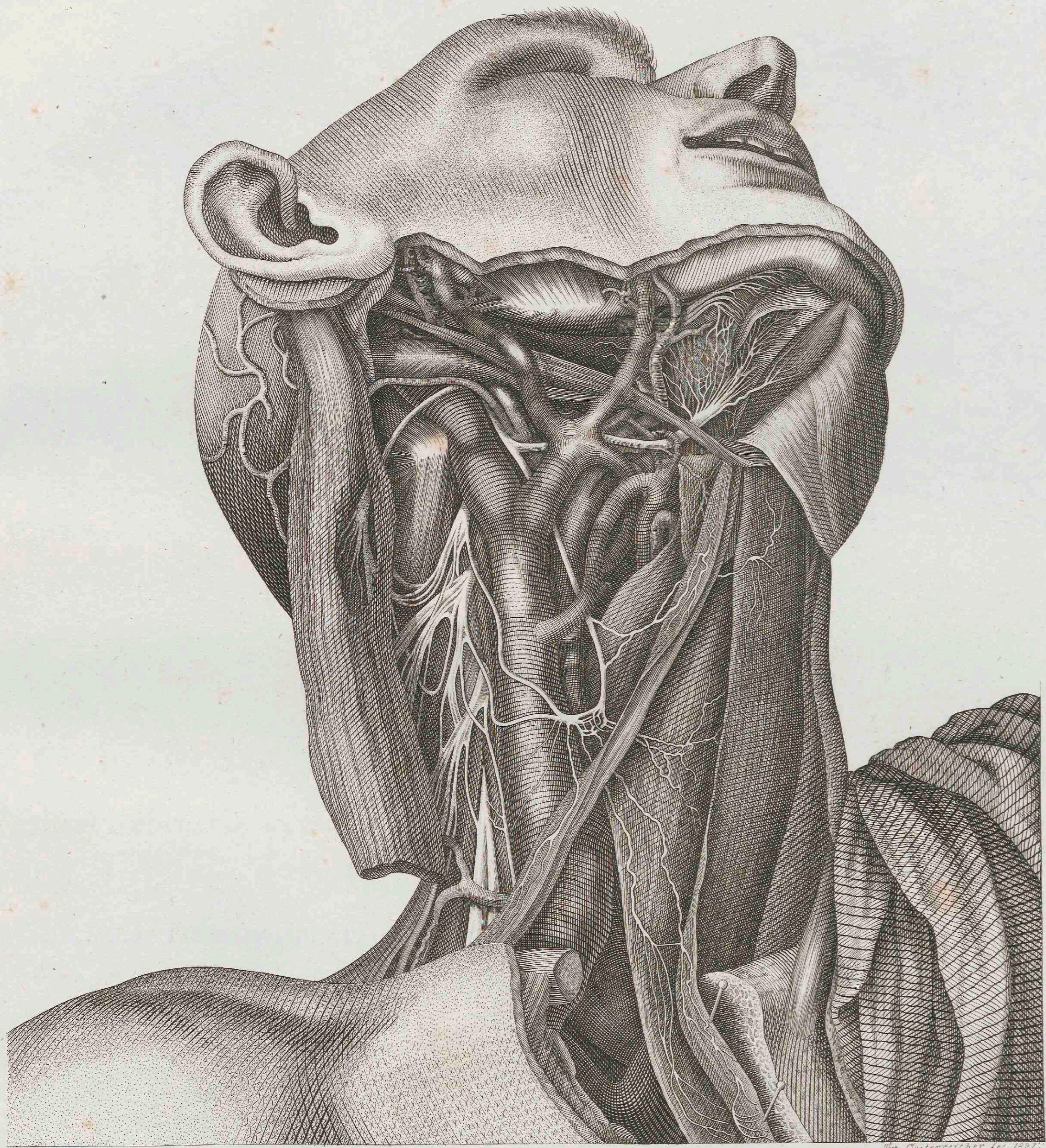
Menschlichen Körpers.

Veranst. v. Oesterreich.

Gedruckt v. J. v. Harpfer.

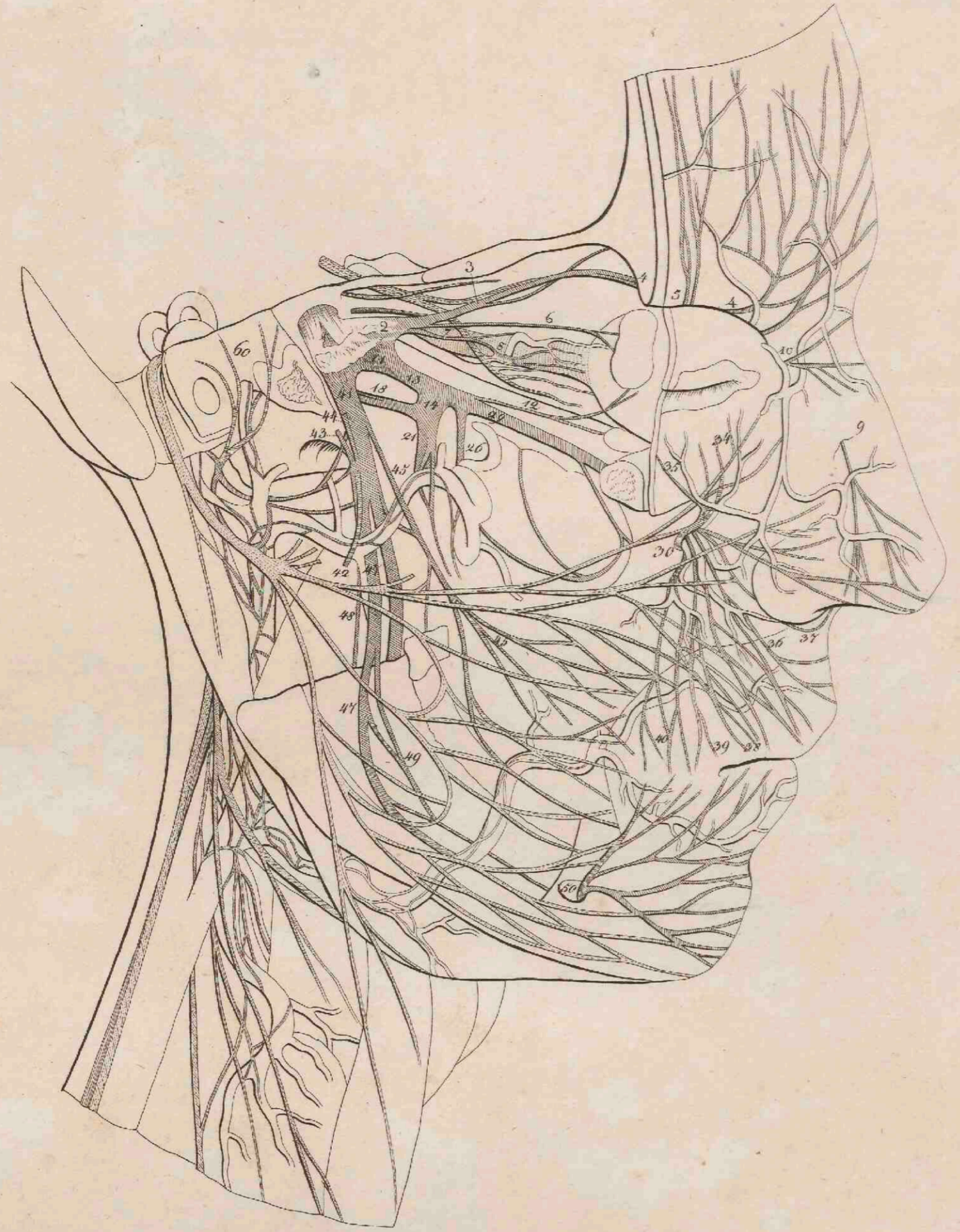
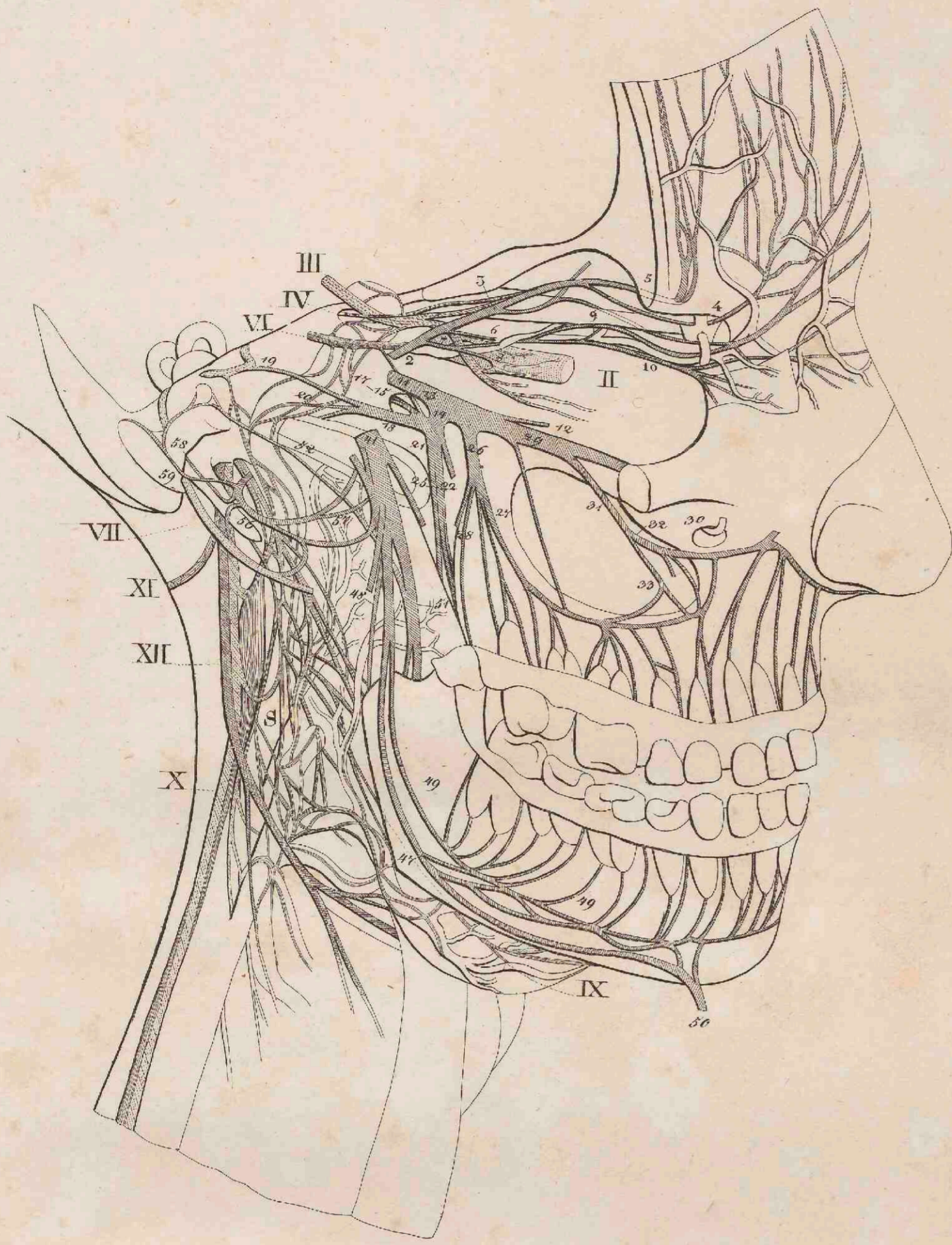
München

1829



Dreigetheilter Nerve

nach Bock.



V Trigemini 1.

- | | | | | | | | | | | | | | | | | | | | | | | | | | | | | | | | | | | | | | | | | | |
|--|--|-----------------------------------|---------------------------------|---------------------------------|------------------|------------------------------|--|---|-----------------------------|---------------|----------------------|--------------------------|-----------------|------------------|---------------------------------|---------------------------------|------------------------|-----------------|------------------|-------------------------------|-------------------------------|------------------------|---------------------|-----------------------|----------------------|------------------|--|-----------------------------------|-----------------------------------|-------------------|------------------|--|------------------|-----------------------|--------------|------------------------------|--|-----------------------------|----------------------------------|-----------------|--------------|
| 2. ramus orbitalis | <table border="0"> <tr> <td>3. frontalis</td> <td>4. supratrochlearis</td> </tr> <tr> <td>6. lacrymalis</td> <td>5. ——— orbitalis</td> </tr> <tr> <td>7. nasalis</td> <td>8. ciliaris ad ganglion</td> </tr> <tr> <td></td> <td>9. ethmoidalis</td> </tr> <tr> <td></td> <td>10. infratrochlearis</td> </tr> </table> | 3. frontalis | 4. supratrochlearis | 6. lacrymalis | 5. ——— orbitalis | 7. nasalis | 8. ciliaris ad ganglion | | 9. ethmoidalis | | 10. infratrochlearis | | | | | | | | | | | | | | | | | | | | | | | | | | | | | | |
| 3. frontalis | 4. supratrochlearis | | | | | | | | | | | | | | | | | | | | | | | | | | | | | | | | | | | | | | | | |
| 6. lacrymalis | 5. ——— orbitalis | | | | | | | | | | | | | | | | | | | | | | | | | | | | | | | | | | | | | | | | |
| 7. nasalis | 8. ciliaris ad ganglion | | | | | | | | | | | | | | | | | | | | | | | | | | | | | | | | | | | | | | | | |
| | 9. ethmoidalis | | | | | | | | | | | | | | | | | | | | | | | | | | | | | | | | | | | | | | | | |
| | 10. infratrochlearis | | | | | | | | | | | | | | | | | | | | | | | | | | | | | | | | | | | | | | | | |
| 11. r. maxillaris superior | <table border="0"> <tr> <td>12. subcutaneus malae</td> <td>13. sphenopalatinus</td> <td>14. ganglion</td> <td>15. vidianus</td> <td>16. superficialis</td> </tr> <tr> <td>13. rami nasales superiores anteriores</td> <td>14. rami nasales superiores posteriores</td> <td>15. rami nasales inferiores</td> <td>16. palatinus</td> <td>17. major</td> </tr> <tr> <td>16. nasopalatinus Scarpa</td> <td>17. r. anterior</td> <td>18. r. posterior</td> <td>19. dentalis posterior superior</td> <td>20. dentalis posterior inferior</td> </tr> <tr> <td>26. dentalis posterior</td> <td>27. r. anterior</td> <td>28. r. posterior</td> <td>29. subcutaneus nasi superior</td> <td>30. subcutaneus nasi inferior</td> </tr> <tr> <td>29, 30. infraorbitalis</td> <td>31. labialis primus</td> <td>32. labialis secundus</td> <td>33. labialis tertius</td> <td>34. massetericus</td> </tr> <tr> <td></td> <td>35. temporalis profundus exterior</td> <td>36. temporalis profundus interior</td> <td>37. buccinatorius</td> <td>38. pterygoideus</td> </tr> <tr> <td></td> <td>39. mylohyoideus</td> <td>40. dentalis inferior</td> <td>41. mentalis</td> <td>42. Insertio chordae tympani</td> </tr> <tr> <td></td> <td>43. plexus anserinus Bockii</td> <td>44. r. inferior meatus auditorii</td> <td>45. r. superior</td> <td>46. decursus</td> </tr> </table> | 12. subcutaneus malae | 13. sphenopalatinus | 14. ganglion | 15. vidianus | 16. superficialis | 13. rami nasales superiores anteriores | 14. rami nasales superiores posteriores | 15. rami nasales inferiores | 16. palatinus | 17. major | 16. nasopalatinus Scarpa | 17. r. anterior | 18. r. posterior | 19. dentalis posterior superior | 20. dentalis posterior inferior | 26. dentalis posterior | 27. r. anterior | 28. r. posterior | 29. subcutaneus nasi superior | 30. subcutaneus nasi inferior | 29, 30. infraorbitalis | 31. labialis primus | 32. labialis secundus | 33. labialis tertius | 34. massetericus | | 35. temporalis profundus exterior | 36. temporalis profundus interior | 37. buccinatorius | 38. pterygoideus | | 39. mylohyoideus | 40. dentalis inferior | 41. mentalis | 42. Insertio chordae tympani | | 43. plexus anserinus Bockii | 44. r. inferior meatus auditorii | 45. r. superior | 46. decursus |
| 12. subcutaneus malae | 13. sphenopalatinus | 14. ganglion | 15. vidianus | 16. superficialis | | | | | | | | | | | | | | | | | | | | | | | | | | | | | | | | | | | | | |
| 13. rami nasales superiores anteriores | 14. rami nasales superiores posteriores | 15. rami nasales inferiores | 16. palatinus | 17. major | | | | | | | | | | | | | | | | | | | | | | | | | | | | | | | | | | | | | |
| 16. nasopalatinus Scarpa | 17. r. anterior | 18. r. posterior | 19. dentalis posterior superior | 20. dentalis posterior inferior | | | | | | | | | | | | | | | | | | | | | | | | | | | | | | | | | | | | | |
| 26. dentalis posterior | 27. r. anterior | 28. r. posterior | 29. subcutaneus nasi superior | 30. subcutaneus nasi inferior | | | | | | | | | | | | | | | | | | | | | | | | | | | | | | | | | | | | | |
| 29, 30. infraorbitalis | 31. labialis primus | 32. labialis secundus | 33. labialis tertius | 34. massetericus | | | | | | | | | | | | | | | | | | | | | | | | | | | | | | | | | | | | | |
| | 35. temporalis profundus exterior | 36. temporalis profundus interior | 37. buccinatorius | 38. pterygoideus | | | | | | | | | | | | | | | | | | | | | | | | | | | | | | | | | | | | | |
| | 39. mylohyoideus | 40. dentalis inferior | 41. mentalis | 42. Insertio chordae tympani | | | | | | | | | | | | | | | | | | | | | | | | | | | | | | | | | | | | | |
| | 43. plexus anserinus Bockii | 44. r. inferior meatus auditorii | 45. r. superior | 46. decursus | | | | | | | | | | | | | | | | | | | | | | | | | | | | | | | | | | | | | |
| 41. r. maxillaris inferior | <table border="0"> <tr> <td>47. maxillaris</td> <td>48. lingualis</td> <td>49. auricularis</td> </tr> <tr> <td>51. lingualis</td> <td>52. Insertio chordae tympani</td> <td>53. ganglion maxillare</td> </tr> <tr> <td>54. et 55. decursus</td> <td></td> <td></td> </tr> </table> | 47. maxillaris | 48. lingualis | 49. auricularis | 51. lingualis | 52. Insertio chordae tympani | 53. ganglion maxillare | 54. et 55. decursus | | | | | | | | | | | | | | | | | | | | | | | | | | | | | | | | | |
| 47. maxillaris | 48. lingualis | 49. auricularis | | | | | | | | | | | | | | | | | | | | | | | | | | | | | | | | | | | | | | | |
| 51. lingualis | 52. Insertio chordae tympani | 53. ganglion maxillare | | | | | | | | | | | | | | | | | | | | | | | | | | | | | | | | | | | | | | | |
| 54. et 55. decursus | | | | | | | | | | | | | | | | | | | | | | | | | | | | | | | | | | | | | | | | | |

Dreigetheilter Nerve

nach Meckel Bang, Bock und Wrisberg.

Fig. 1

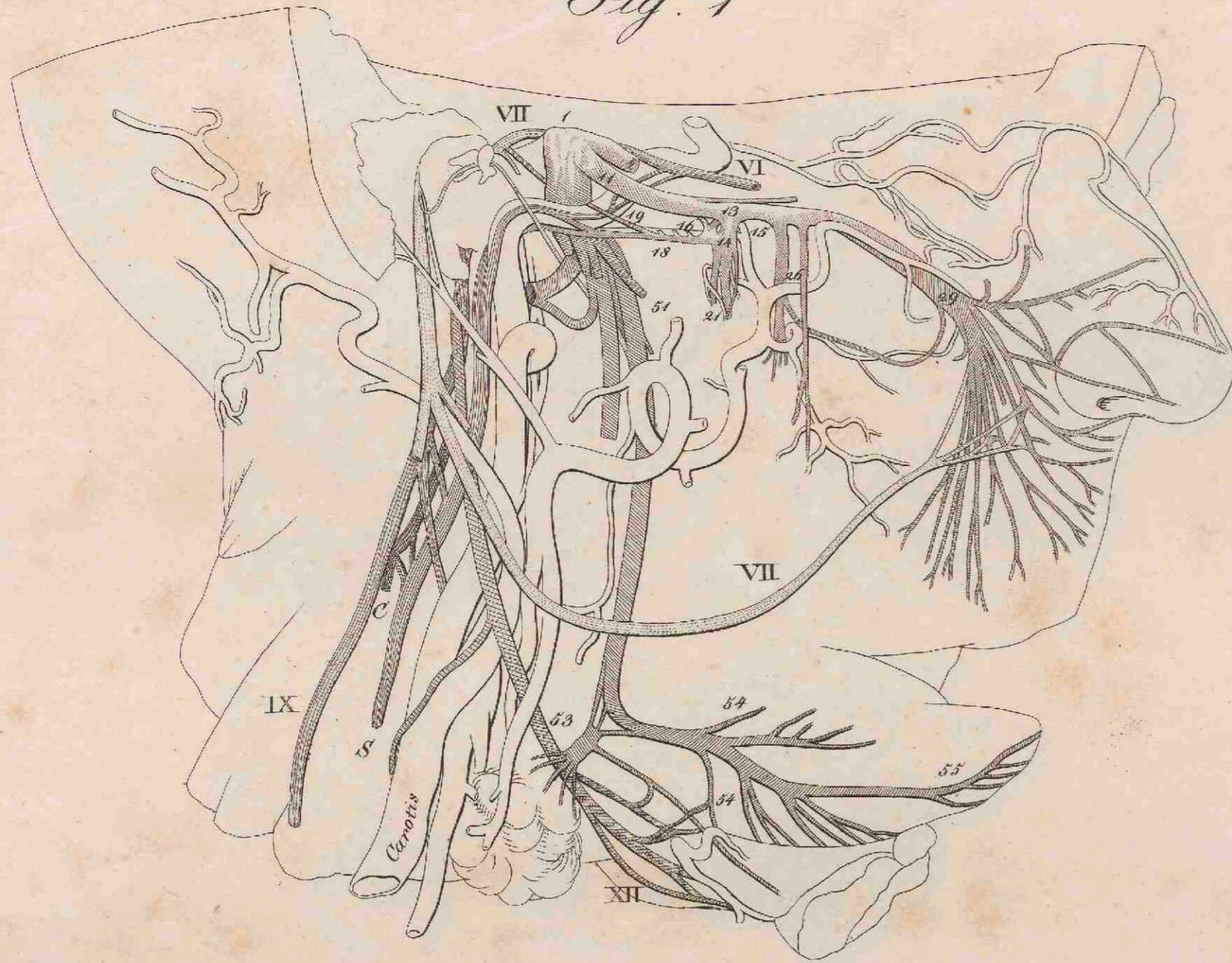

Fig. 2

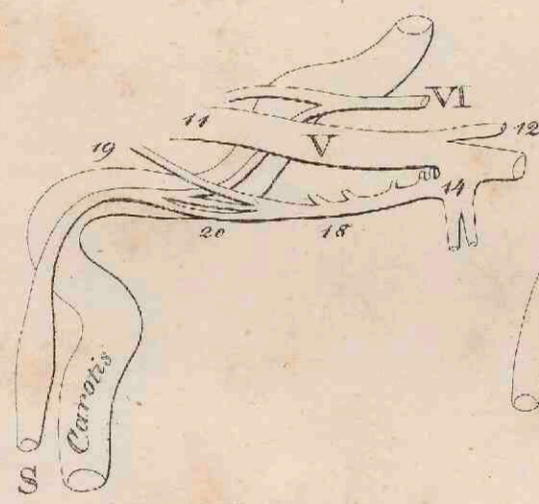


Fig. 3




Fig. 4

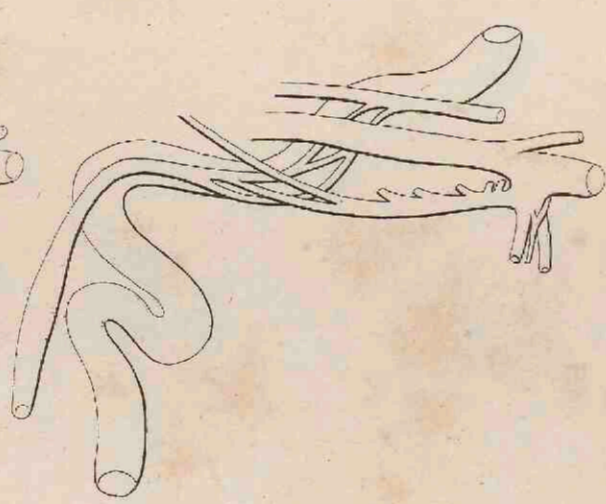


Fig. 5

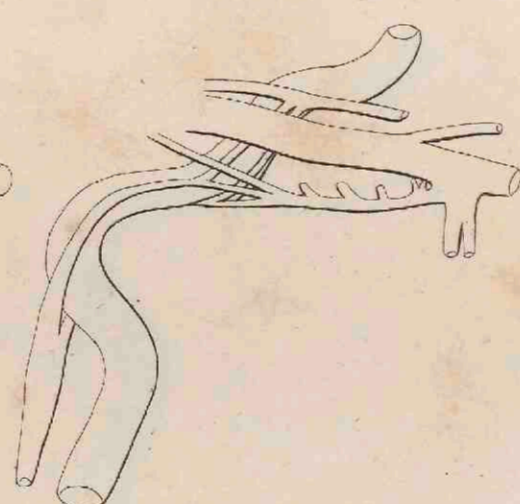


Fig. 6




Fig. 8

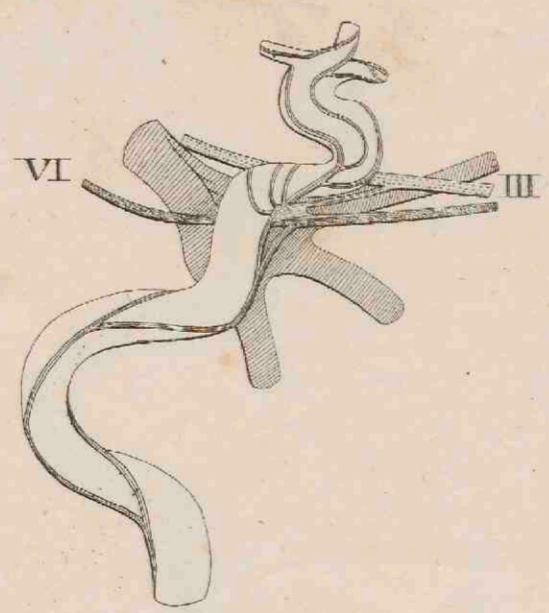


Fig. 7



Fig. 9

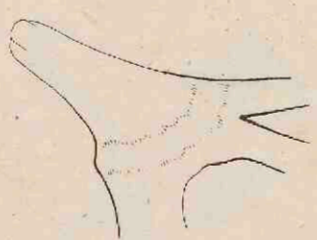


Fig. 10

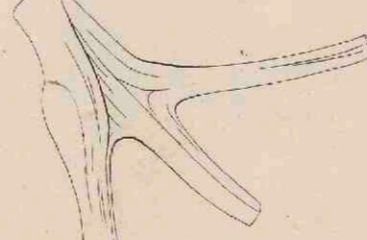


Fig. 12

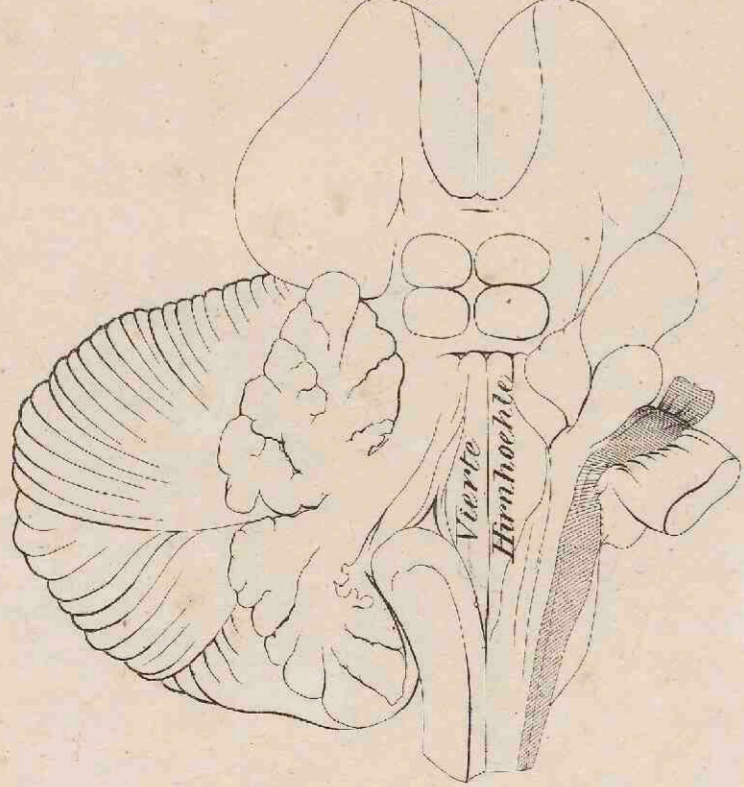


Fig. 11

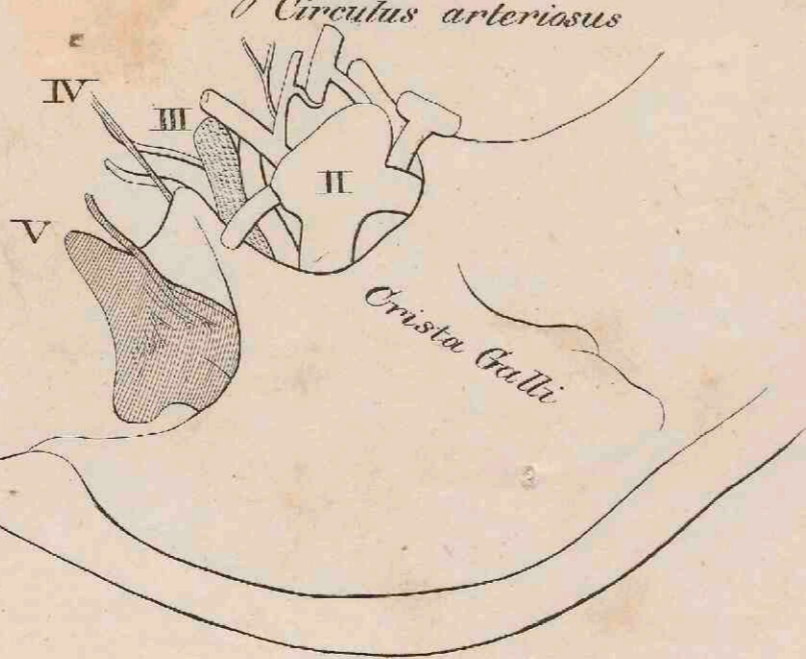


Fig. 13

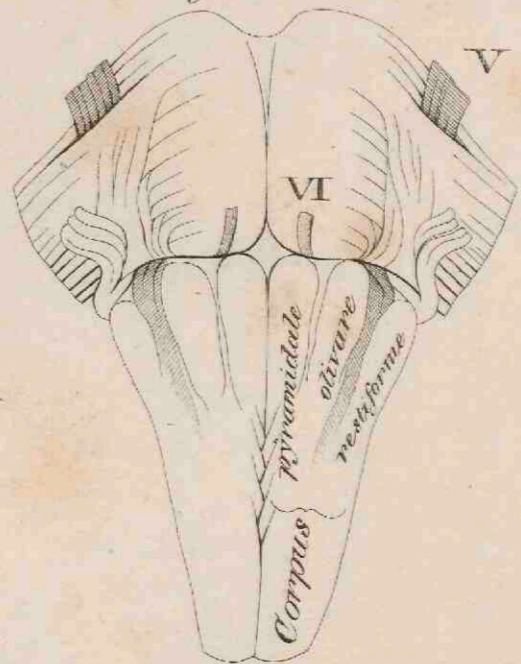
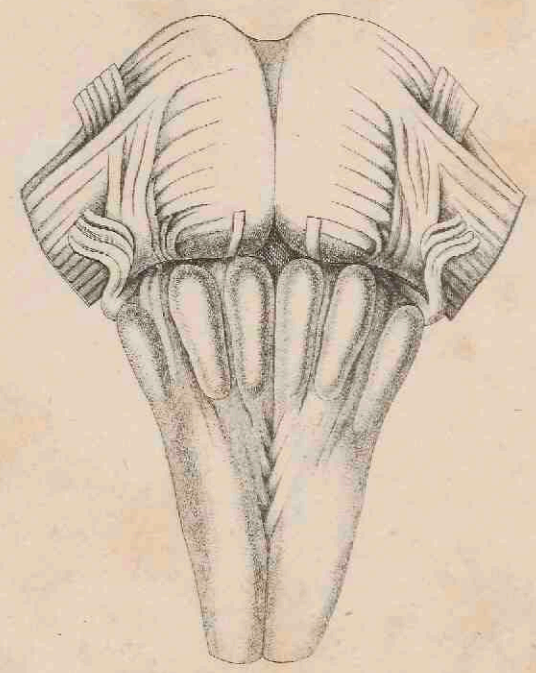
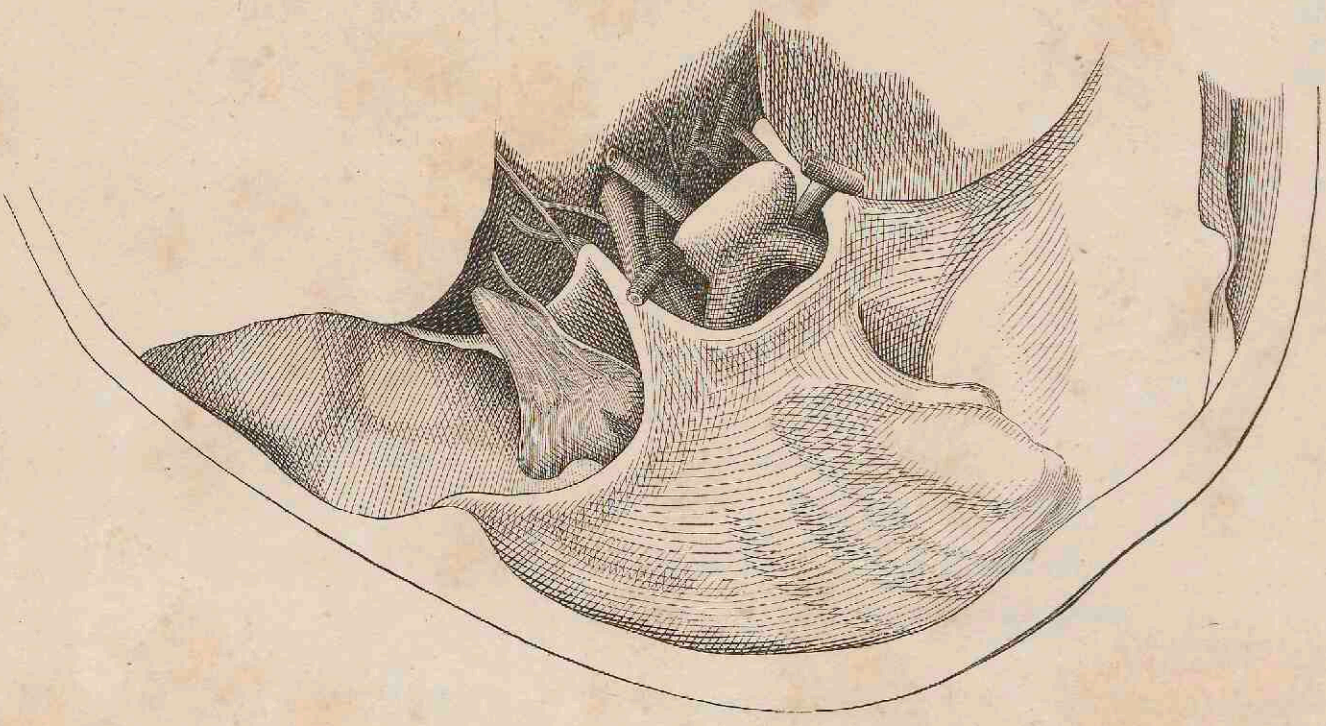
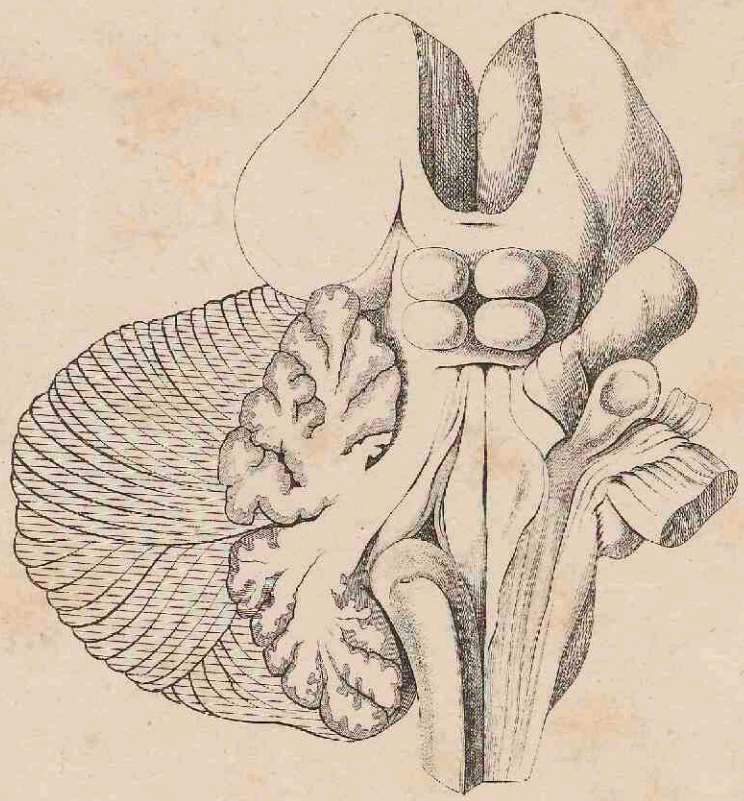
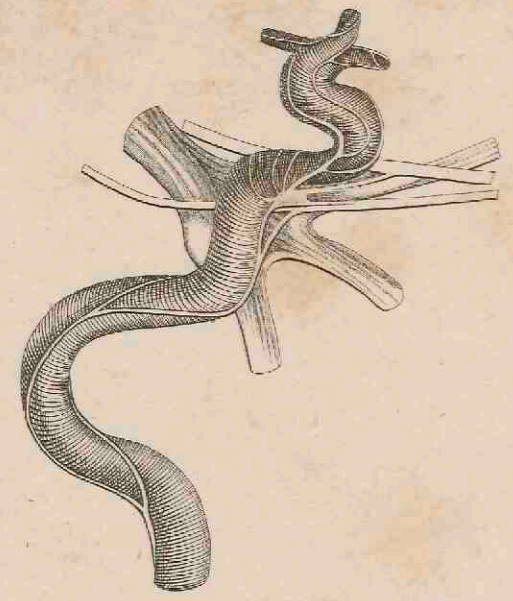
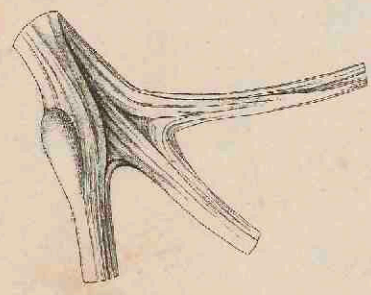
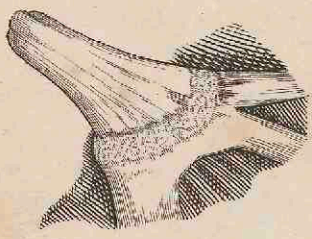
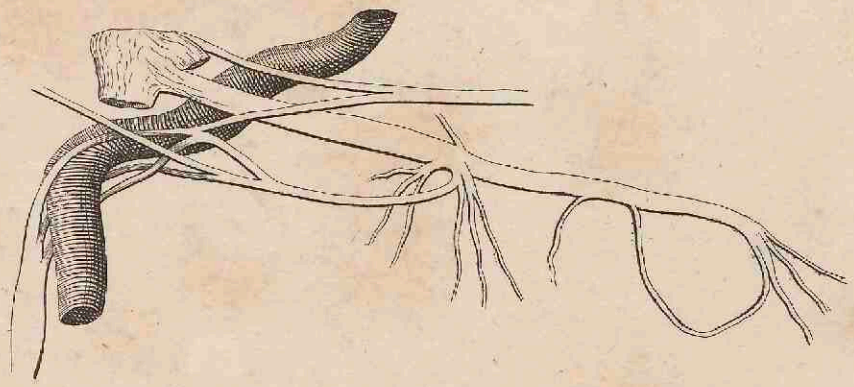

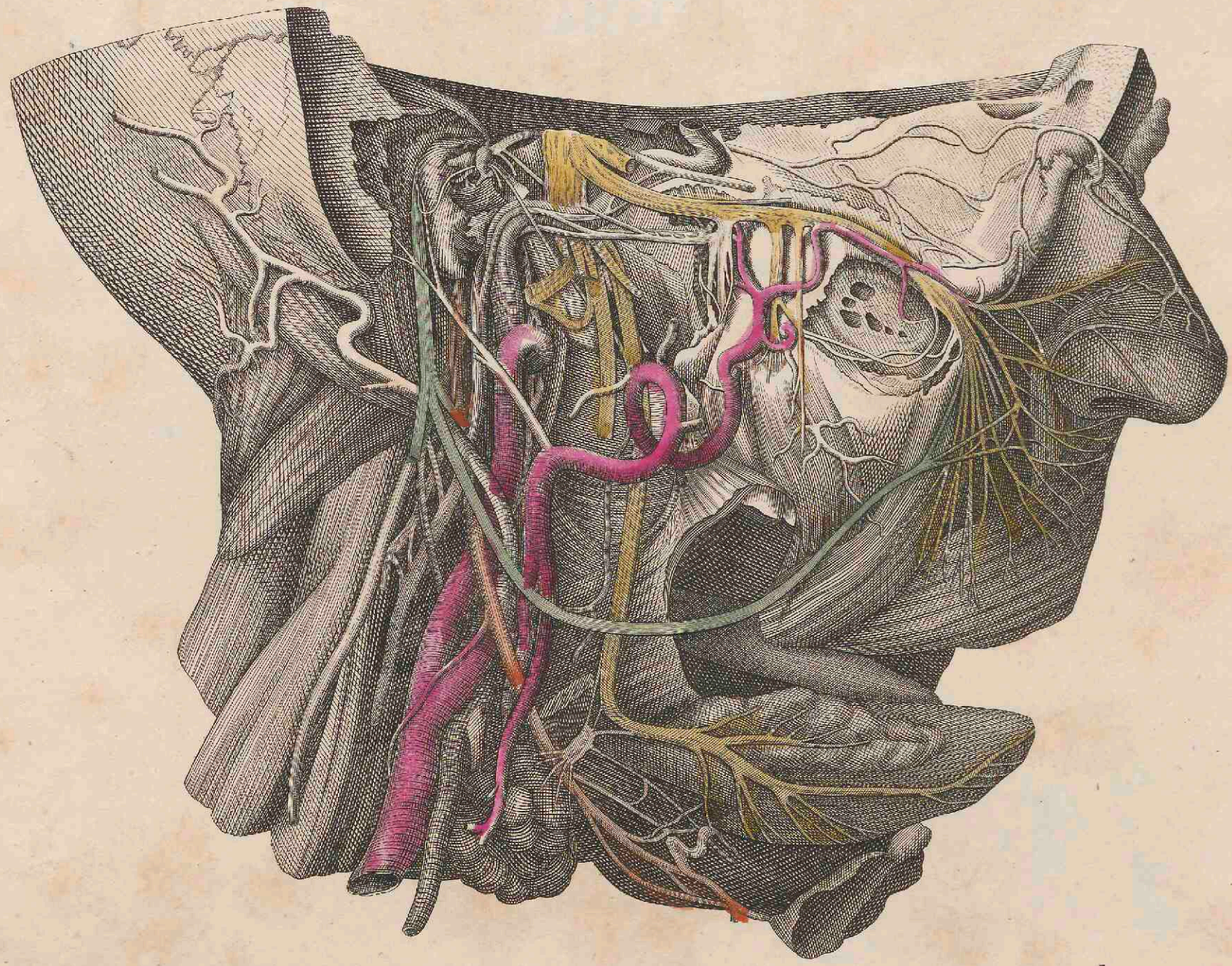


Fig. 1. Verlauf des Nerven. Fig. 2 - 8. Varietaeten seiner Verbindung mit dem sympathischen Nerven. Fig. 8. Dessen oberstes Ganglion nach Bock. Fig. 9. Ganglion Gasseri von oben, Fig. 10, von unten, Fig. 11, in seiner Lage betrachtet. Fig. 12. Das verlängerte Mark mit dem Ursprünge des Nerven, von oben, Fig. 13, von unten betrachtet.

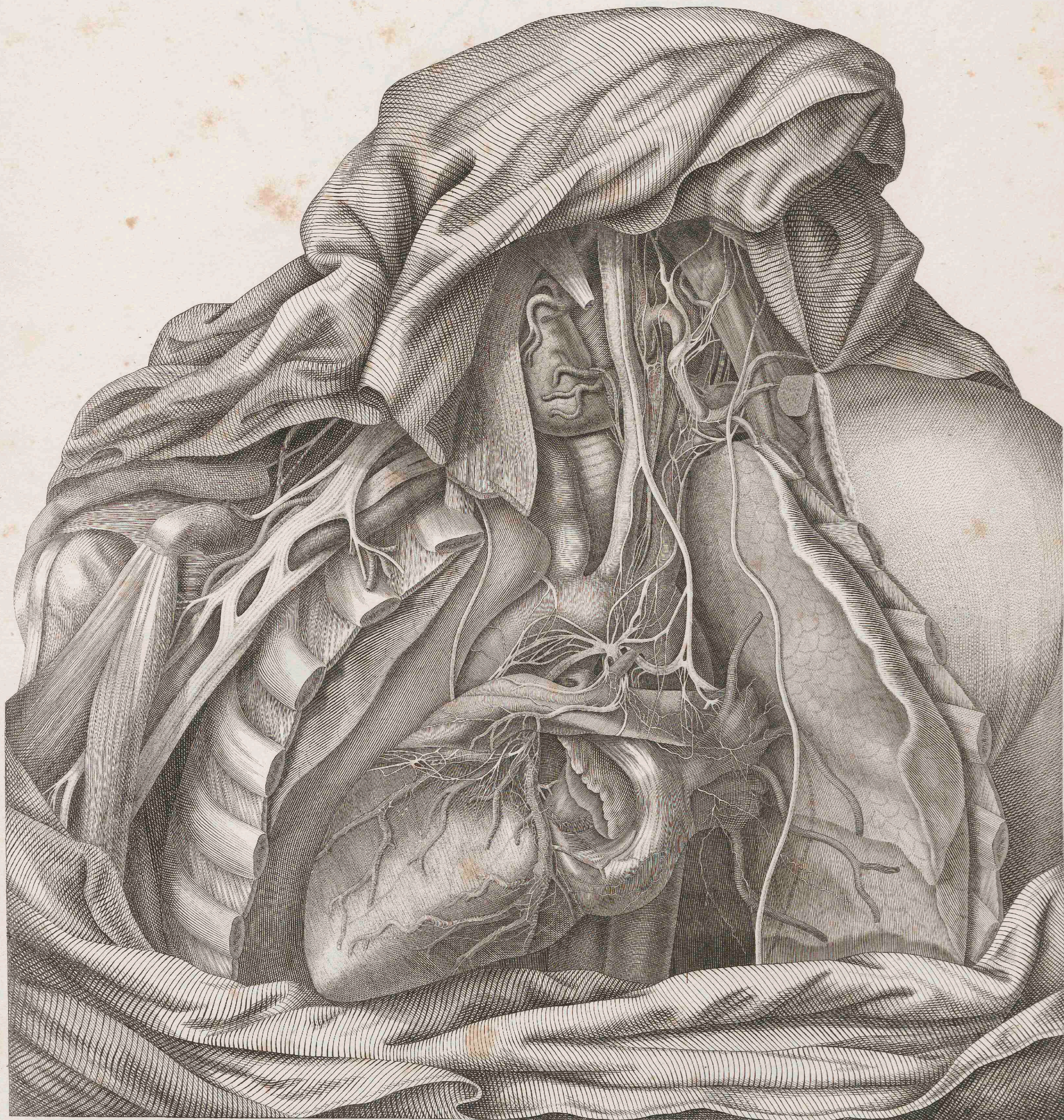


Herumschweifender und sympathischer Nerve

nach Scarpa

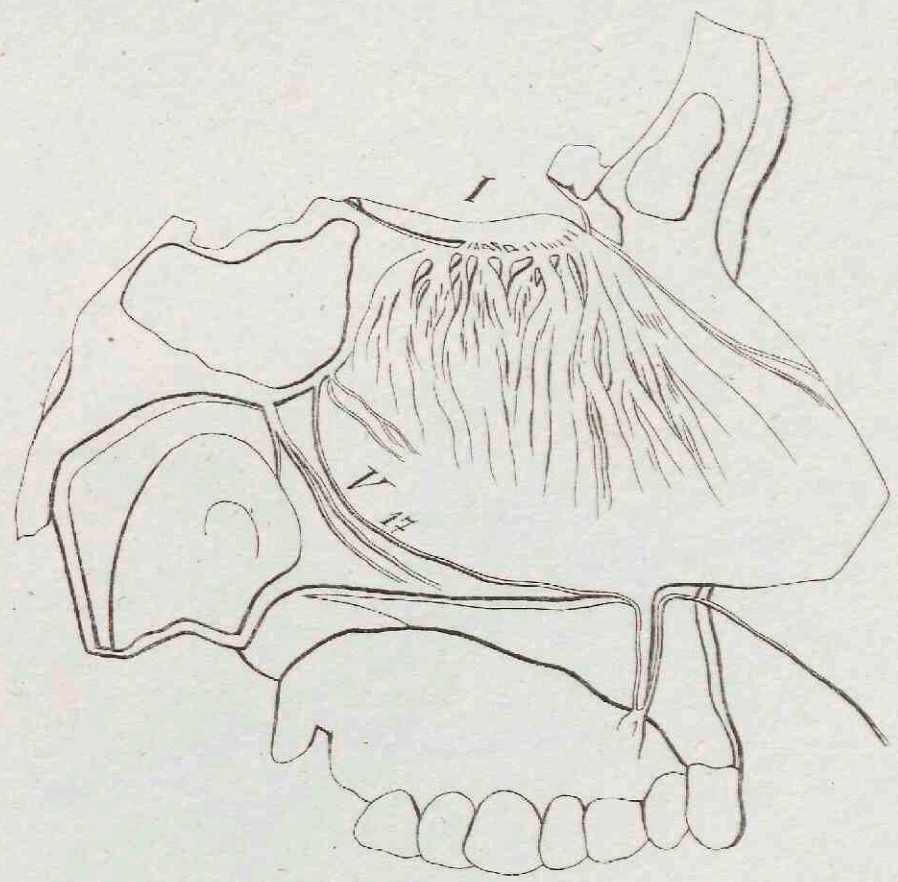
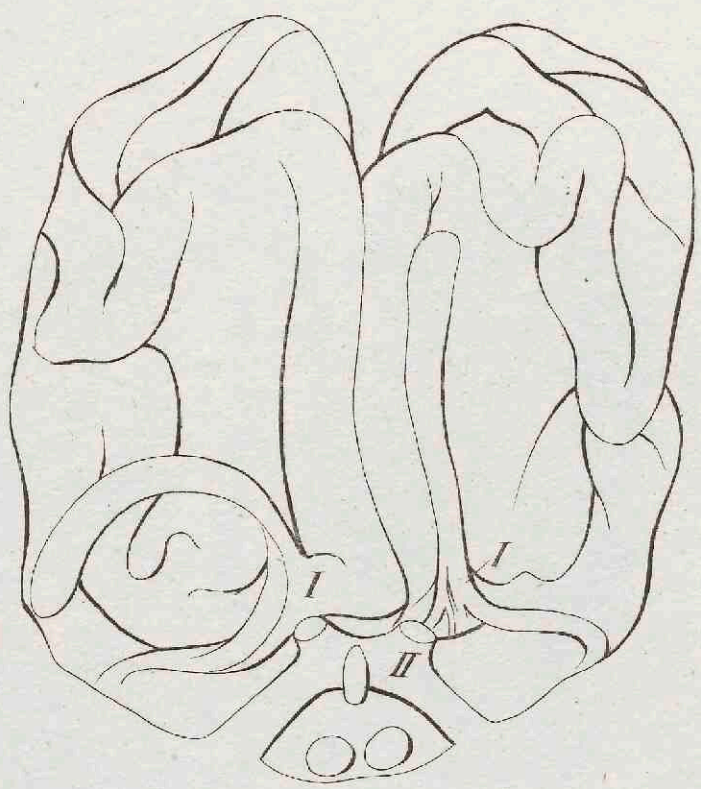
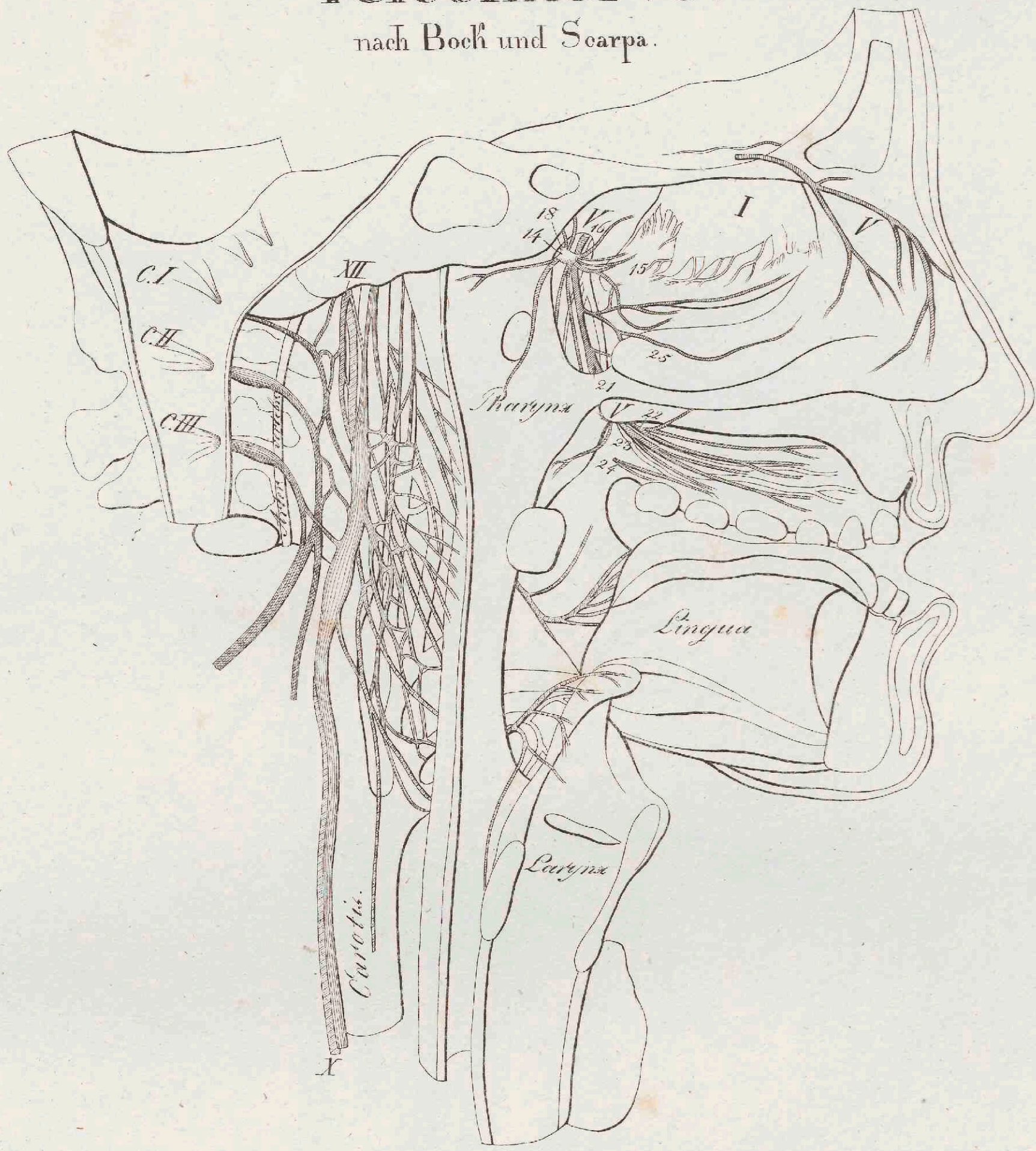

Vagus	a Pars thoracica	{	b ramus cardiacus	} 7 Plexus cardiacus
			c — laryngeus	
			d plexus pulmonalis	
			e ramus ad oesophagum	
1 Sympathicus	P. cervicalis	{	* Ganglion superius	} 8 Gangl. Wisbergii.
			2 — medium	
			3 — inferius	
			4 nervus cardiacus superficialis	}
			5 — — accessorius	
			6 — — profundus	



Riechnerve.

nach Boek und Scarpa.



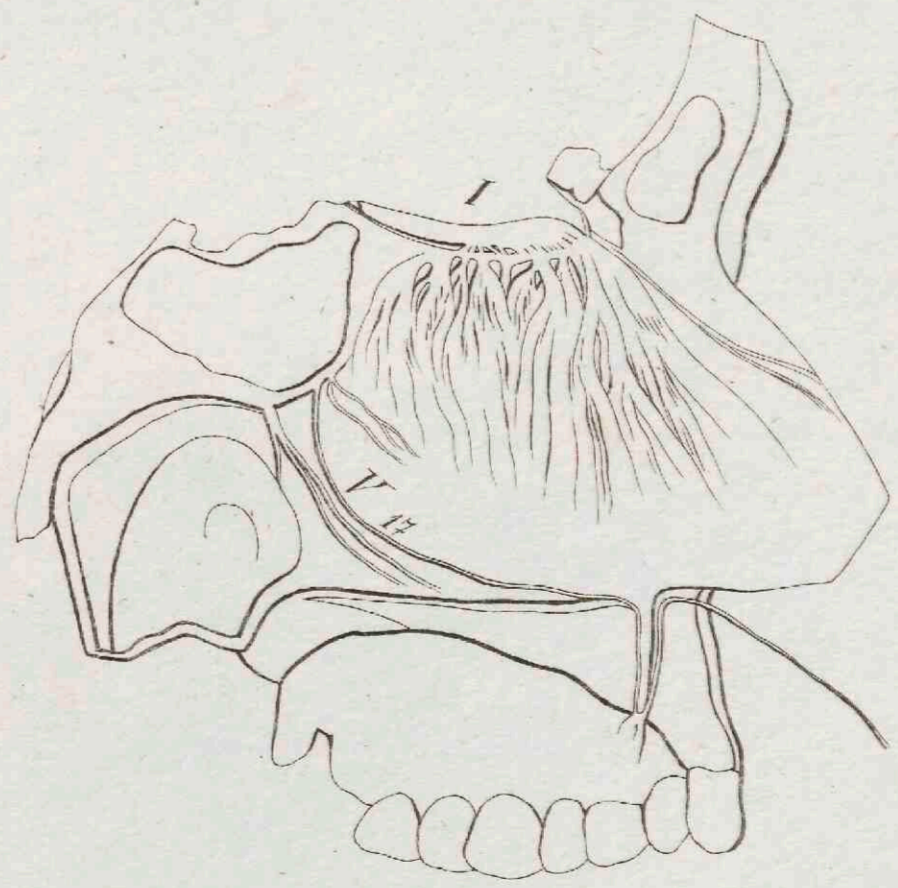
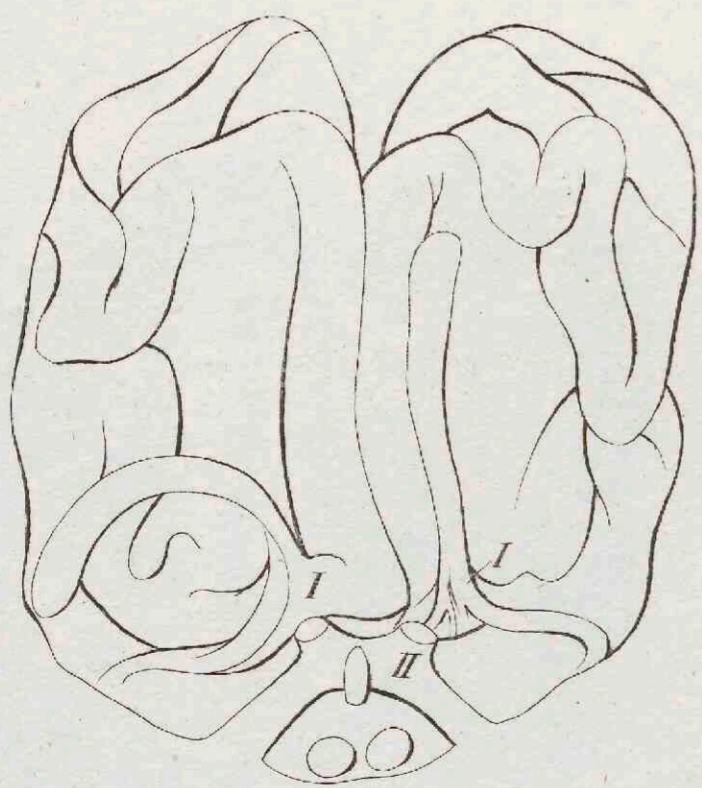
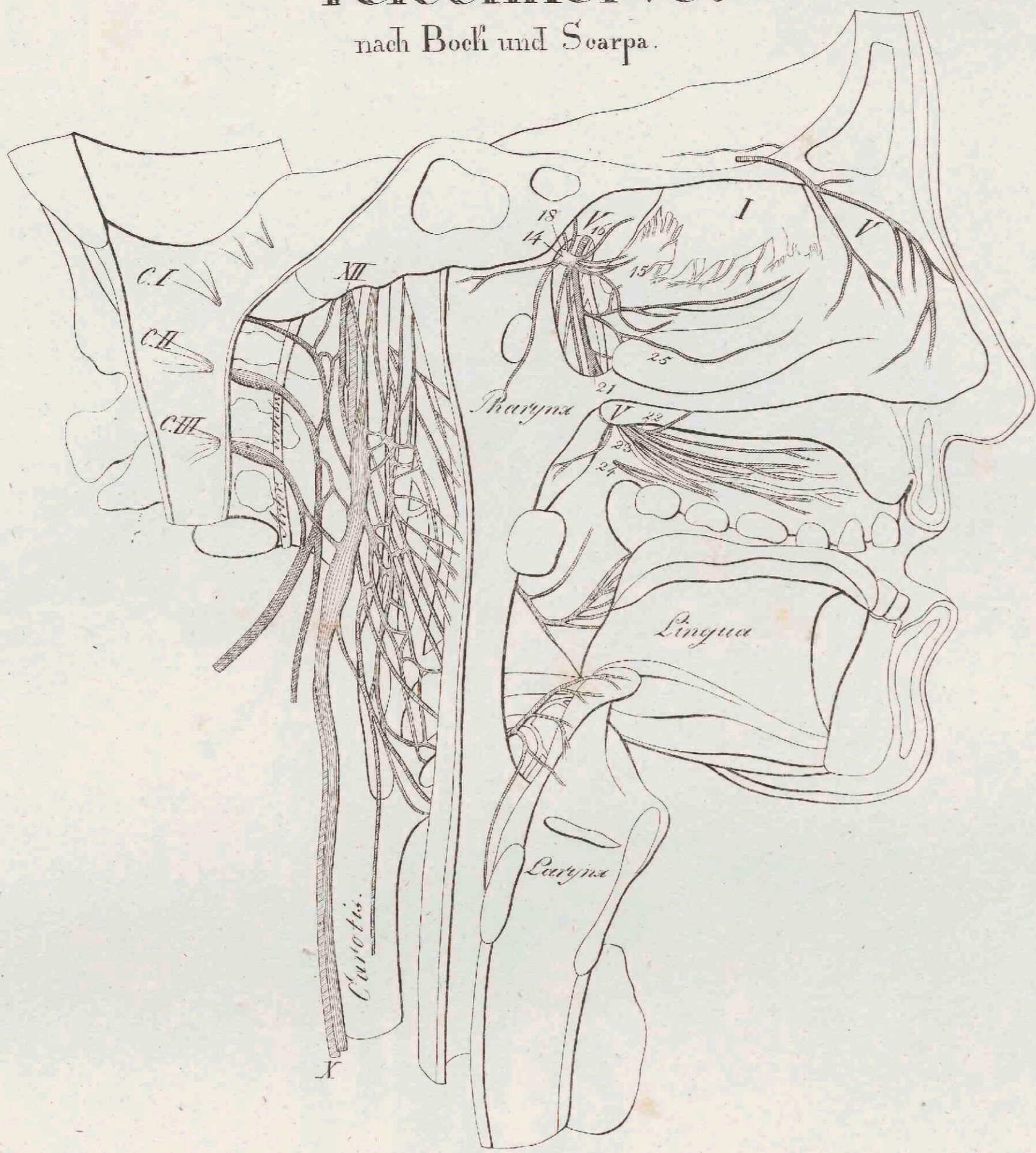
Der Riechnerve entspringt mit drei Wurzeln aus der Grundfläche des vorderen Lappens des großen Gehirns, wird dann dreieckig, und schwülzt hierauf in ein länglichtundes Ganglion an, aus dessen unterer Fläche unzählige Ästchen entspringen, deren innere größere, auf der Scheidewand der Nase, deren äußere kleinere aber auf der oberen und mittleren Muschel verlaufen.

Die römischen Zahlen beziehen sich auf die Nervengänge, die arabischen auf das Schema des dreigetheilten Nerven.

Boeck'sche Zeichnung.

Riechnerve.

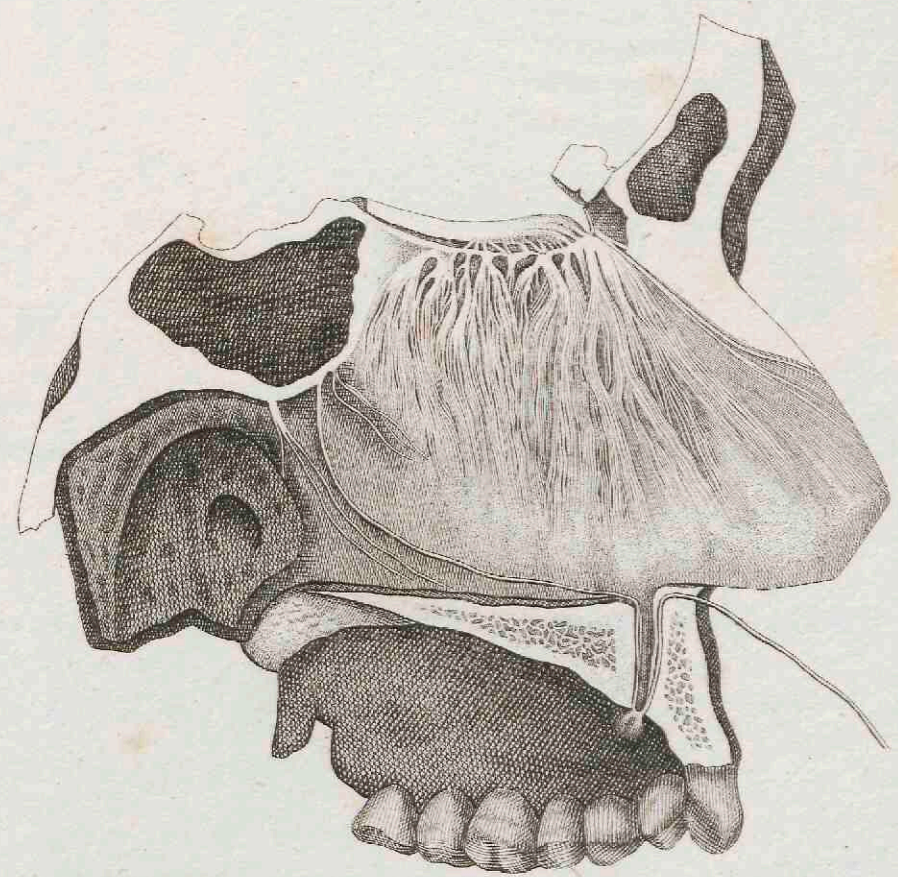
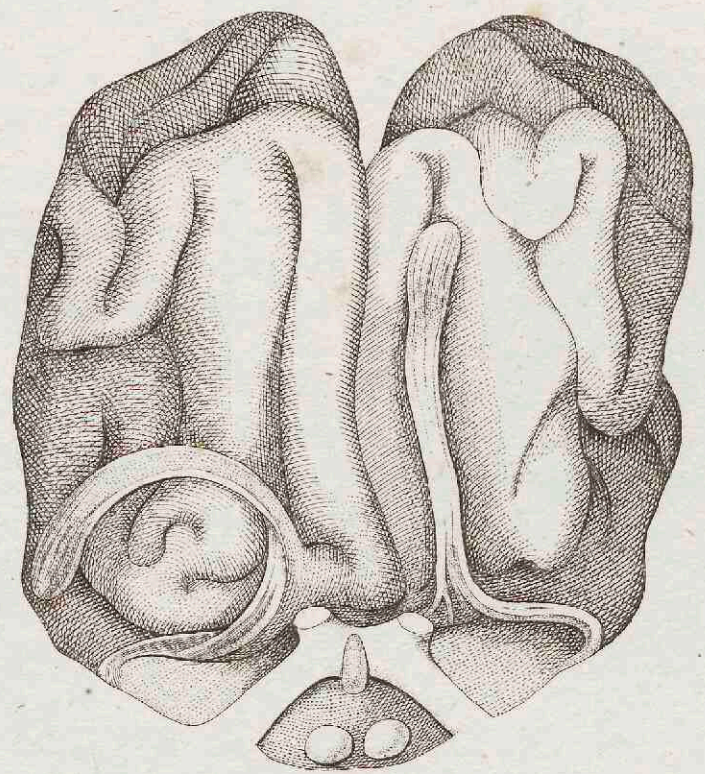
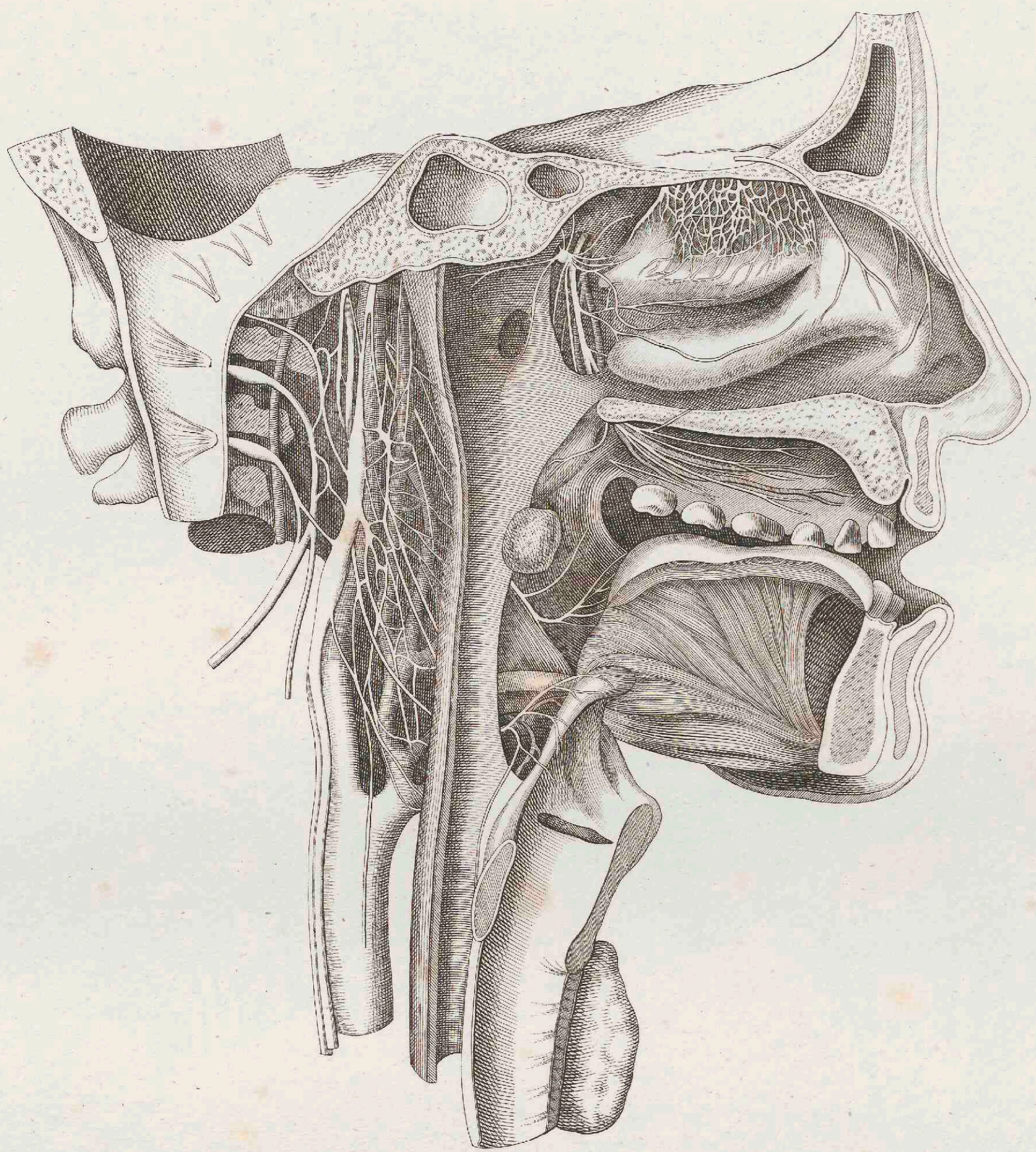
nach Boek und Scarpa.



Der Riechnerve entspringt mit drei Wurzeln aus der Grundfläche des vorderen Lappens des großen Gehirns, wird dann dreieckig, und schwillt hierauf in ein länglich-rundes Ganglion an, aus dessen unterer Fläche unzählige Ästchen entspringen, deren innere größer, auf der Scheidewand der Nase, deren äußere kleiner aber auf der oberen und mittleren Muschel verlaufen.


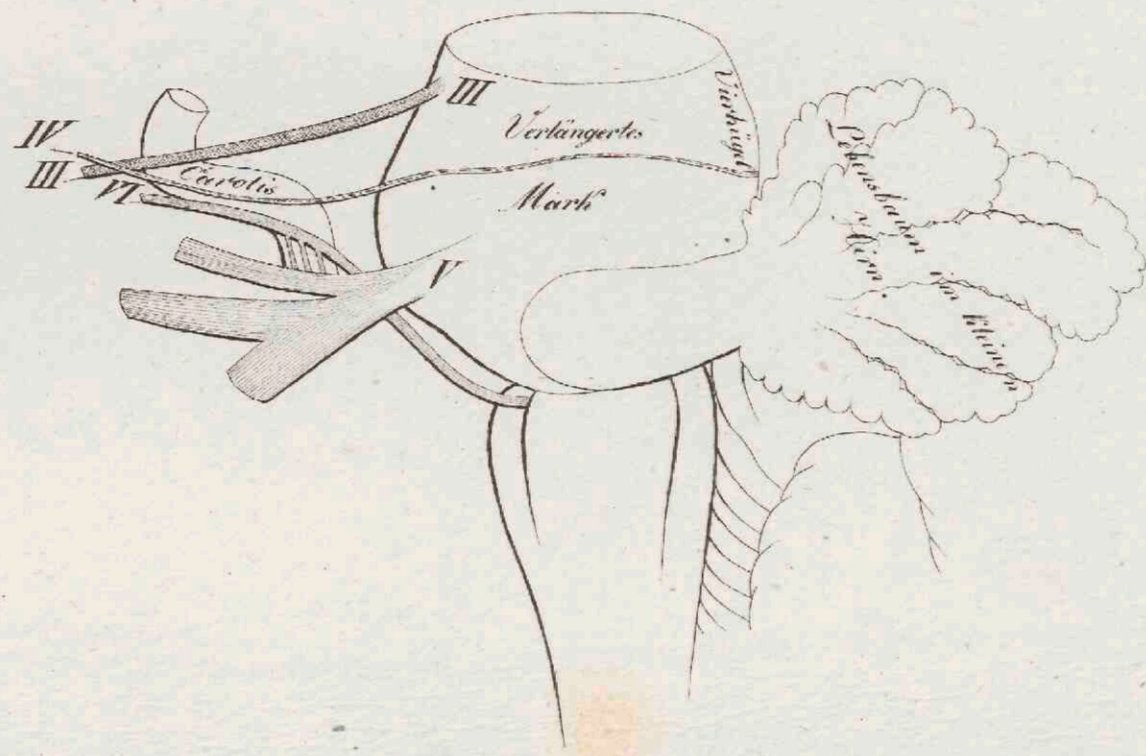
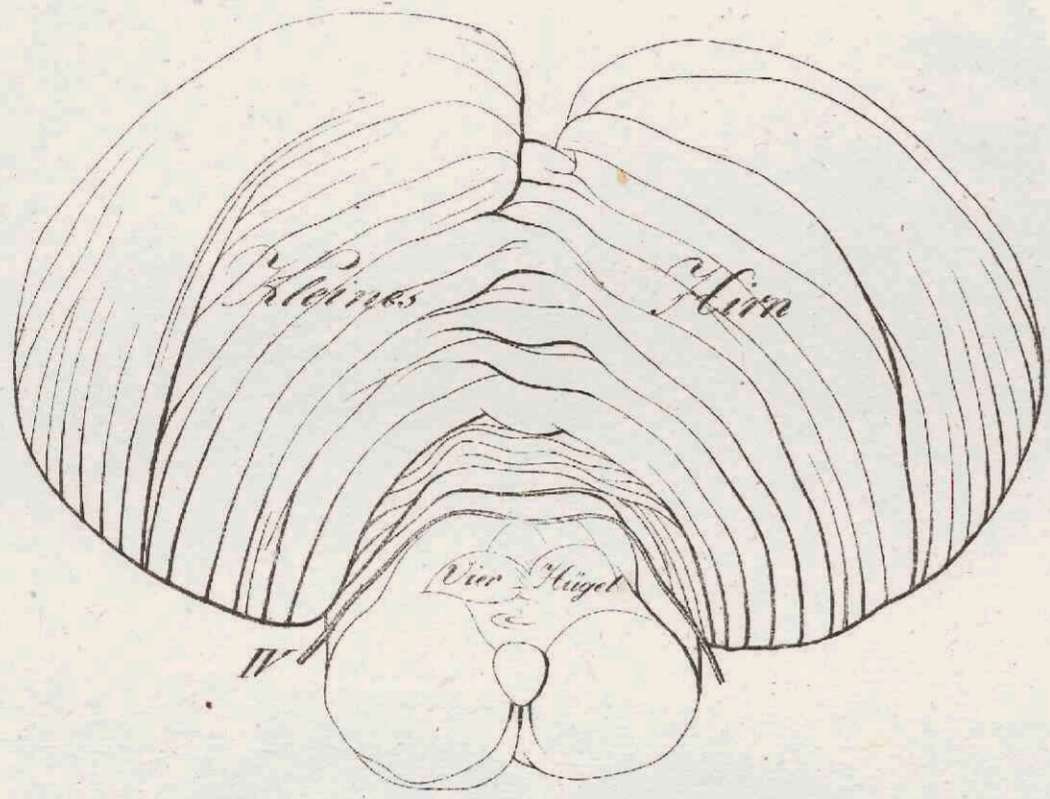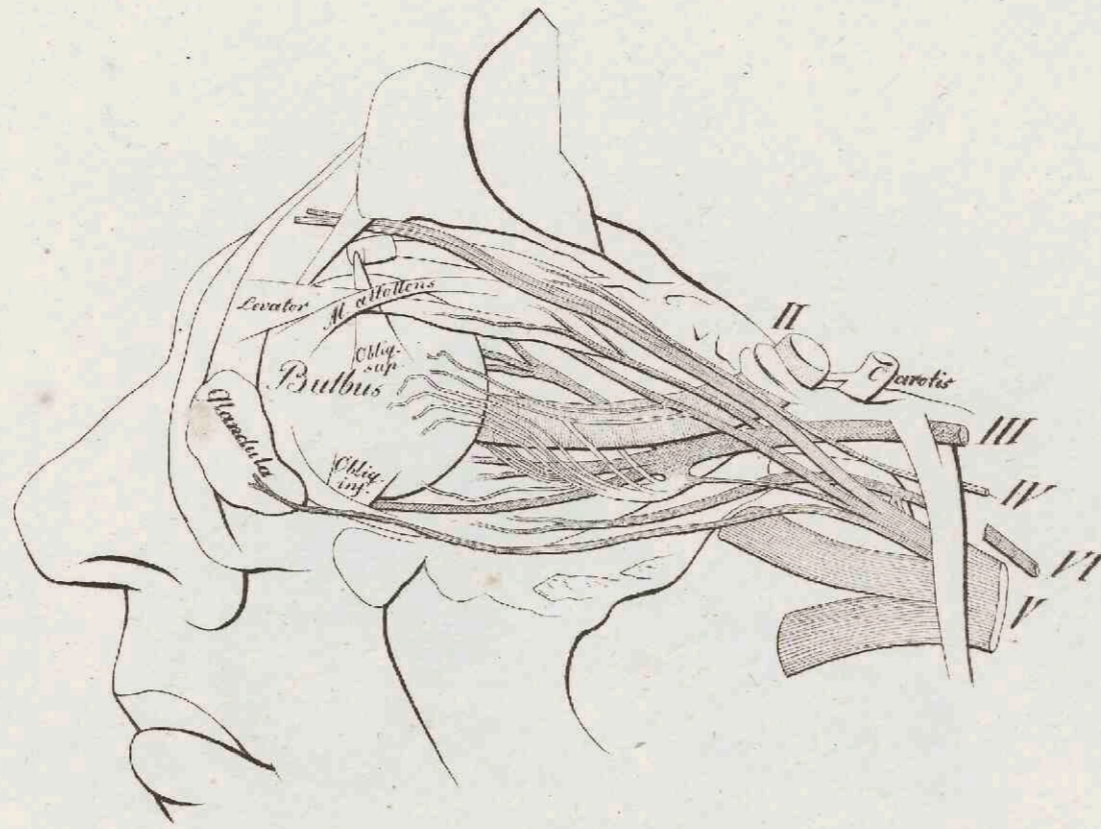
Die römischen Zahlen beziehen sich auf die Nervenzweige, die arabischen auf das Schema des dreigetheilten Nerven.

Boeck und Scarpa 1782

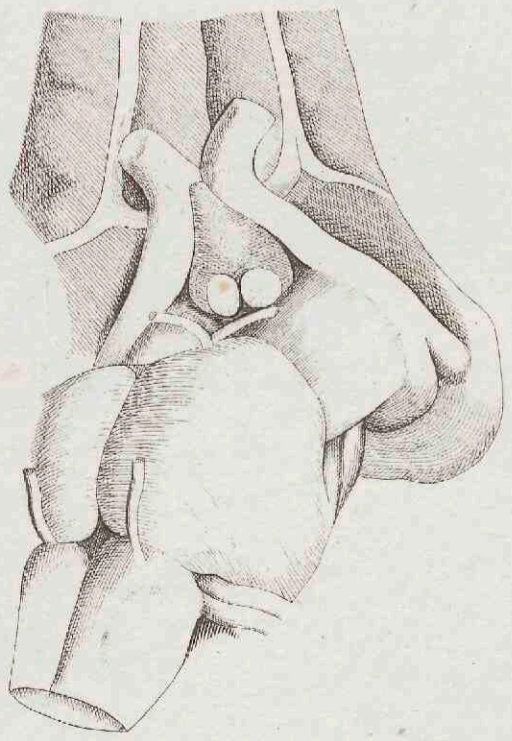
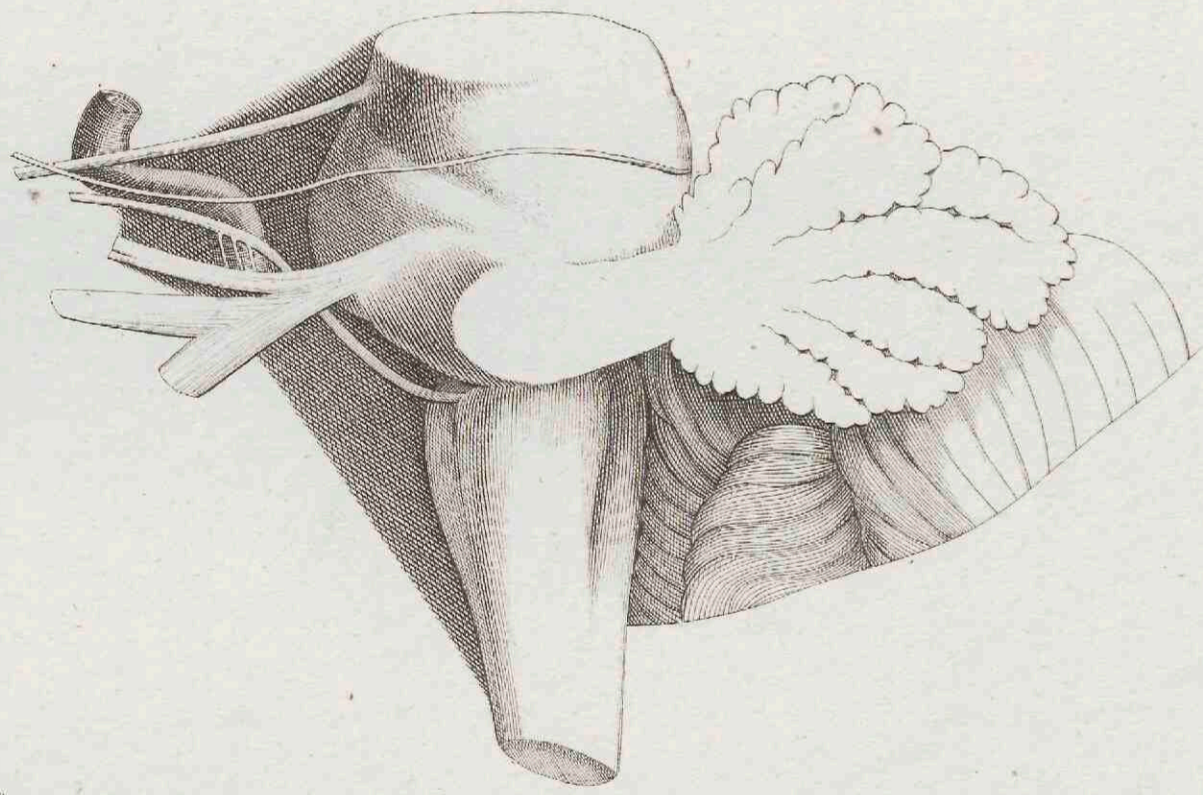
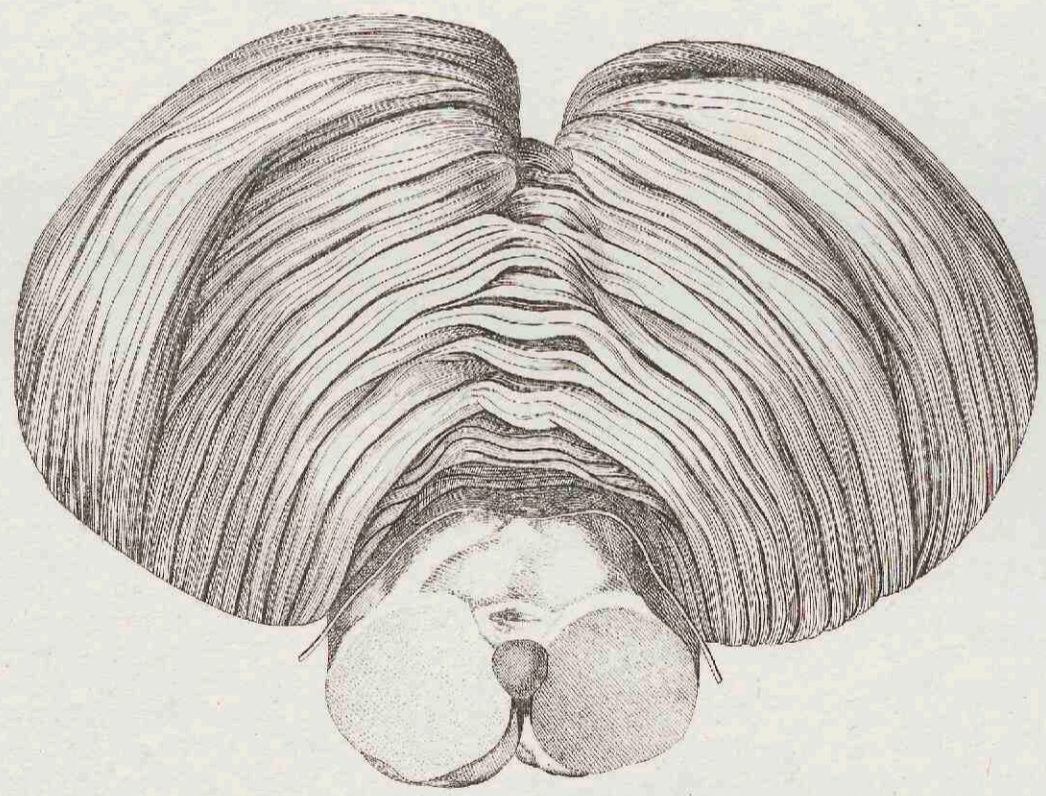
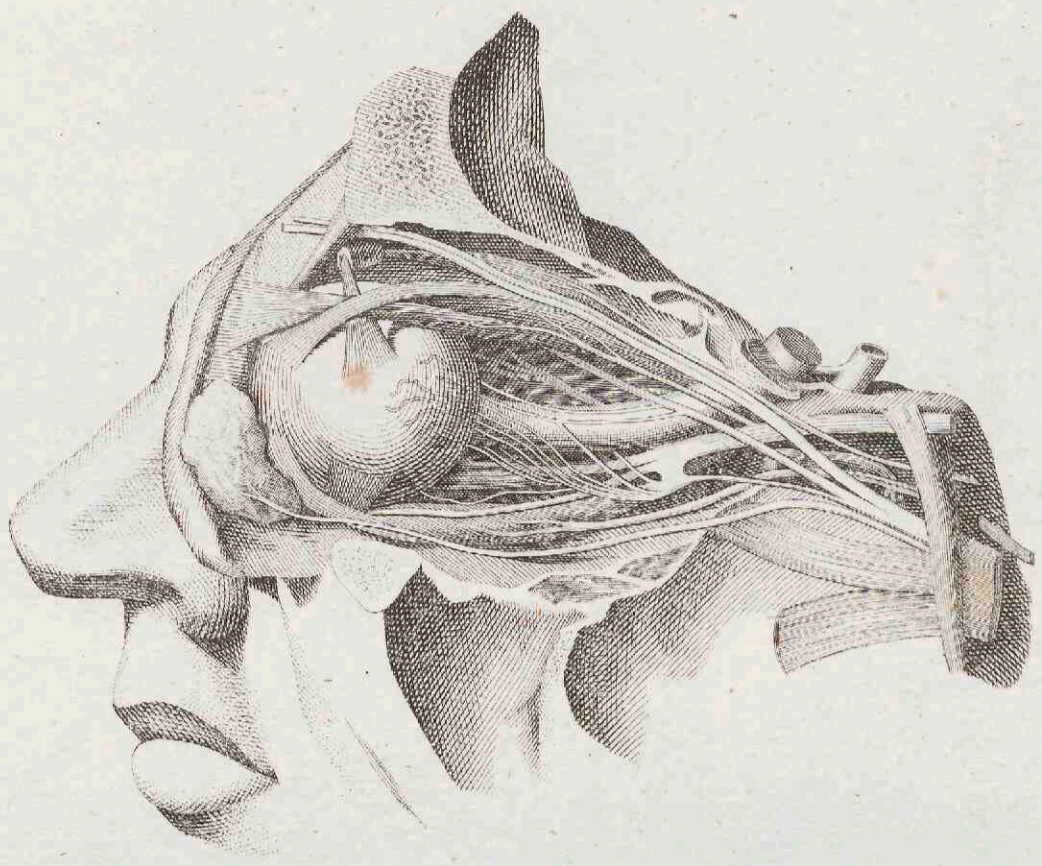


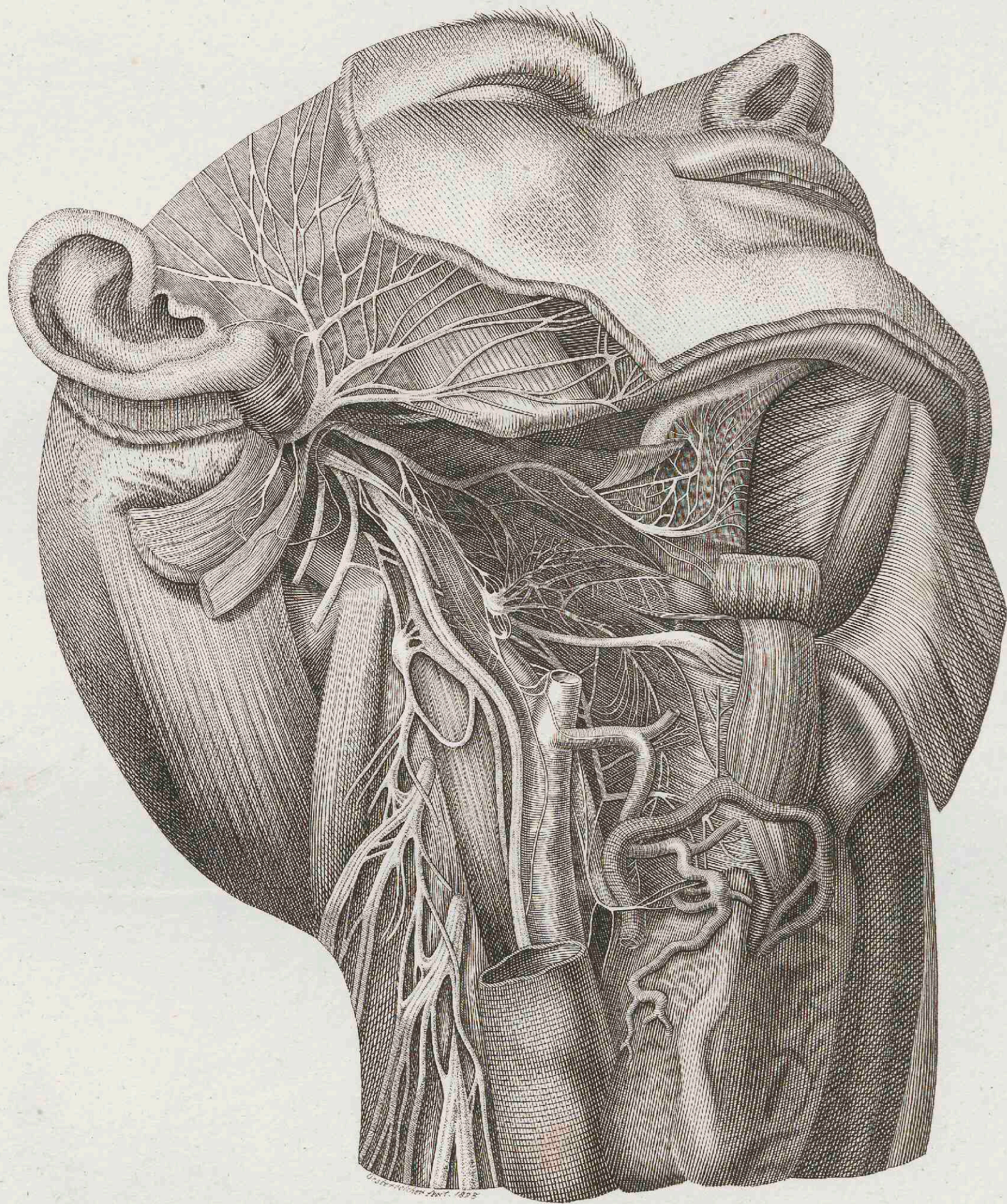Augenhöhlnerven,

nach Cloquet, Reil, Santorini und Zinn.



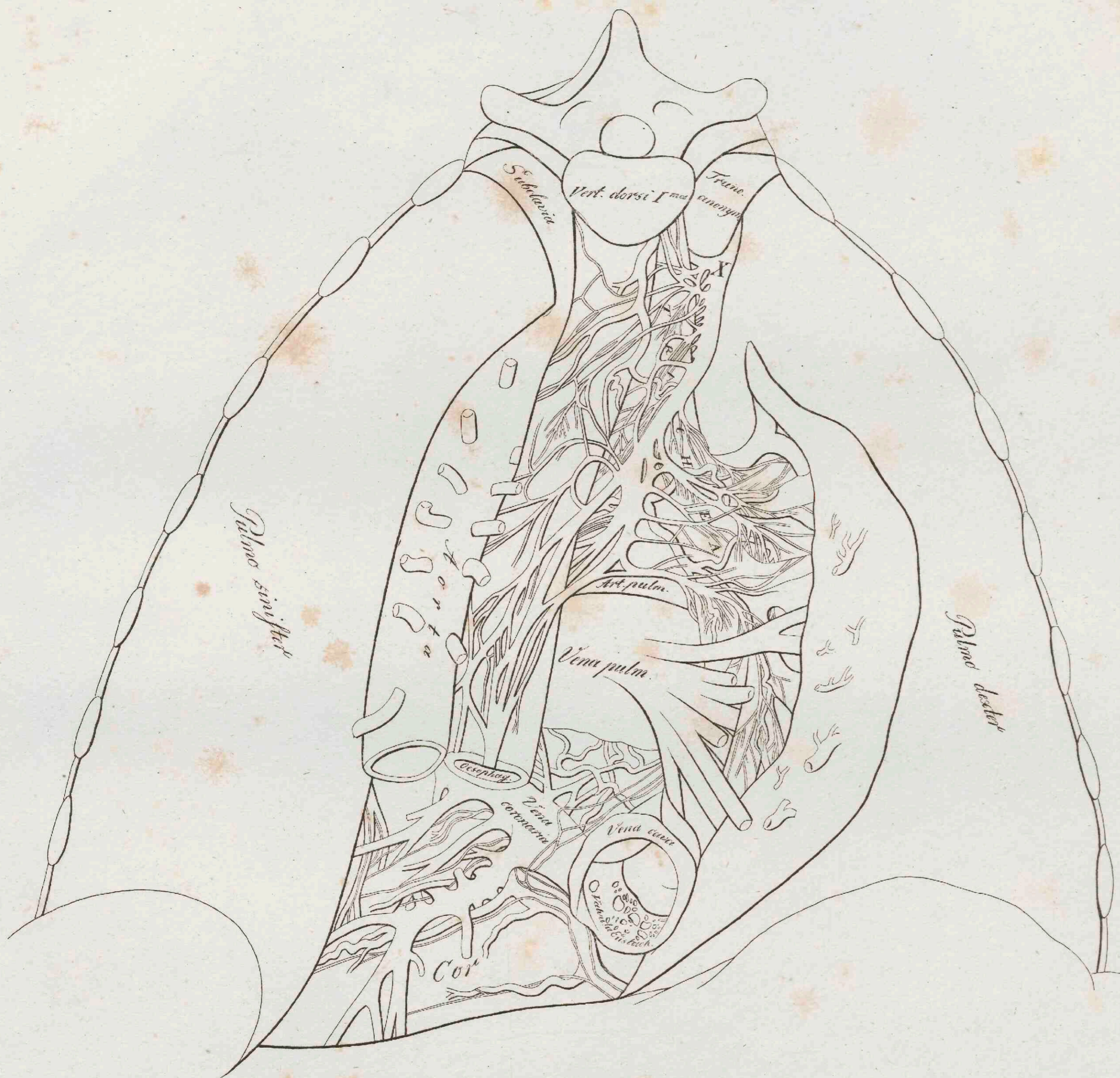- II. N. opticus, der Sehnerv, entspringt im Kerne des Gehirns, und kömmt, indem er sich um den Hirnschenkel herumschlägt, zur Basis des Gehirns, wo beide Nerven sich kreuzen. Dann gehen sie auswärts durch die Augenhöhle in den Augapfel. (S. Auge).
- III. oculomotorius, der gemeinschaftliche Augenmuskelnerv, kömmt aus dem Hirnschenkel hervor, und theilt sich in zwei Äste, deren oberer in die Musc. altollens und levator palpebrae, der untere in den adducens, depressans u. obliquus inf. sich verzweigt, auch kömmt aus ihm die kurze Wurzel des Gangl. ophthalm. hervor.
- IV. trochlearis, s. patheticus, der obere Augenmuskelnerv, entspringt hinter den Vierhügeln aus der Hirnbläube, und geht in den Musculus obliquus superior.
- V. trigeminus, (S. Nervent. den dreigetheilten Nerven.)
- VI. abducens, der äußere Augenmuskelnerv, entspringt zwischen den Oliven und Pyramiden, aus dem verlängerten Marke, und geht in den Musculus abducens.



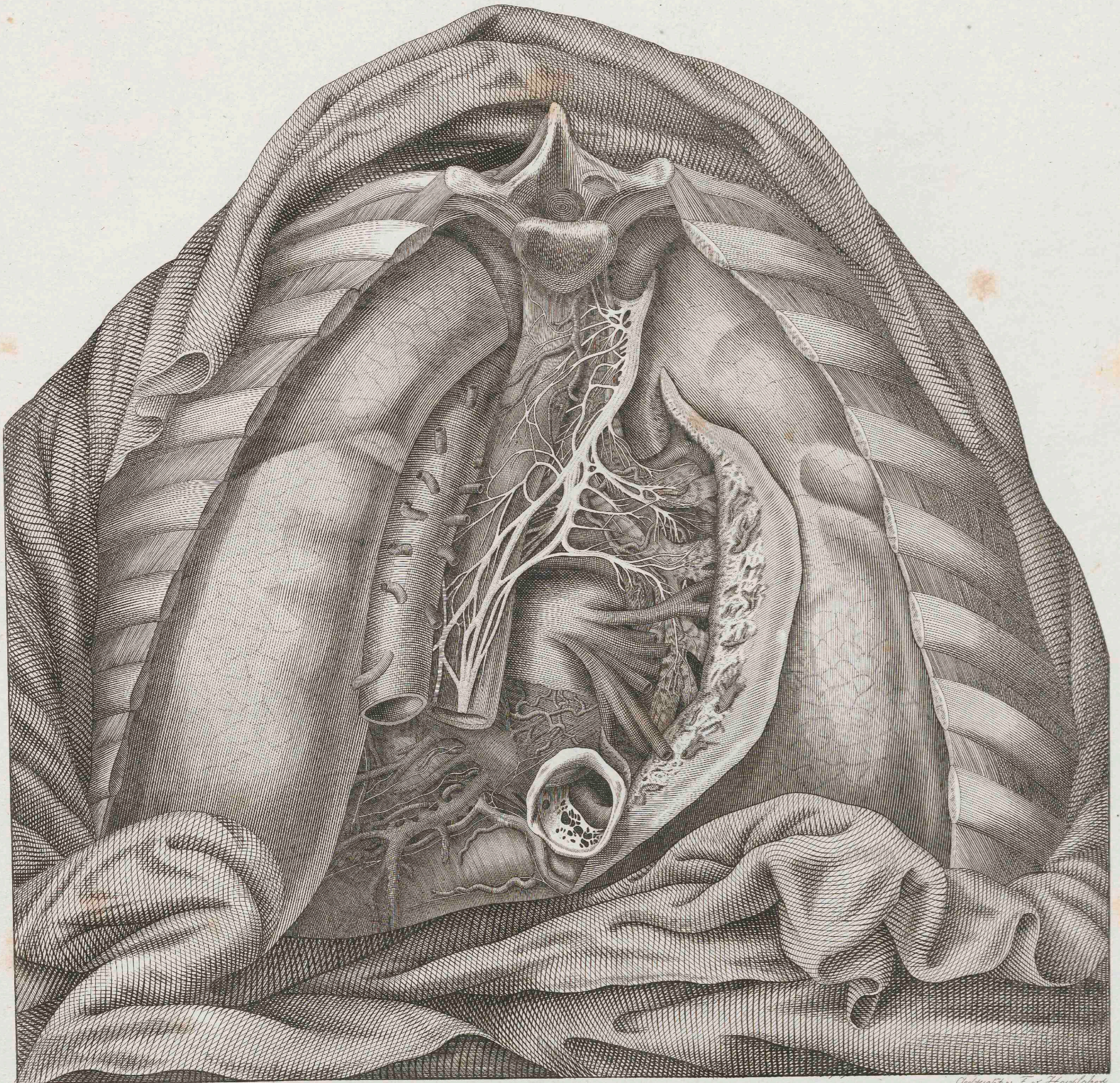


Herumschweifender Nerve.

nach A. Scarpa.



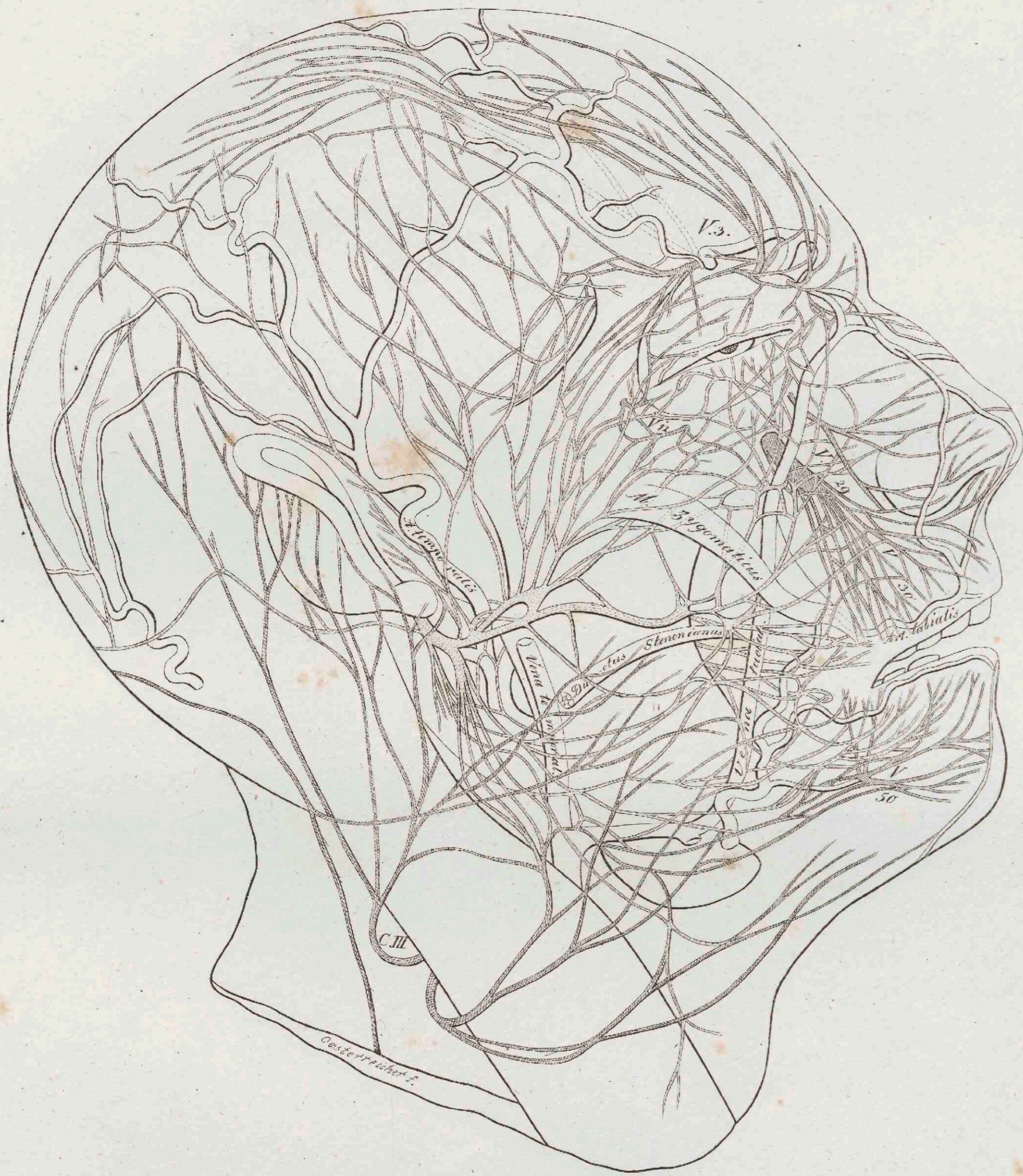
Nervi vagi plexus pulmonalis posterior et oesophageus.



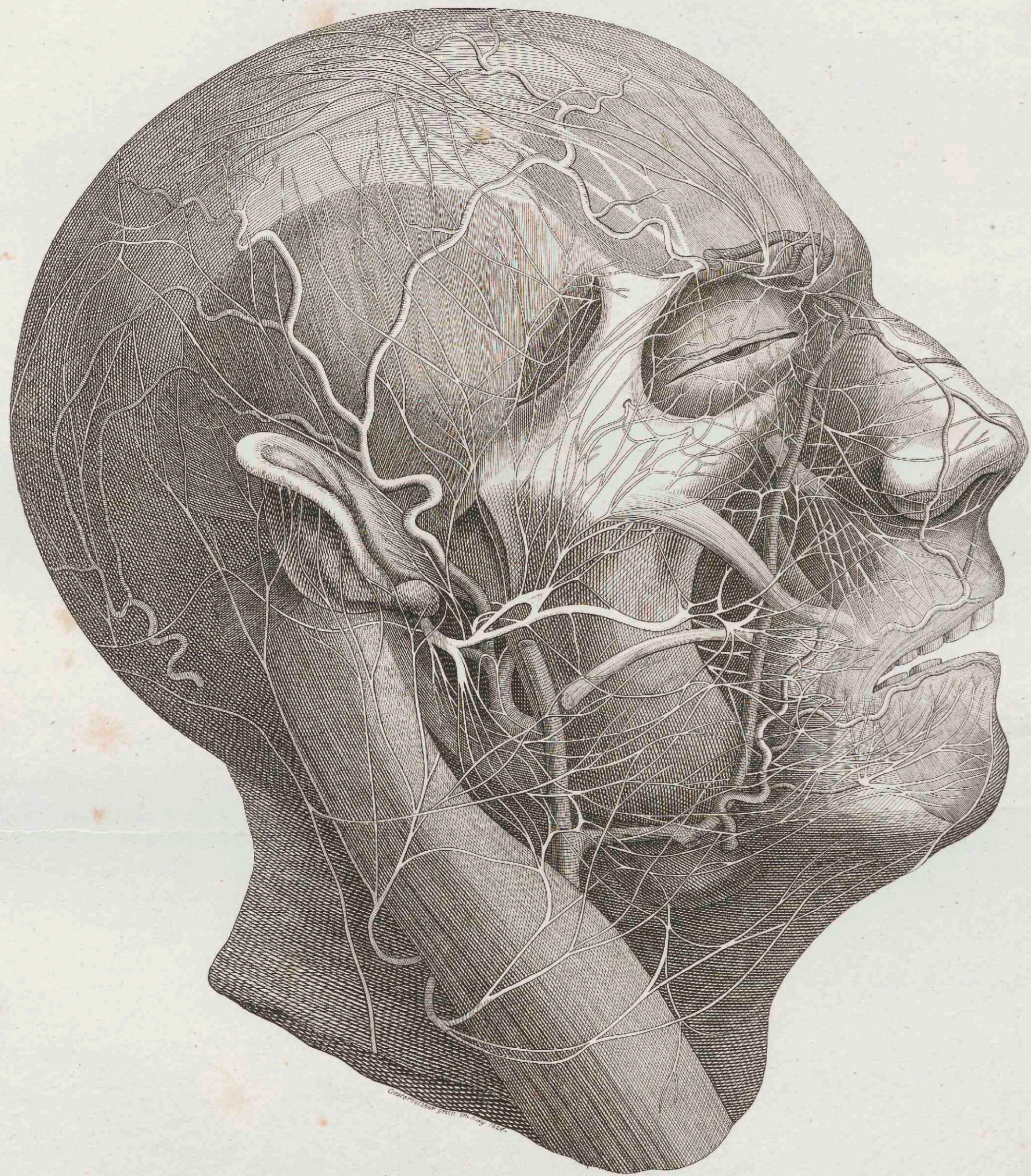
Gravirt v. Oesterreicher, im Juny 1828.

Gravirt v. F. v. Harscher.

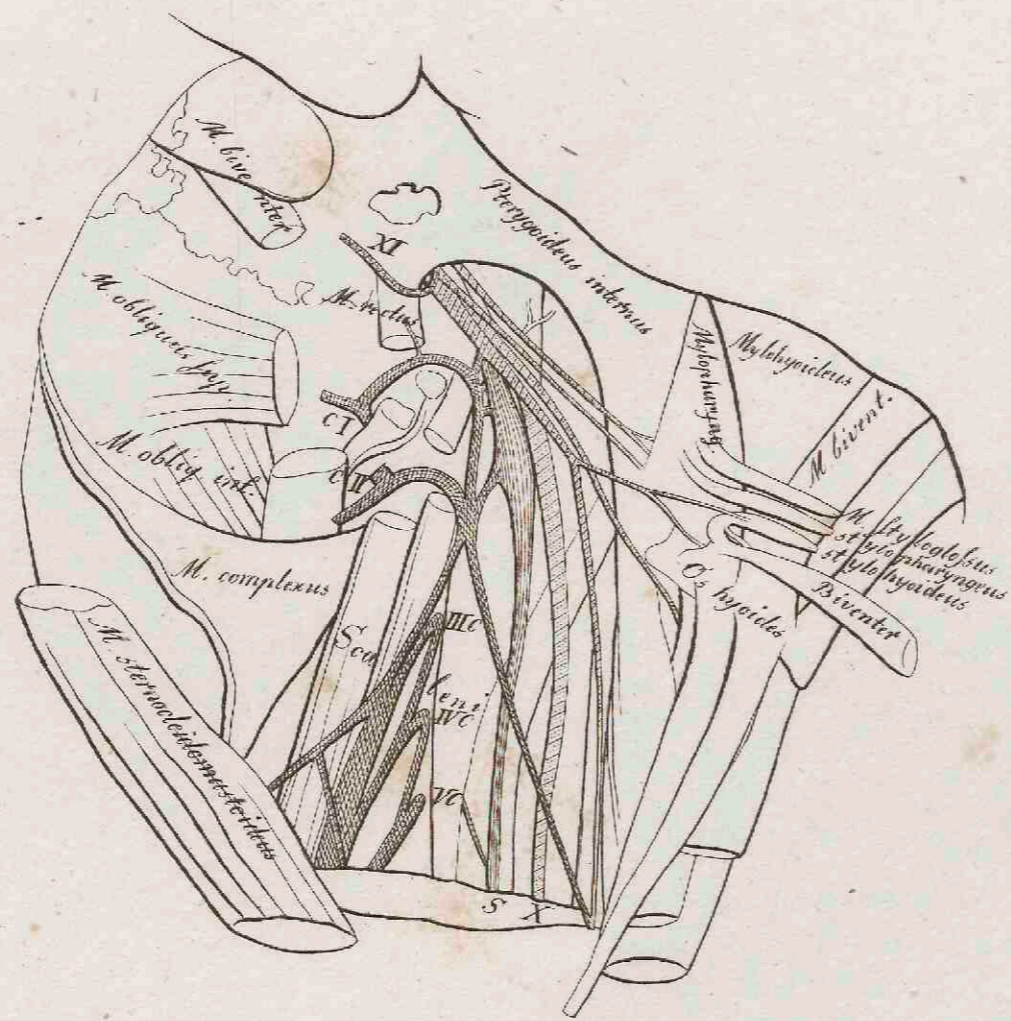

Antlitznerve
nach Meckel d.ä.



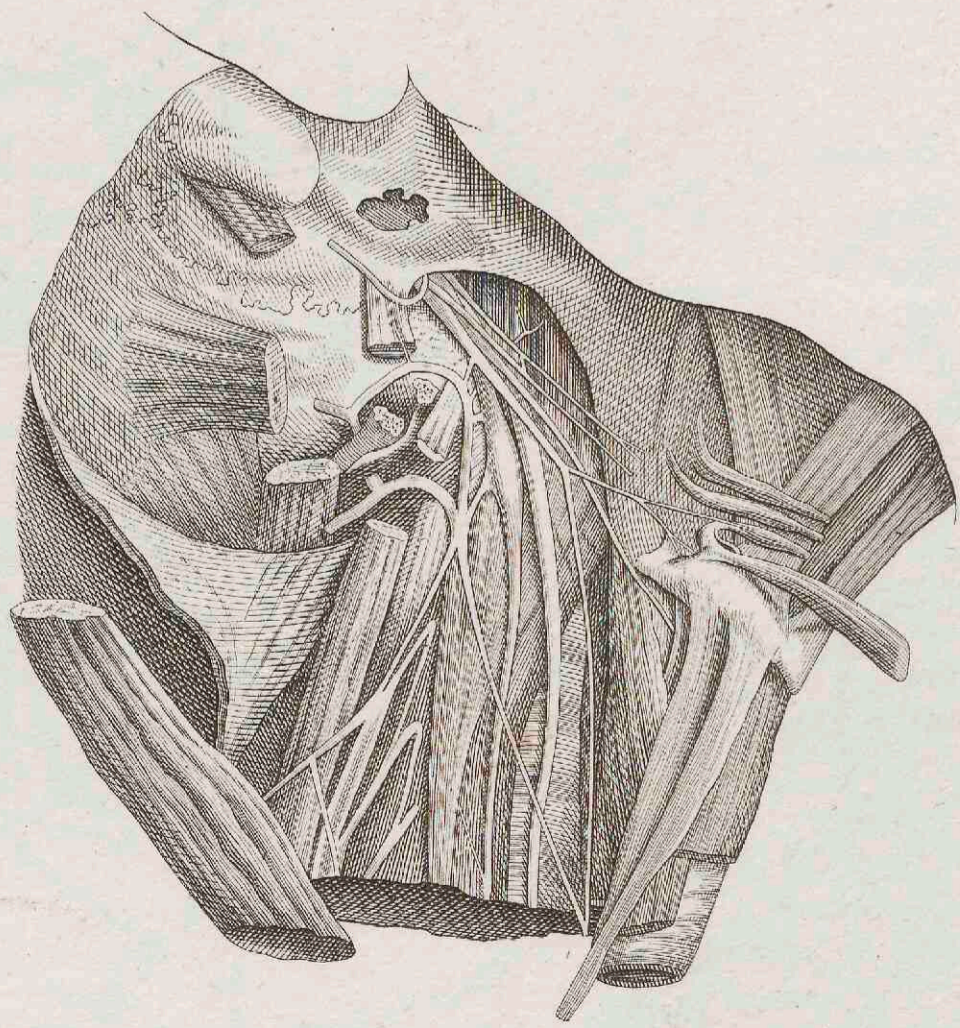
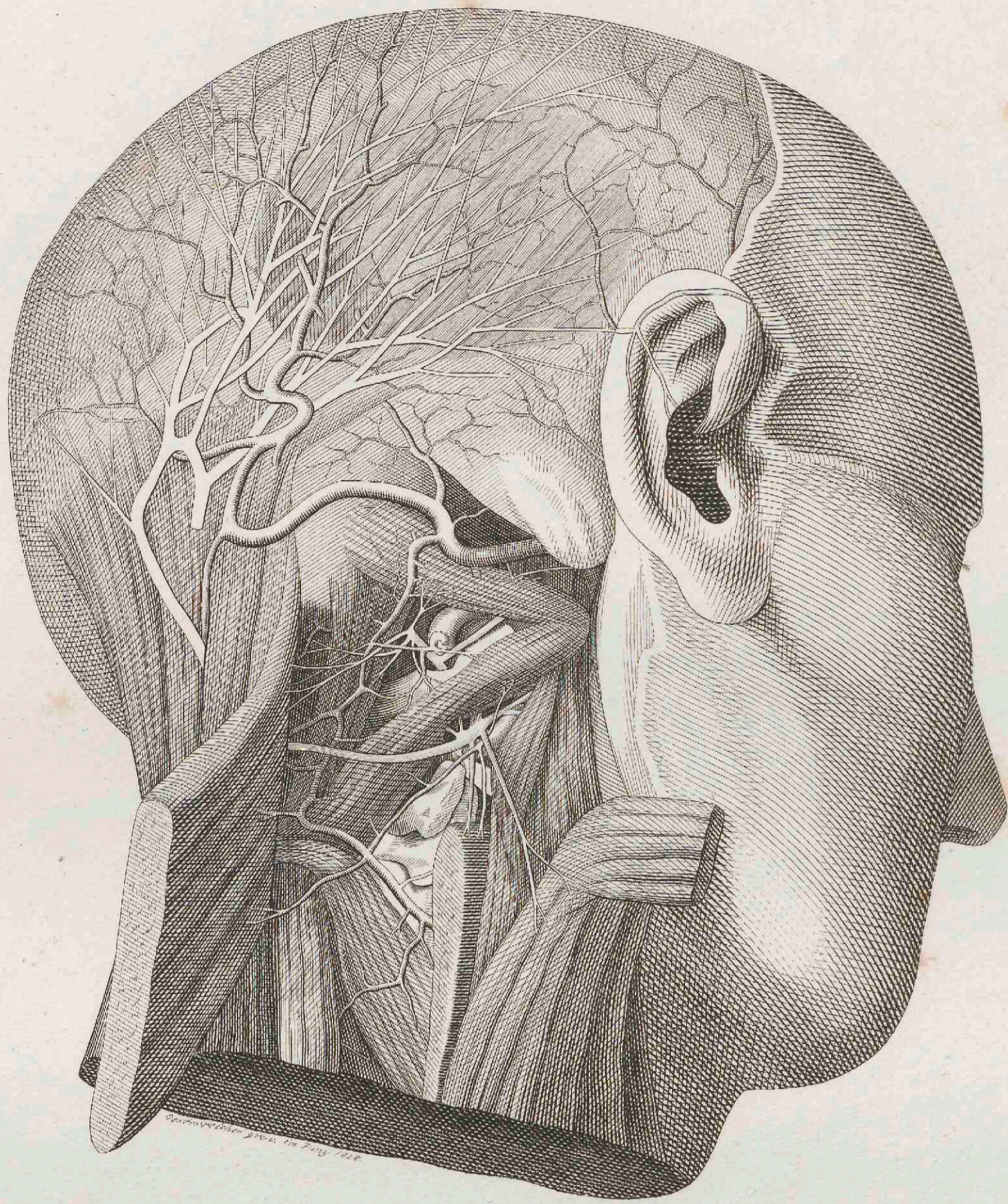
VII Nervus facialis .



Halsnerven,
nach Alch.

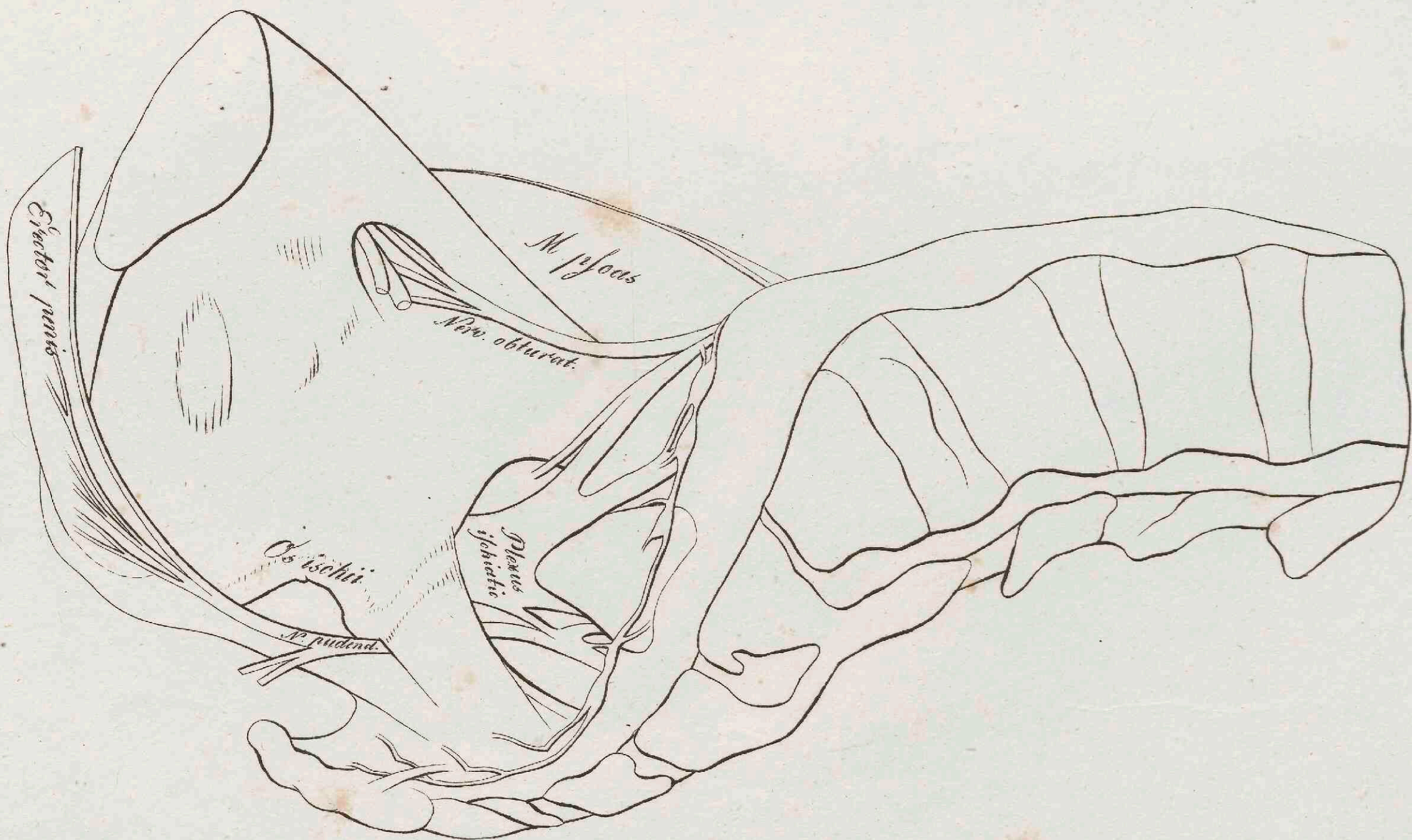
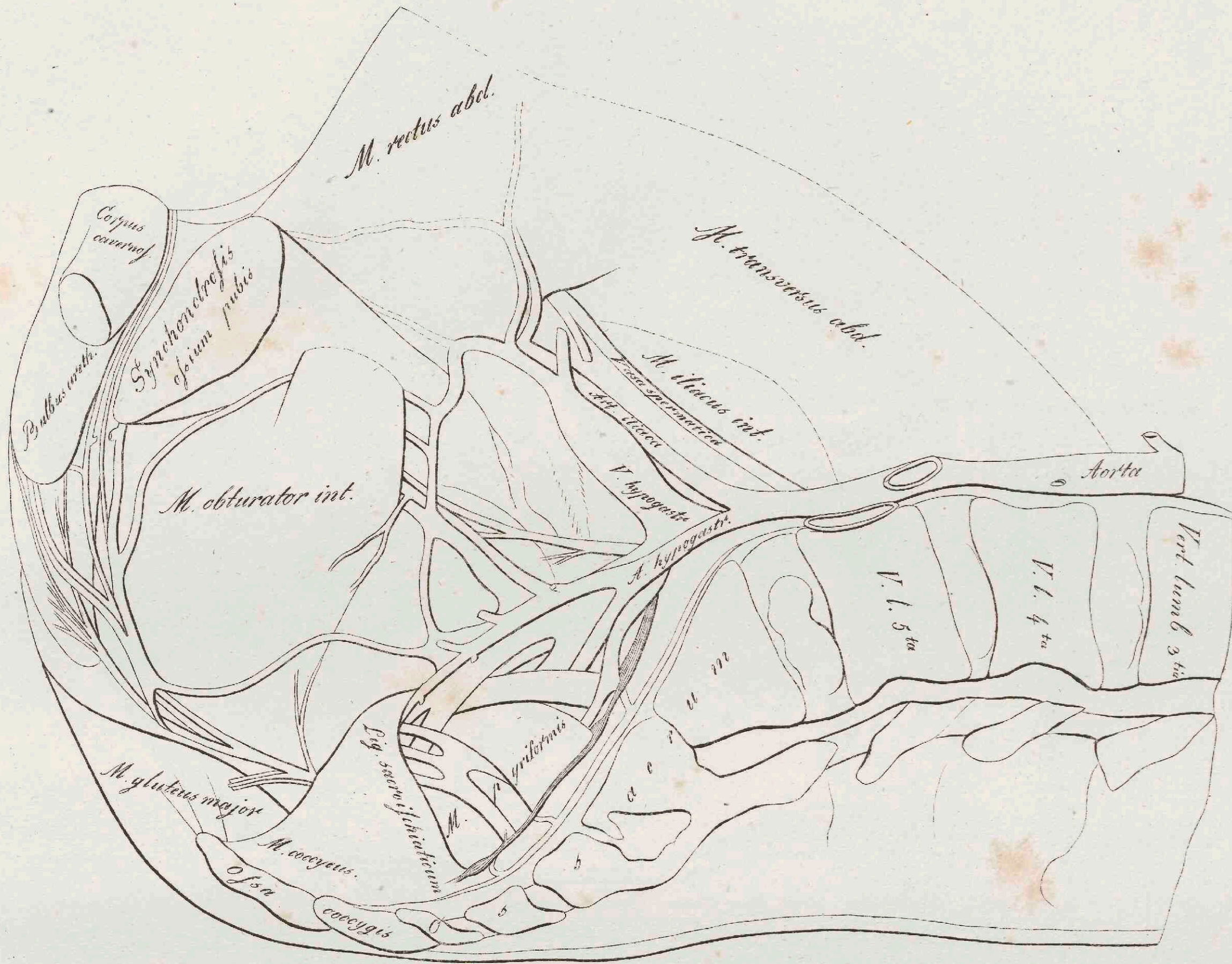
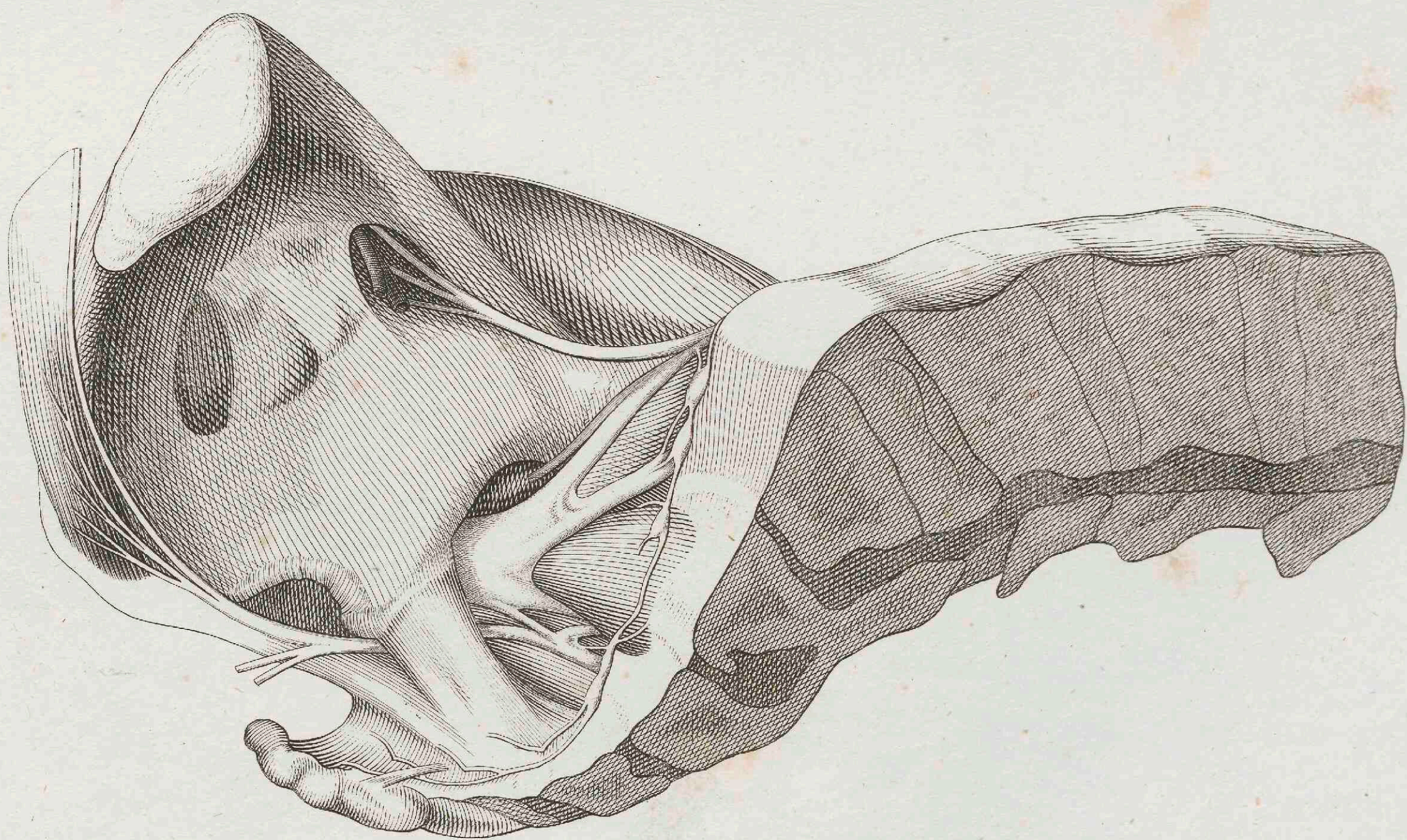
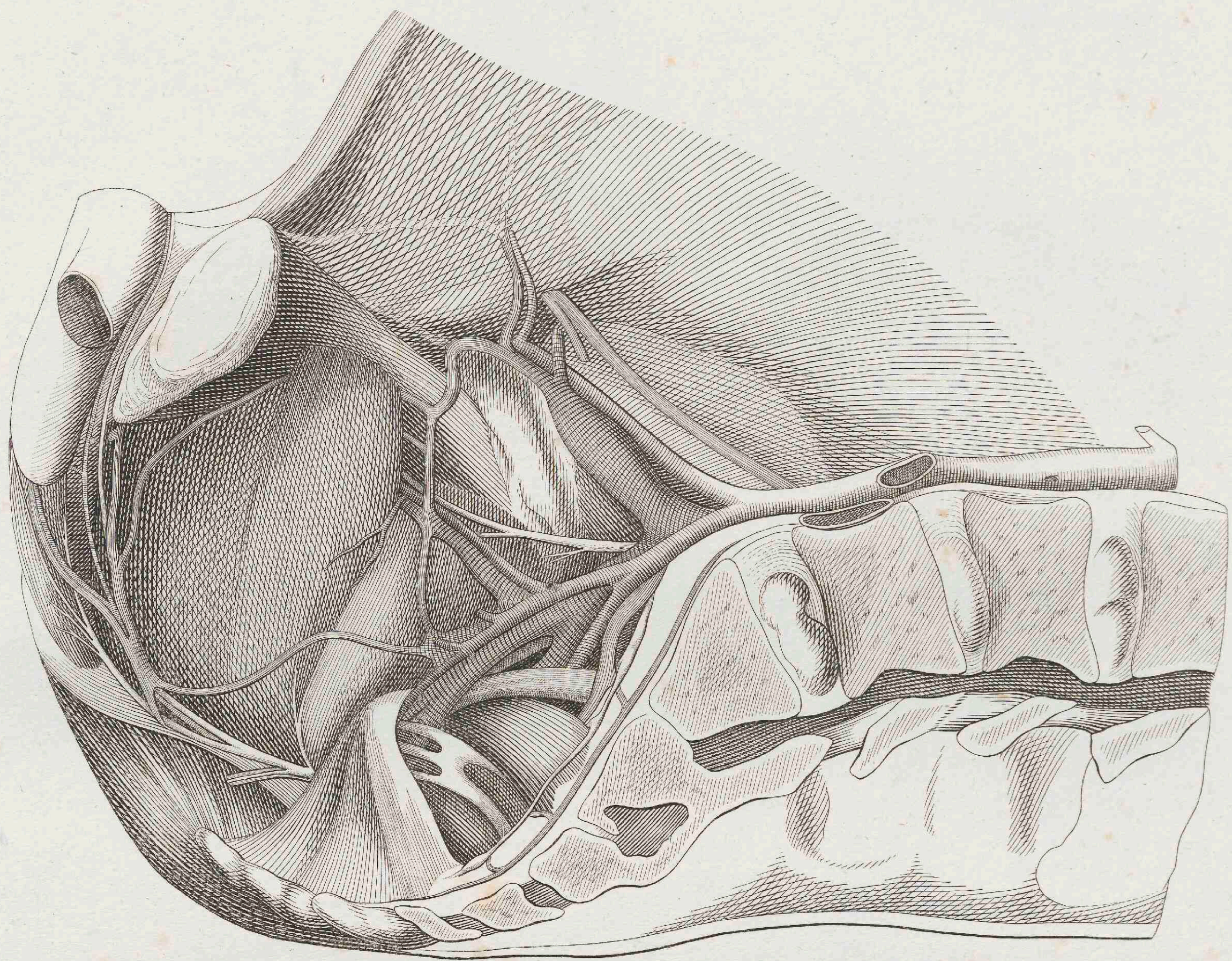
Nervorum cervicalium par I et II.



Ende des Sympathischen Nerven,

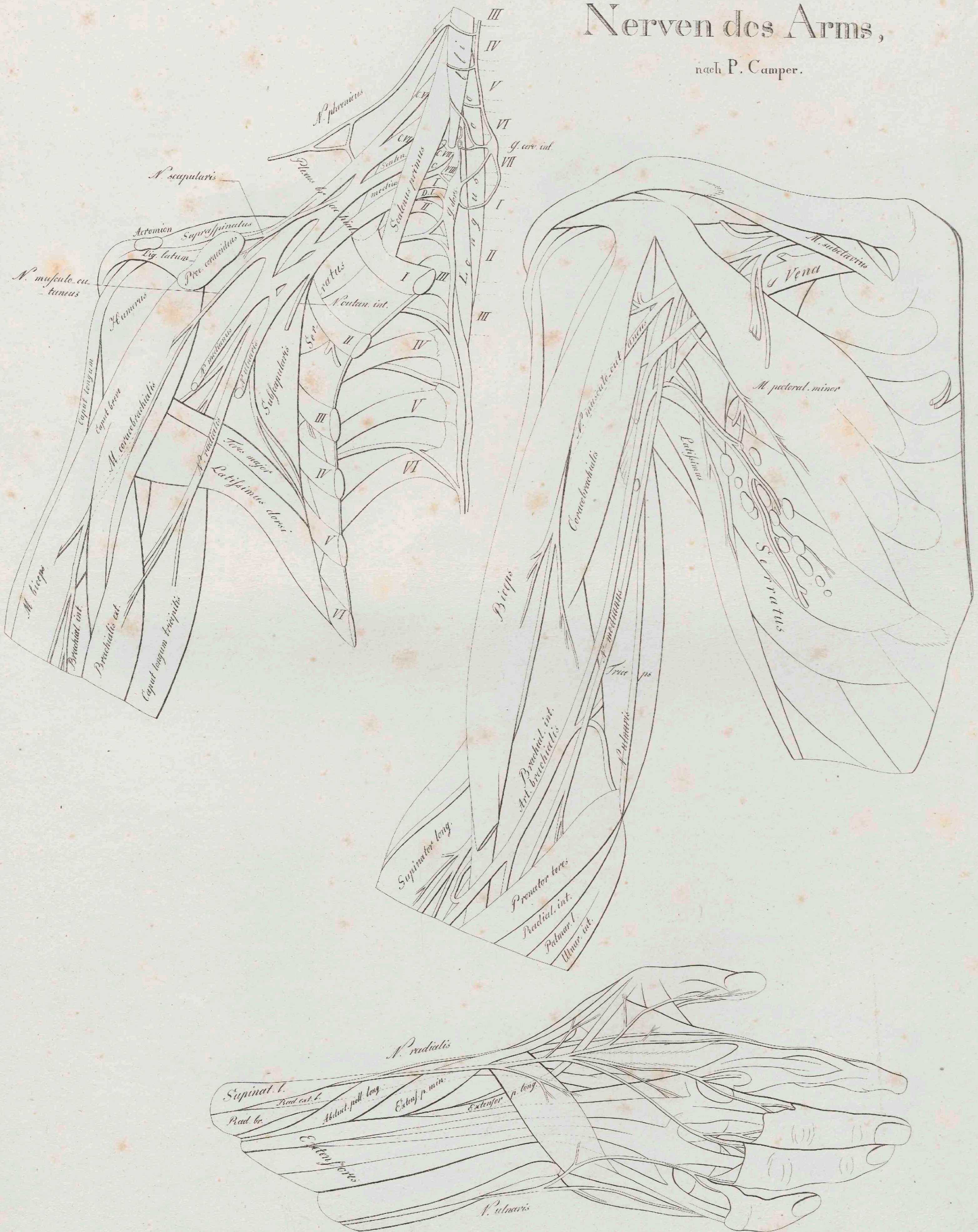nach Camper.






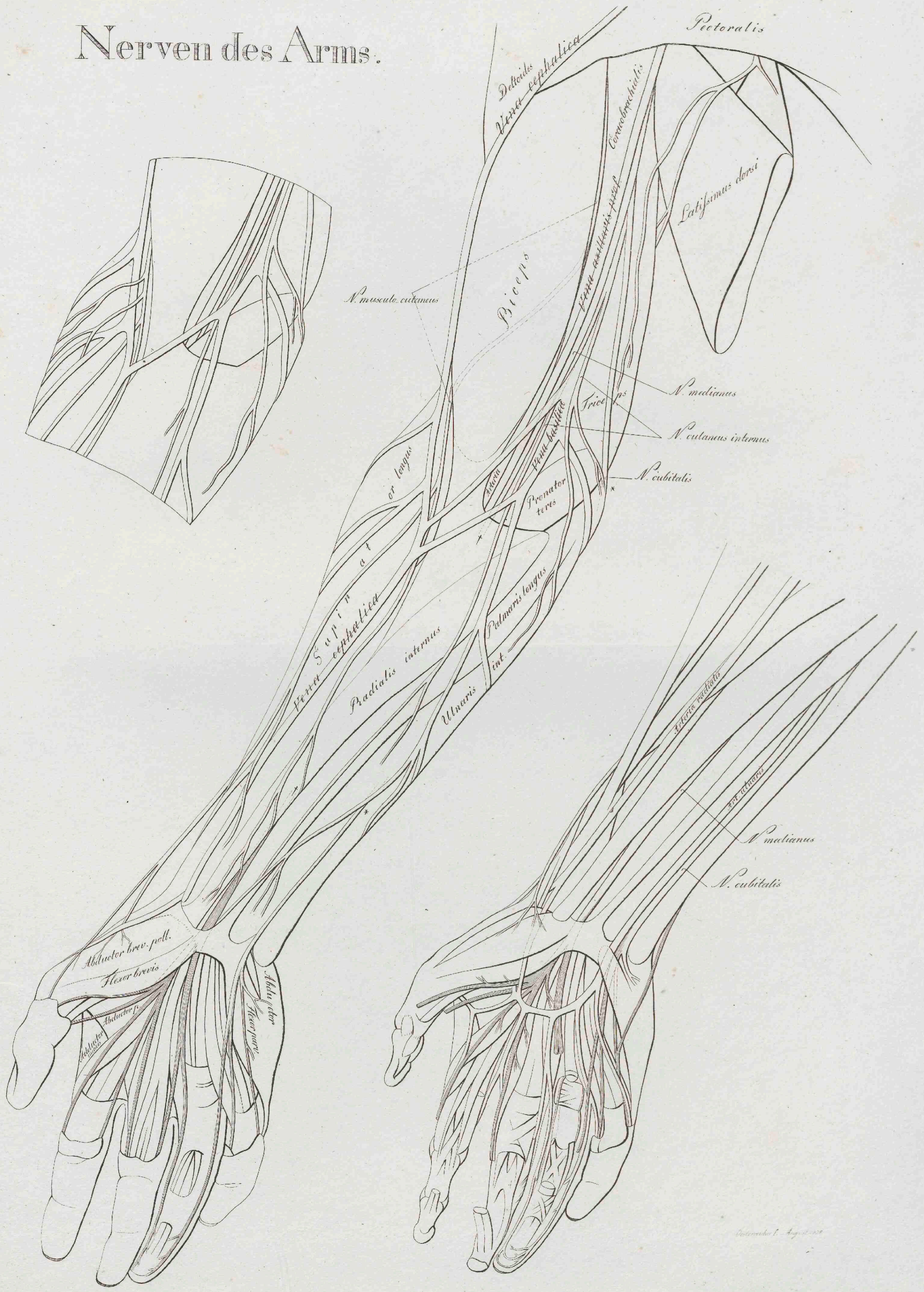
Nerven des Arms,

nach P. Camper.

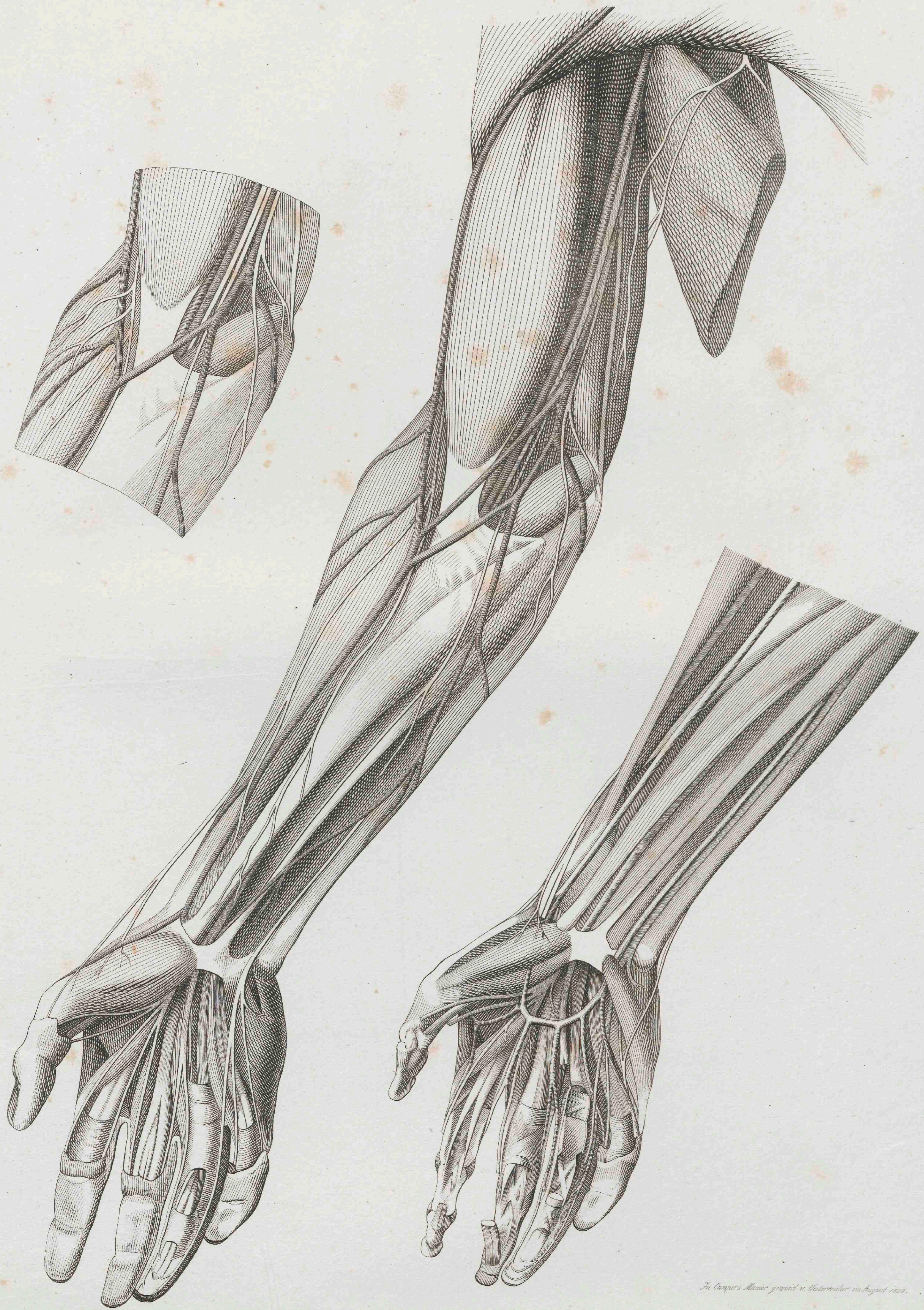




Nerven des Arms.



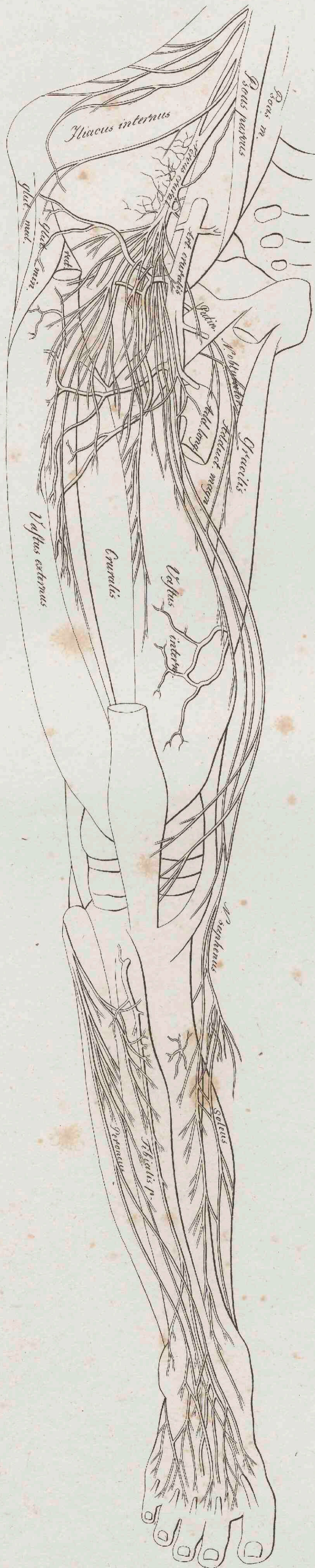
Weyrauch del. August 1788

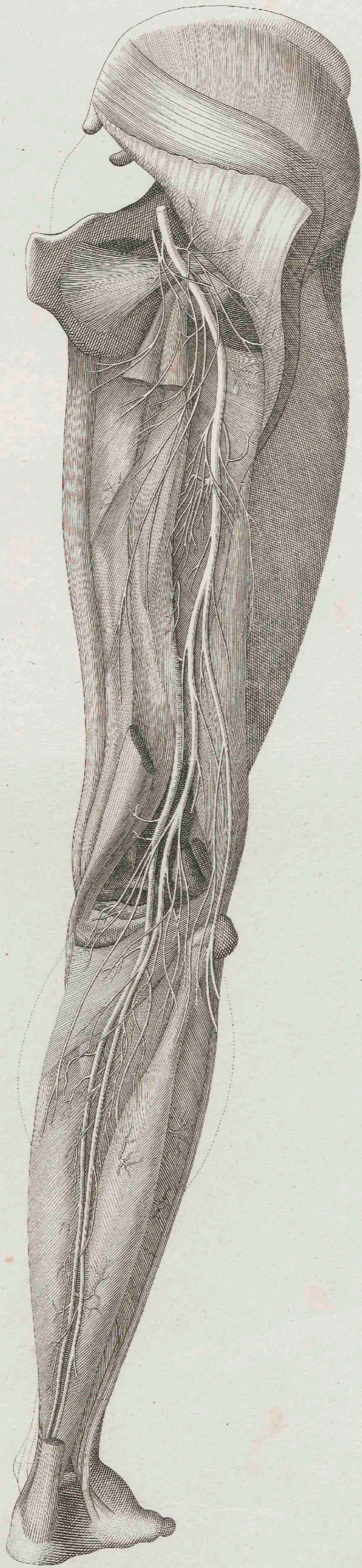
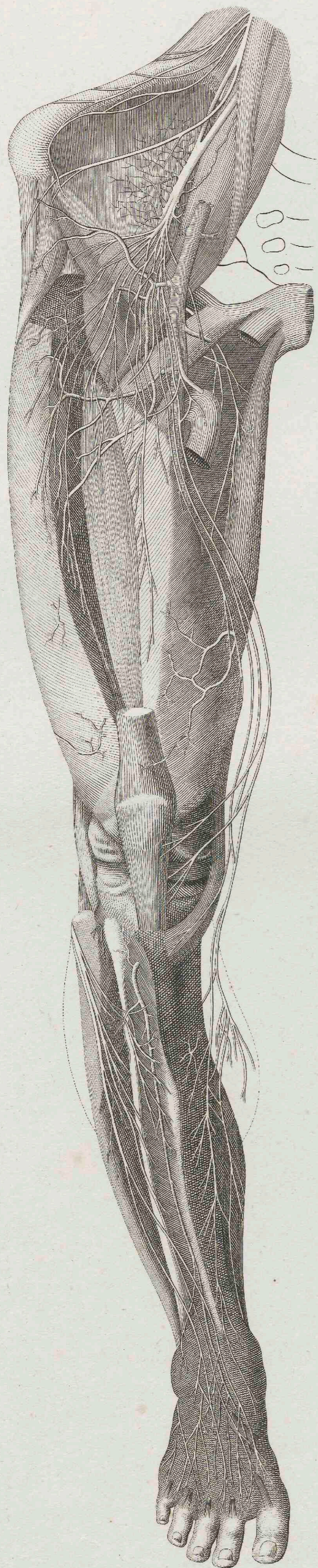


Fi. Camper's Musculi gravior & posterioribus in August. 1768.

Nerven des Schenkels.

nach Fischer.

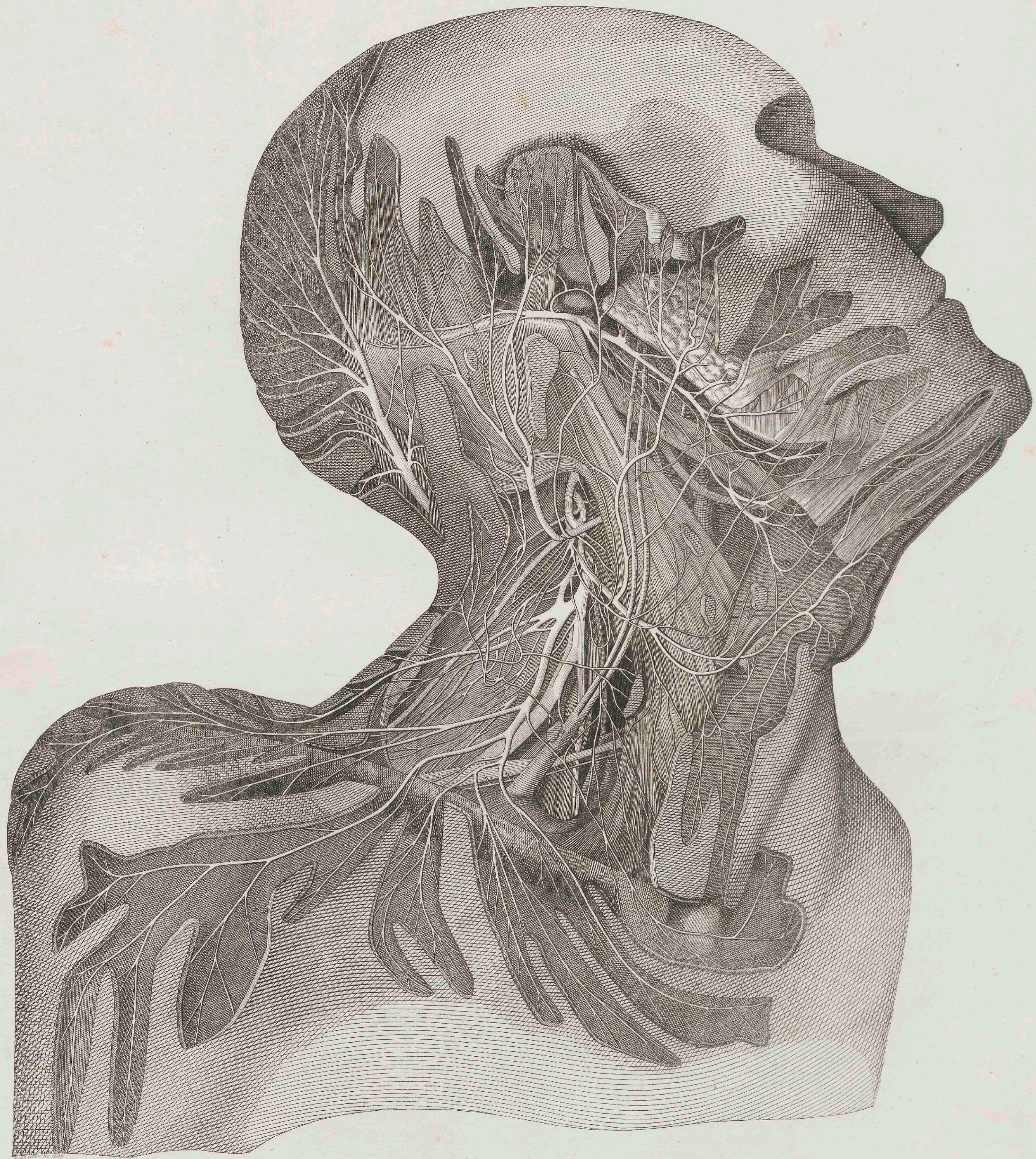




Halsnerven,
nach Peipers.



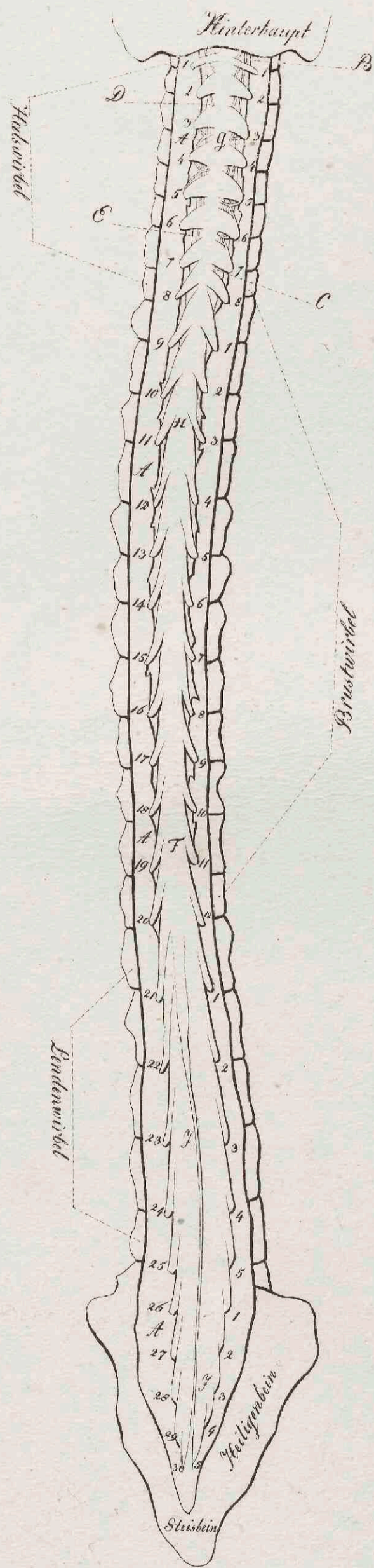
Nervorum cervicalium par III et IV.



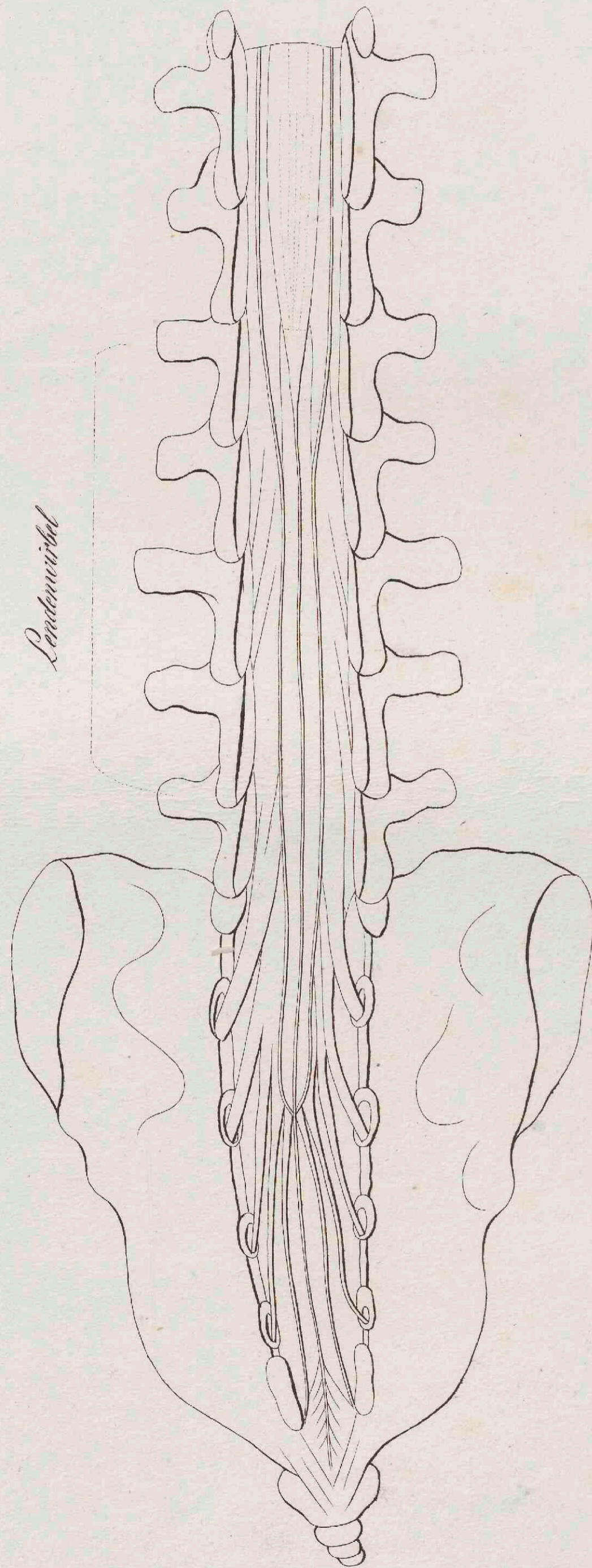
Rückenmark,

nach Burdach, Loschge und Frotcher.

T. I.



T. II.



T. III.

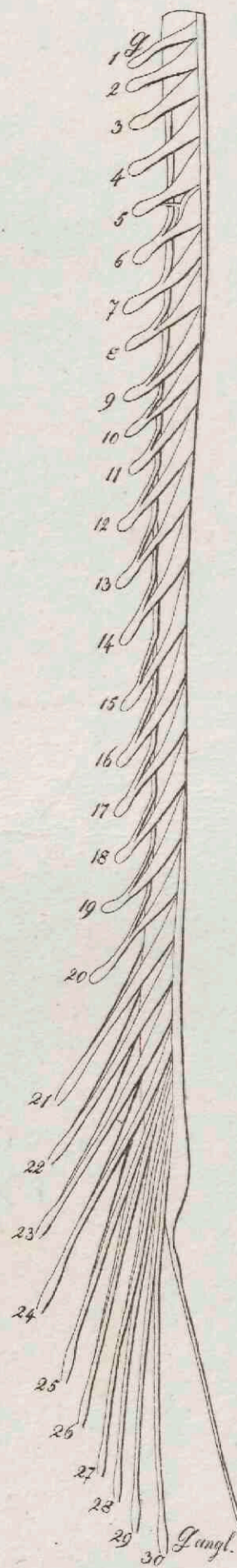
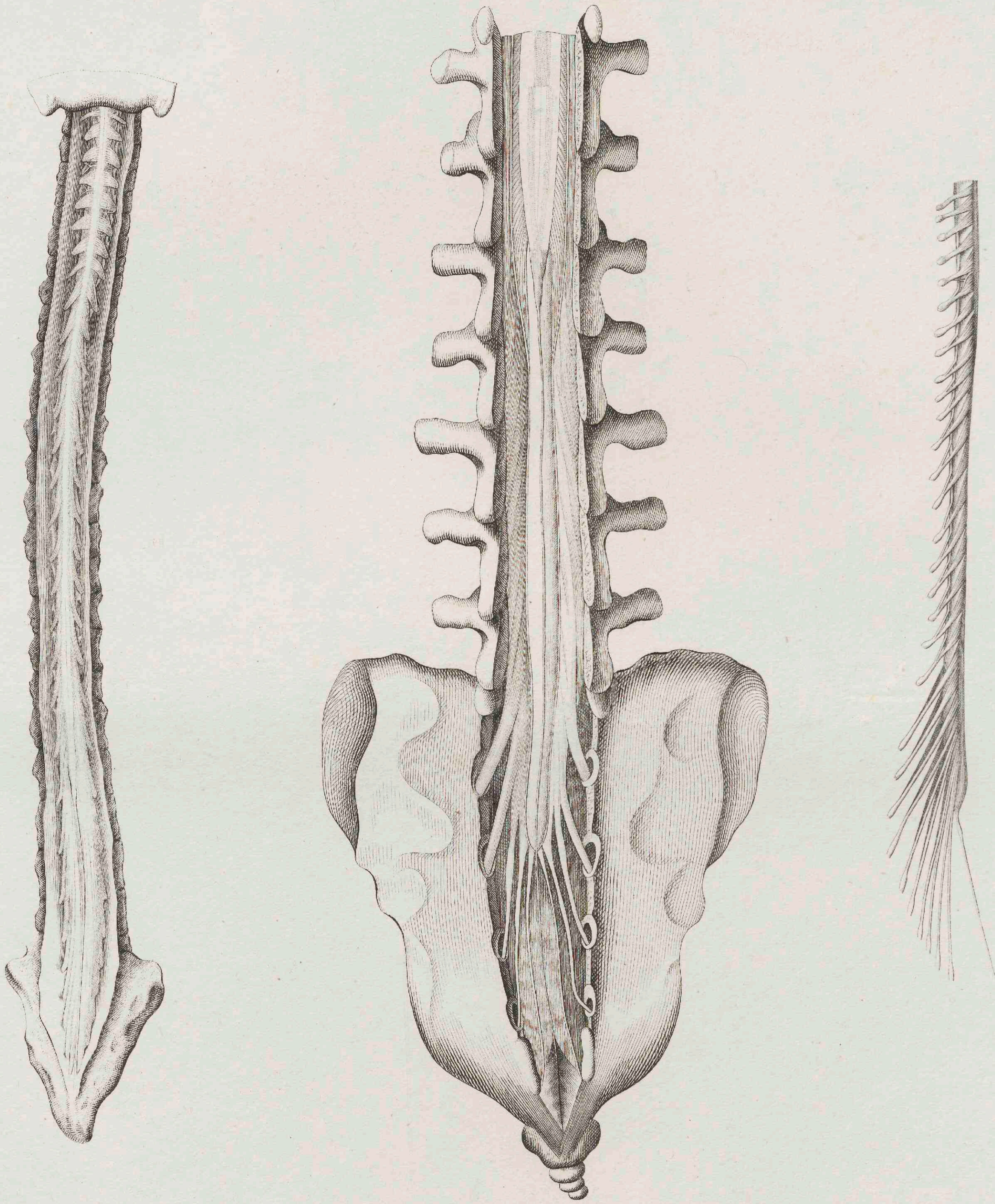


Fig. I. Rückenmark eines Erwachsenen. A. ligament. denticulatum, B. C. Beinerve des Willis, F. Ende, G. Anfang, H. Körper des Rückenmarks, I. Schlussband, oder Faden, dessen Verhältnisse sich in Lebensgröße (Fig. II) deutlicher zeigen. Fig. III. Seitenansicht vom Rückenmark eines Kindes.

Die arabischen Zahlen bedeuten die Ordnung der Nervenpaare.



Das Hirn,

nach Soemmerring.

Nerven des Hirns.

I { Riechnerve
olfactorius

III { Sehnerv
opticus

III { gemeinschaftlicher Augenmuskelnerv
oculomotorius

IV { innerer Augenmuskelnerv
trochlearis

V { dreigetheilte Nerve
trigeminus

VI { äußerer Augenmuskelnerv
abducens

VII { Auliznerv
facialis

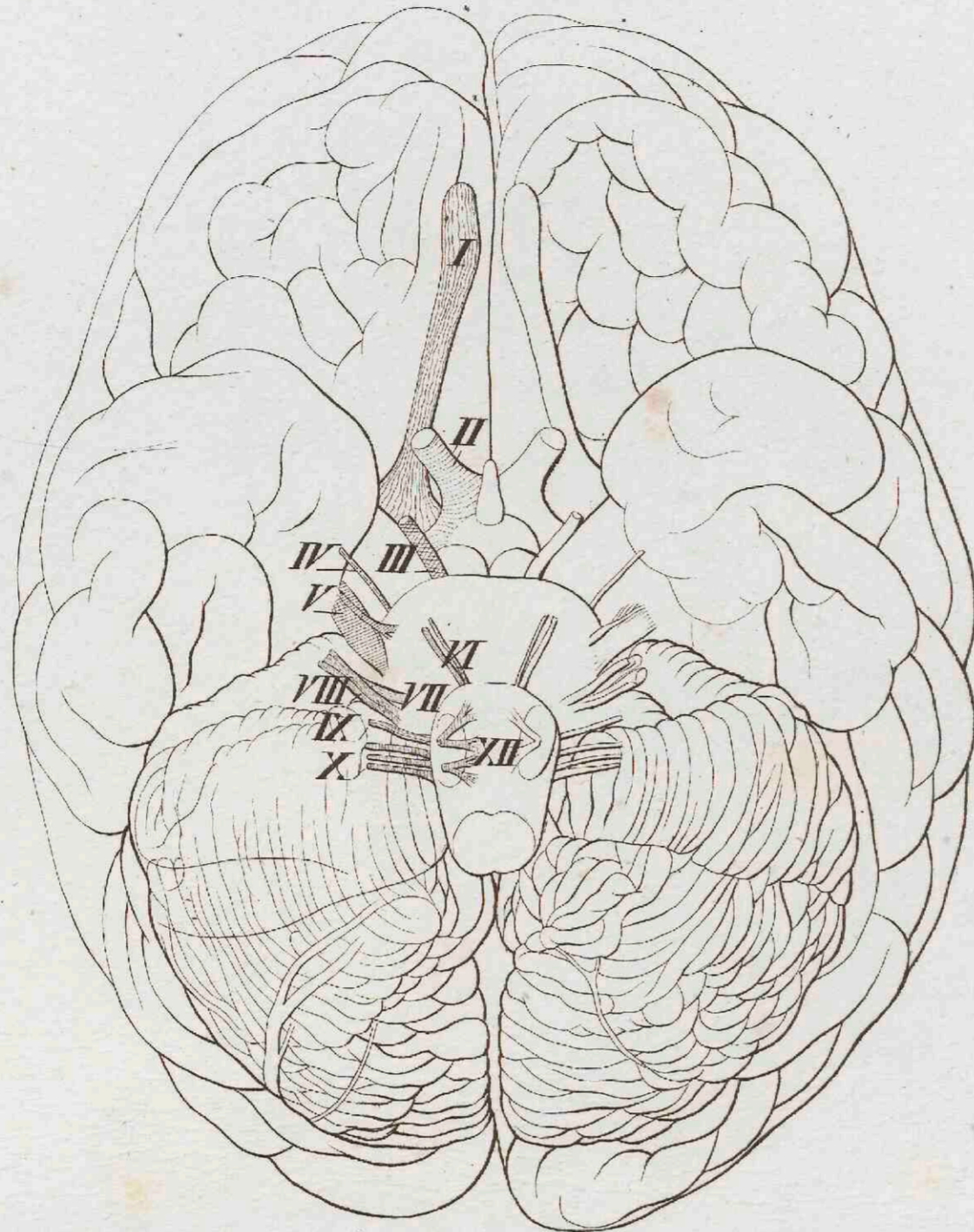
VIII { Hörnerv
acusticus

IX { Zungenschlundkopfnerv
glossopharyngeus

X { herumschweifender Nerve
vagus

XI { Beinerv
accessorius

XII { Zungenfleischnerv
hypoglossus



Senkrechter Durchschnitt oder das wahre sogenannte Profil des Hirns.

a. b. c. großes Hirn. a. vorderer b. hinterer Lappen. c. ausgeschwülzte Fläche, die auf dem Zelle ruht.

d. e. Pallium (corpus callosum) d. vorderer, e. hinterer Pund.

f. g. Bogus (forix) g. linkes Säulchen, das in den Sehnervenhügel geht.

h. i. K. Scheidewand. Höhle (ventriculus opti).

l. Markblatt, welches die Höhle vorwärts u. unterwärts schließt.

m. vorderer Commissur.

n. n. Blättchen, welches die dritte Höhle schließt.

o. Adersgellichte.

p. q. r. Sehnervenhügel.

s. t. Zusammenhangs-Stelle.

u. eingeleytes markiges Streichen, das sich vorwärts gegen das Säulchen, hinterwärts in 2 markige Leisten der Zirbel verliert.

z. Zirbel.

t. hintere Commissur.

u. Hirnsand

v. w. Vordrüse v. oberer, w. unterer.

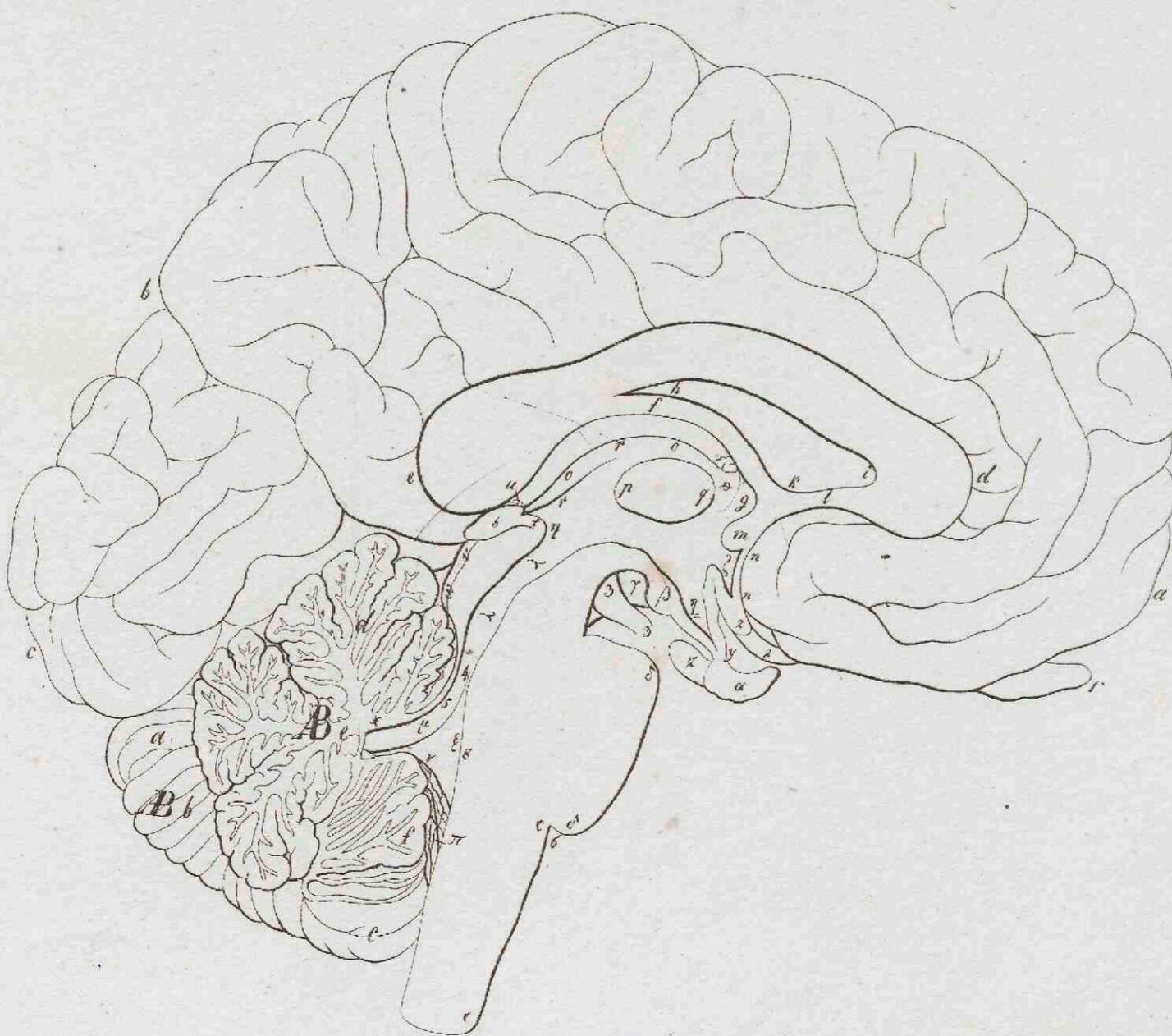x. Klappe

y. Trichter

z. α. Hirnanhang. z. grauer α. weißer Theil.

β. Markkugeln

γ. linker Theil der Anschwellung zwischen den Sehnerven, aus welcher das 3^{te} Hirnventrikel entspringt.



δ. δ. Hirnknoten.

ε. ε. Rückenmark.

η. η. θ. Dritte Hirnhöhle.

θ. Stelle unter dem Gewölbe, wo nicht nur die Seiten-

hirnhöhlen unter sich, sondern auch mit der 3^{ten} Hirnhöhle in Verbindung kommen.

ζ. Gang d. 3^{ten} Höhle vor der Kreuzungsstelle der Sehnerven.

η. Gang zum Trichter.

ι. ι. Wasserleitung (aqueductus) oder Canal zwischen der 3. u. 4. Höhle.

μ. v. ζ. Vierte Höhle.

μ. obere.

v. untere.

ξ. hintere Wand

π. Adersgellichte zwischen dem kleinen Hirne und Rückenmarke, welches d. 4. Höhle schließt.

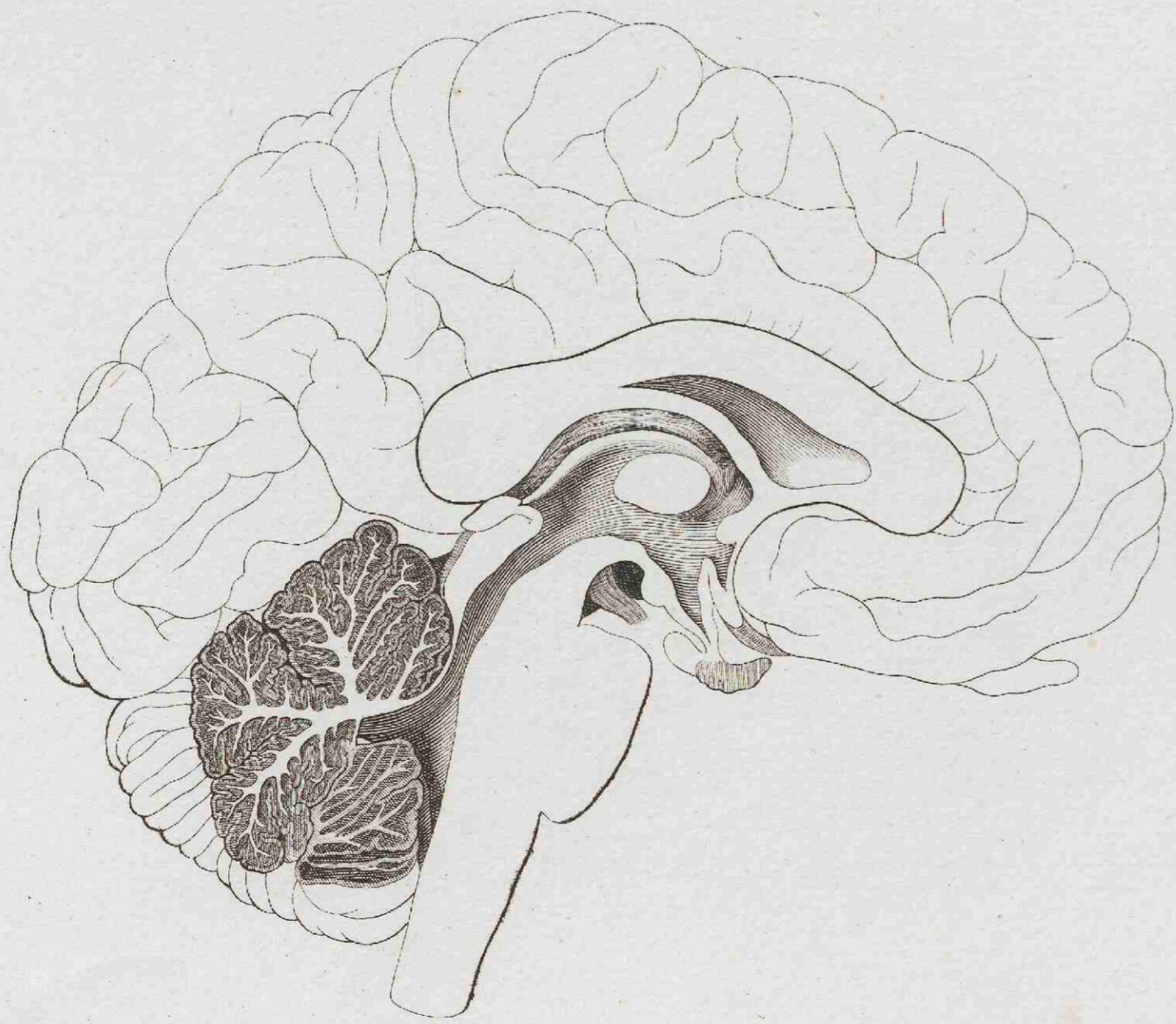
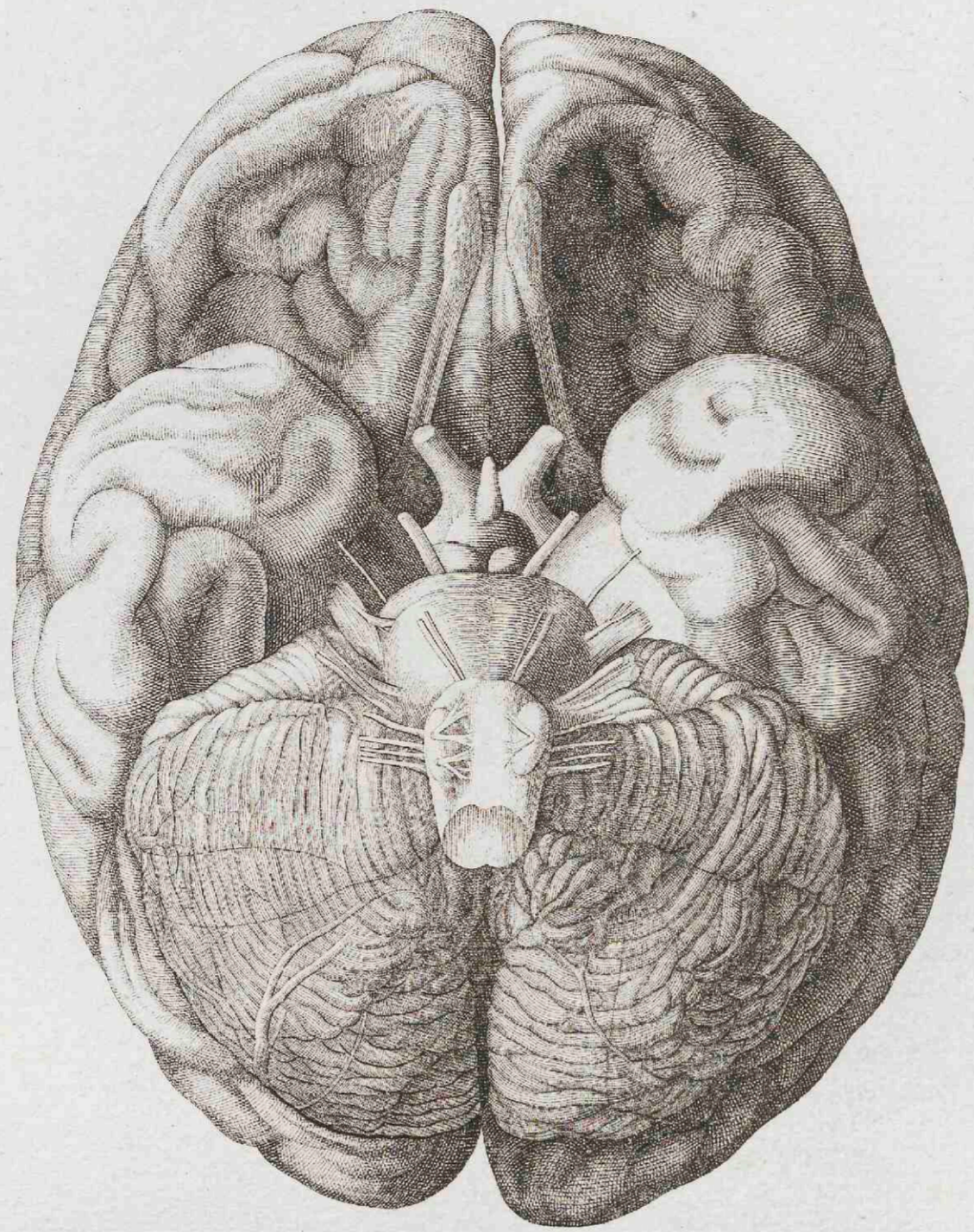
A. B. kleines Hirn. a. b. c.

A. Lebensbaum. d. e. t.

1. Kette des Riechnerven.

2. Sehnerv.

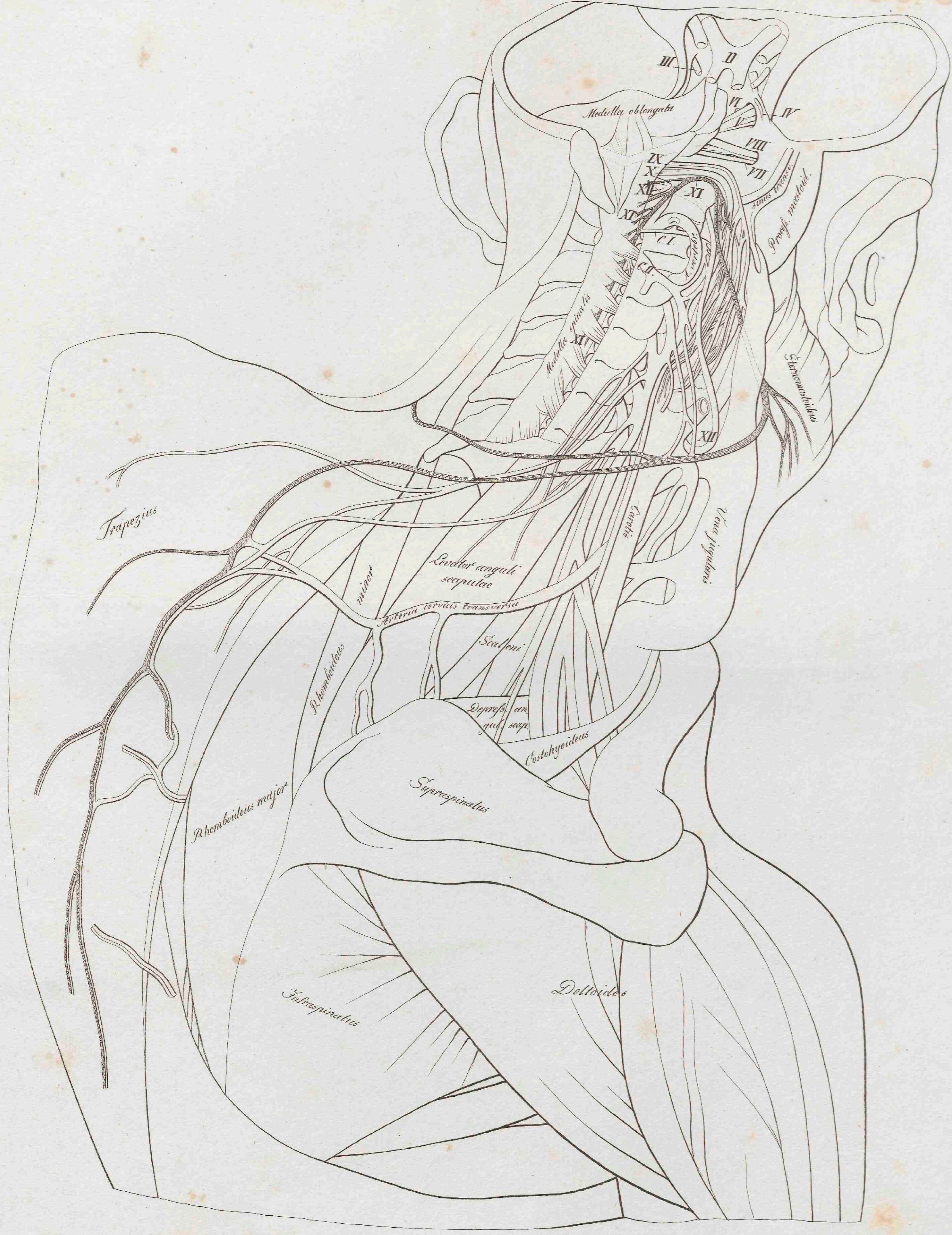3. u. 3. Hirnventrikel der Nerven.

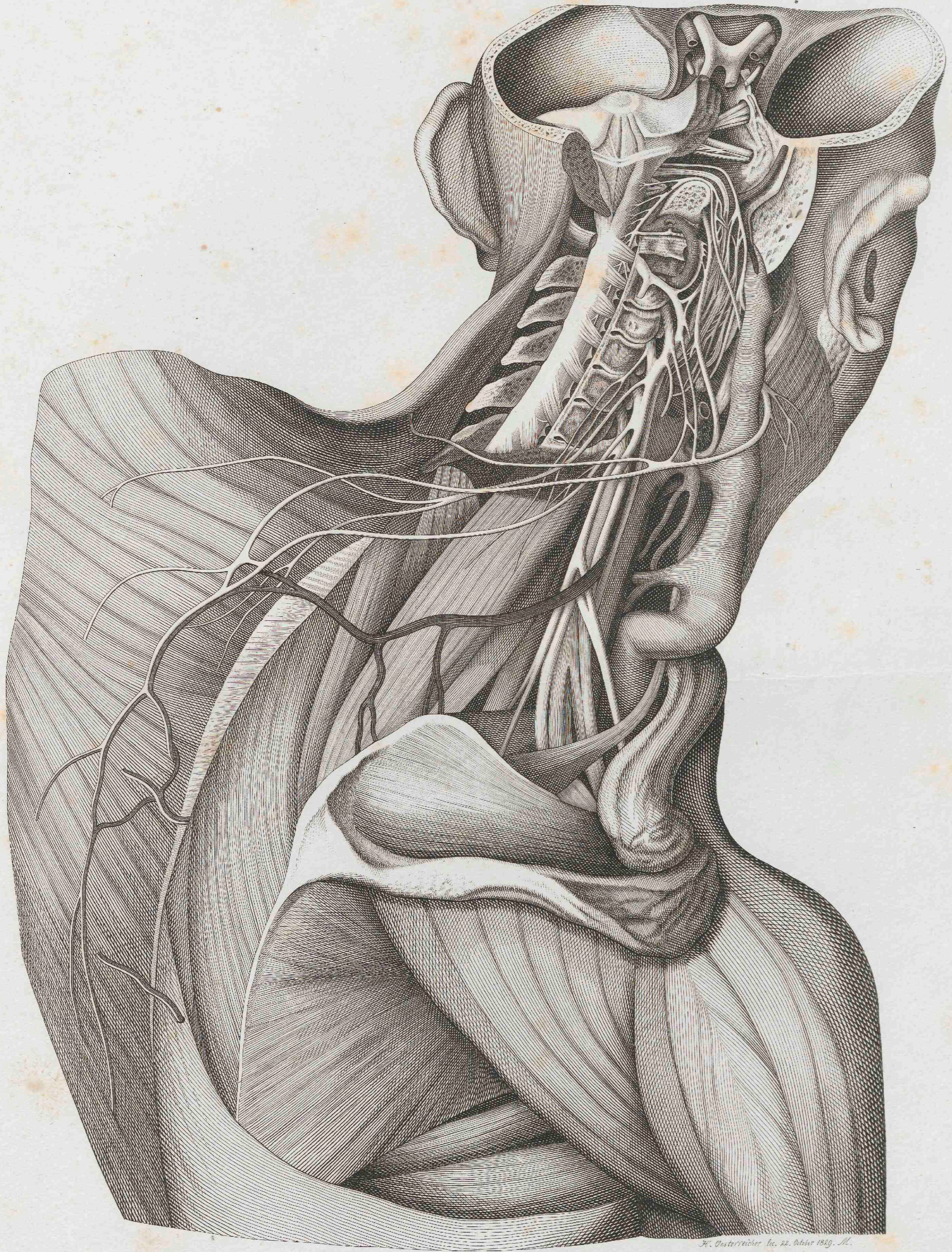



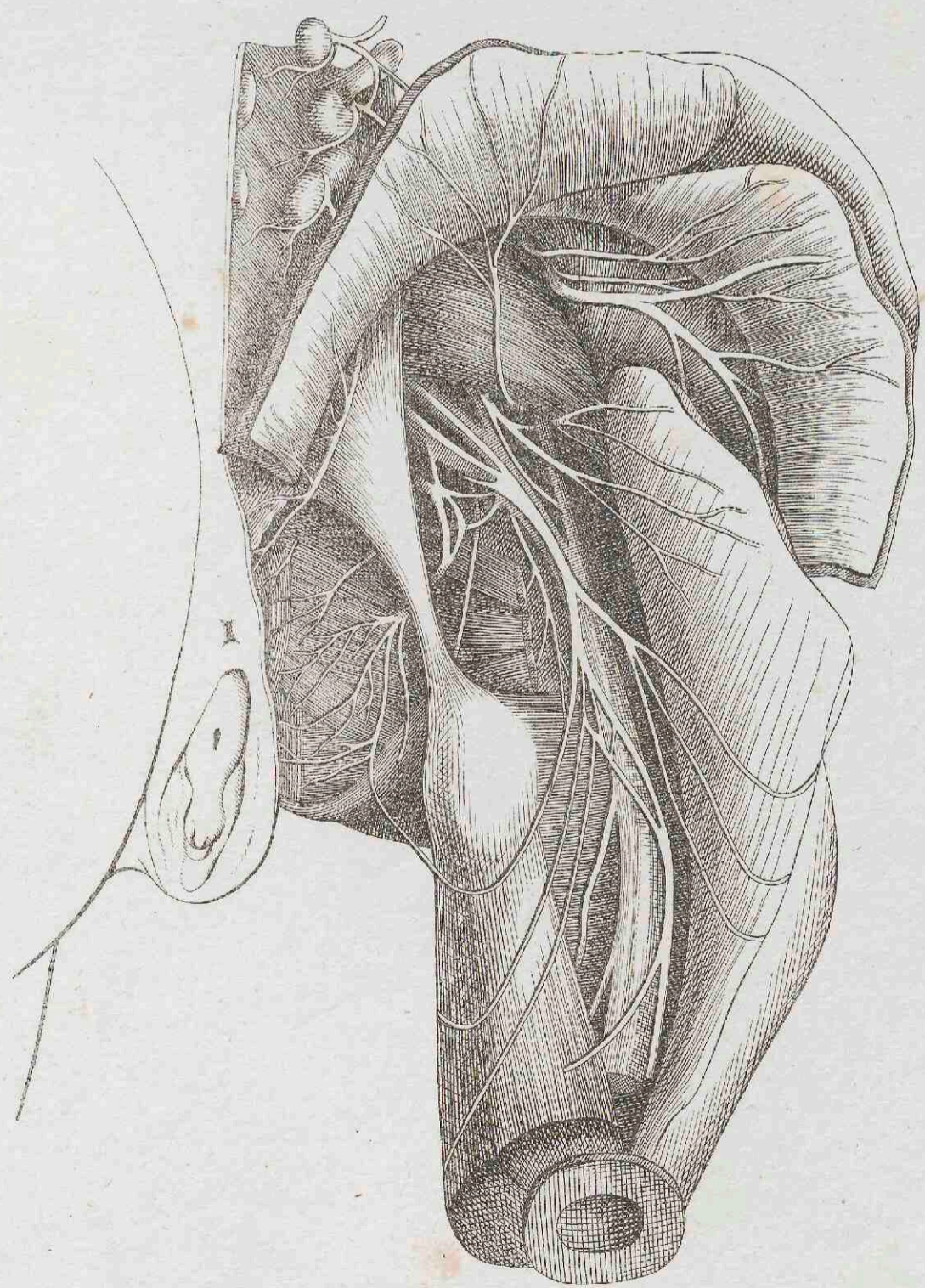
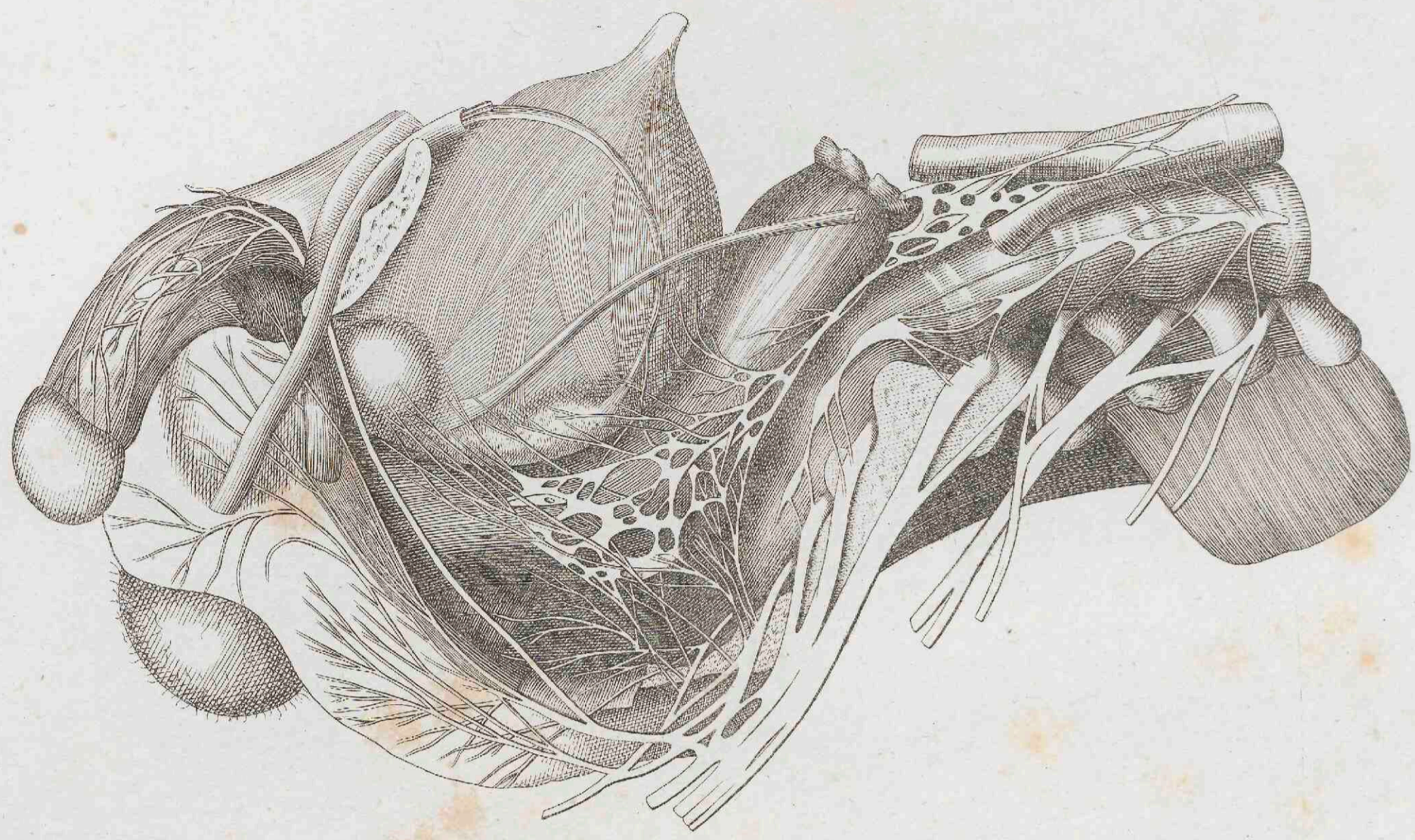
Castroreider 1. 17. September 1829.

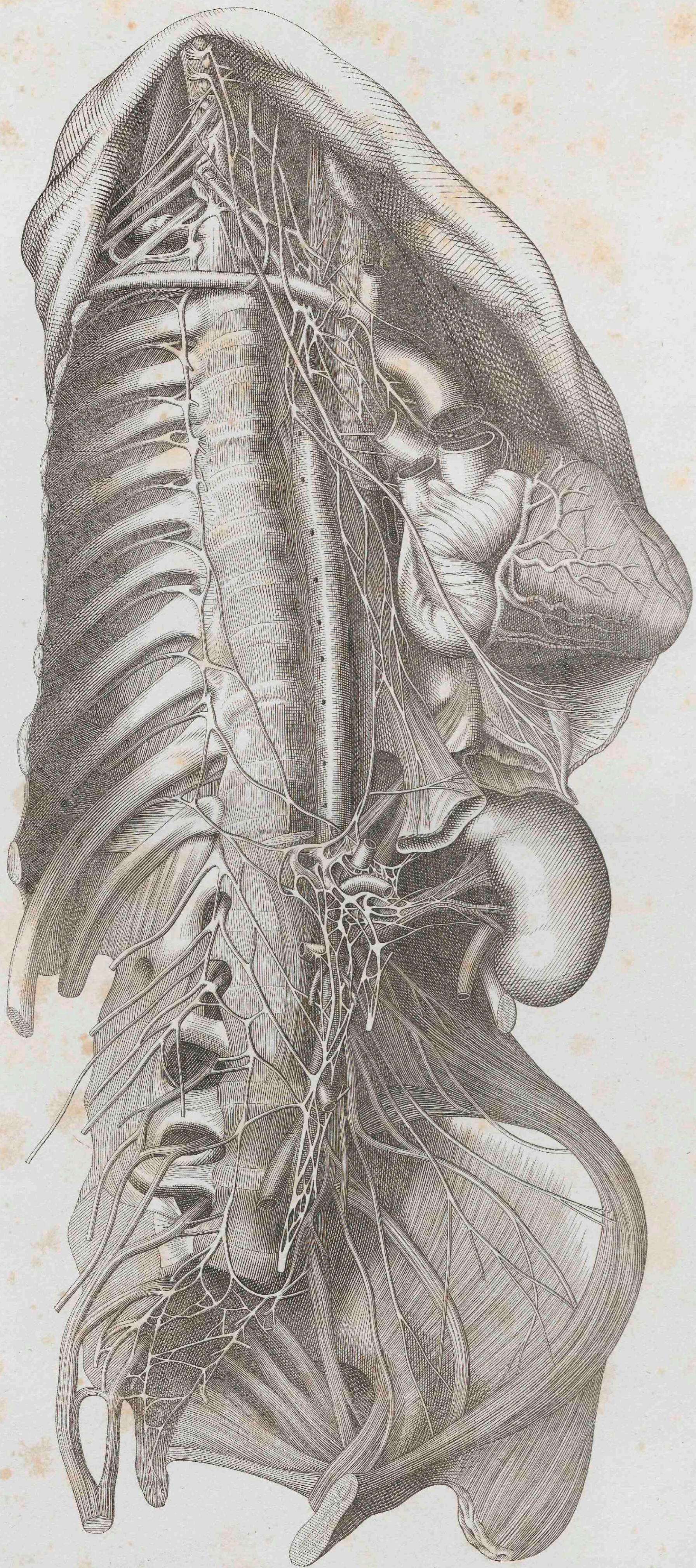
Beinerve,

nach Scarpa.



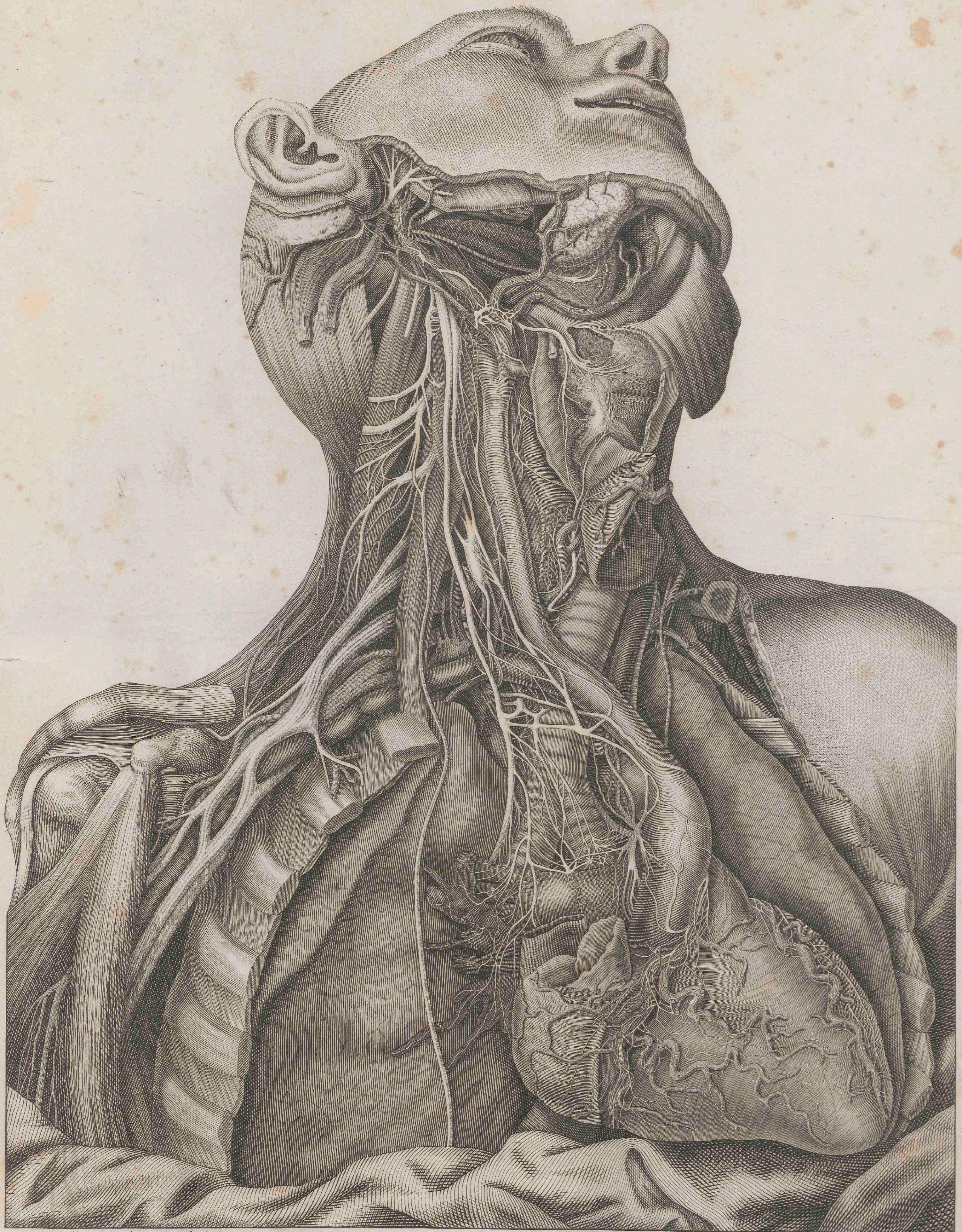






Herumschweifender und sympathischer Nerve.





Nerven der Gebaermutter.



