





Chirurgisch-anatomische Abbildungen für Ärzte und Wundärzte

<https://hdl.handle.net/1874/284750>







h

J. C. Rosenmüllers

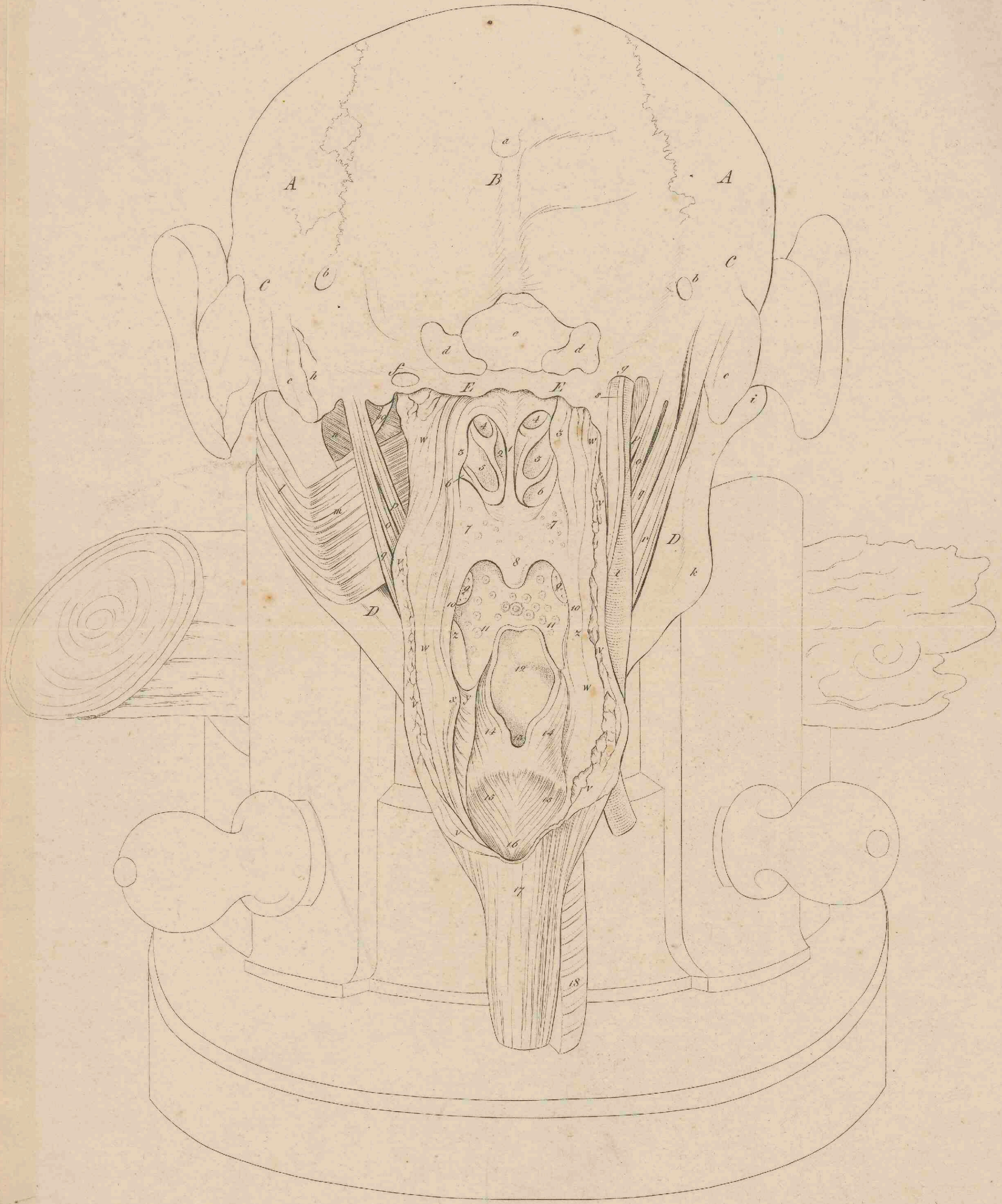
Chirurgisch - Anatomische

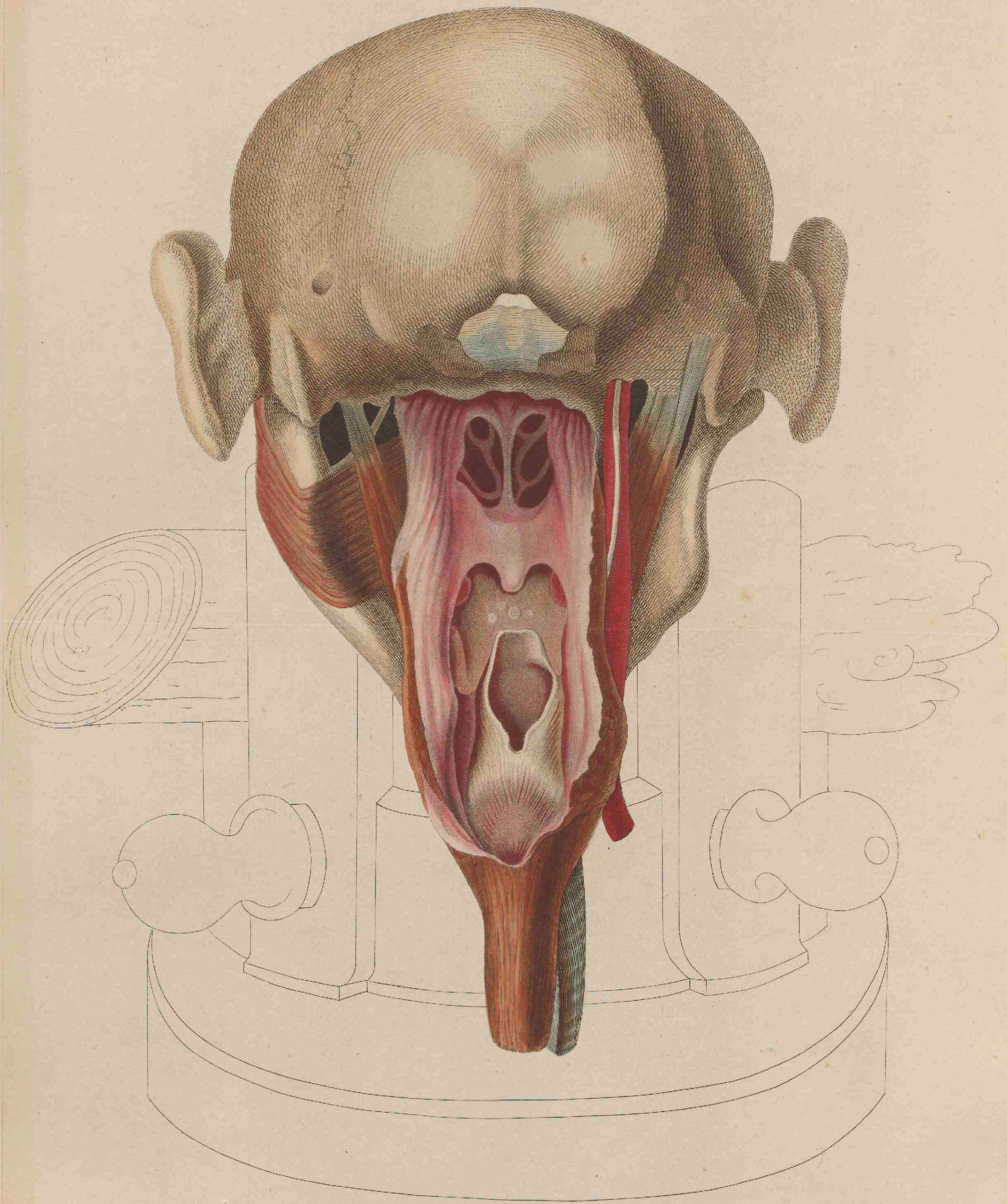
ABBILDUNGEN.

ERSTER THEIL

welcher die Theile des Kopfs und Halses begreift.

I. Lieferung.





Rosenmüller ad nat. deli.

J. F. Schröter, sculps. in Leipzig

Fig. 1.

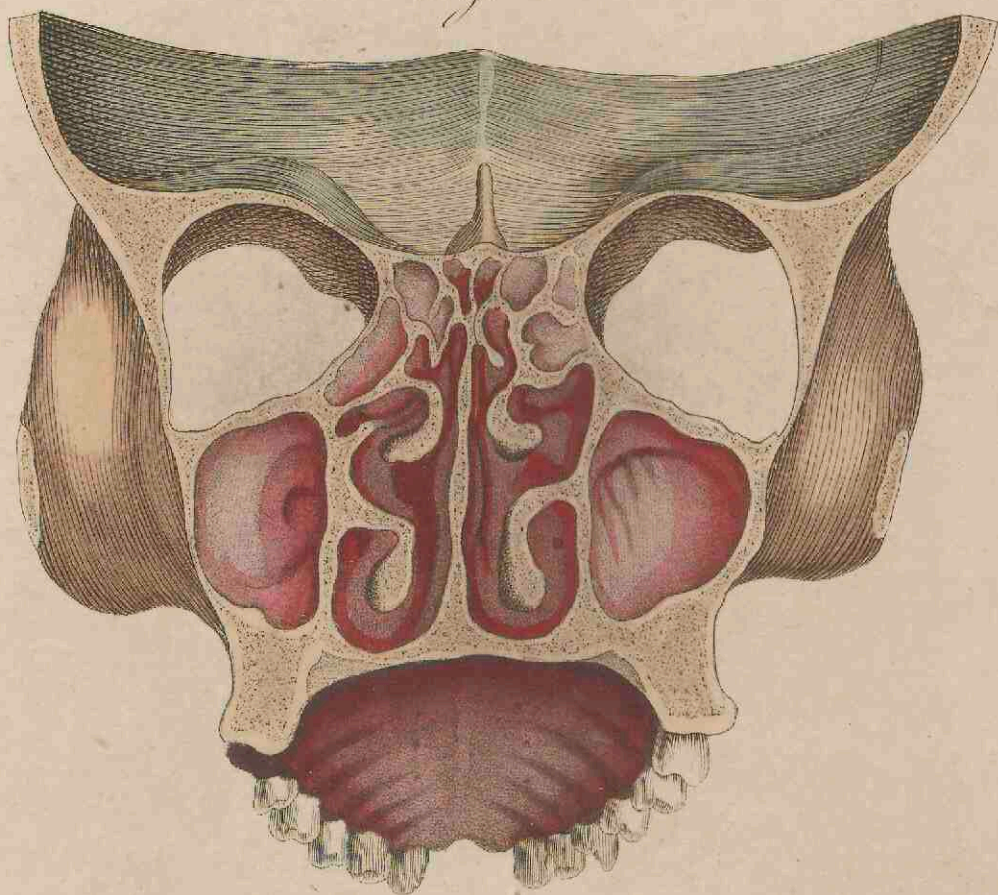
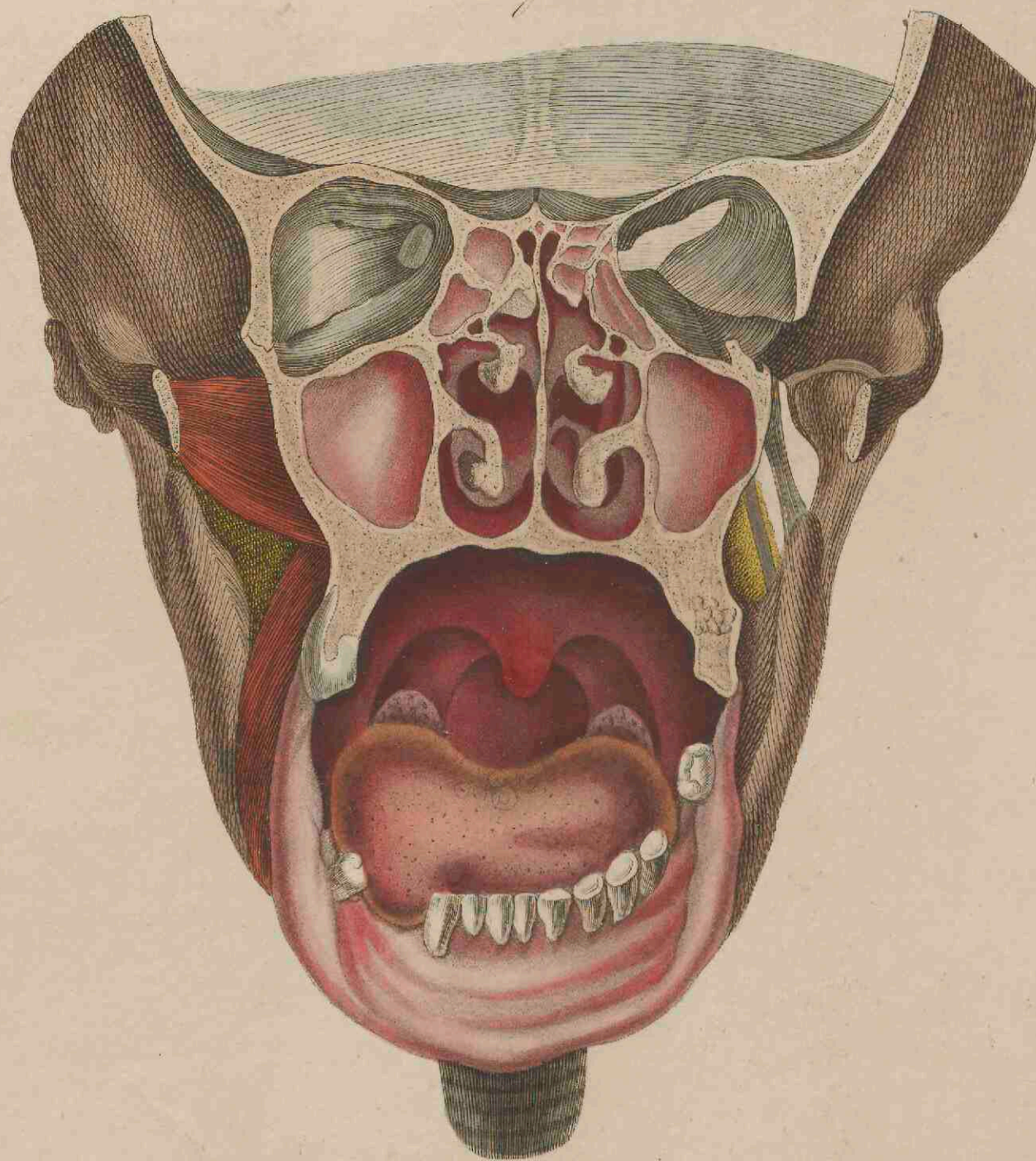
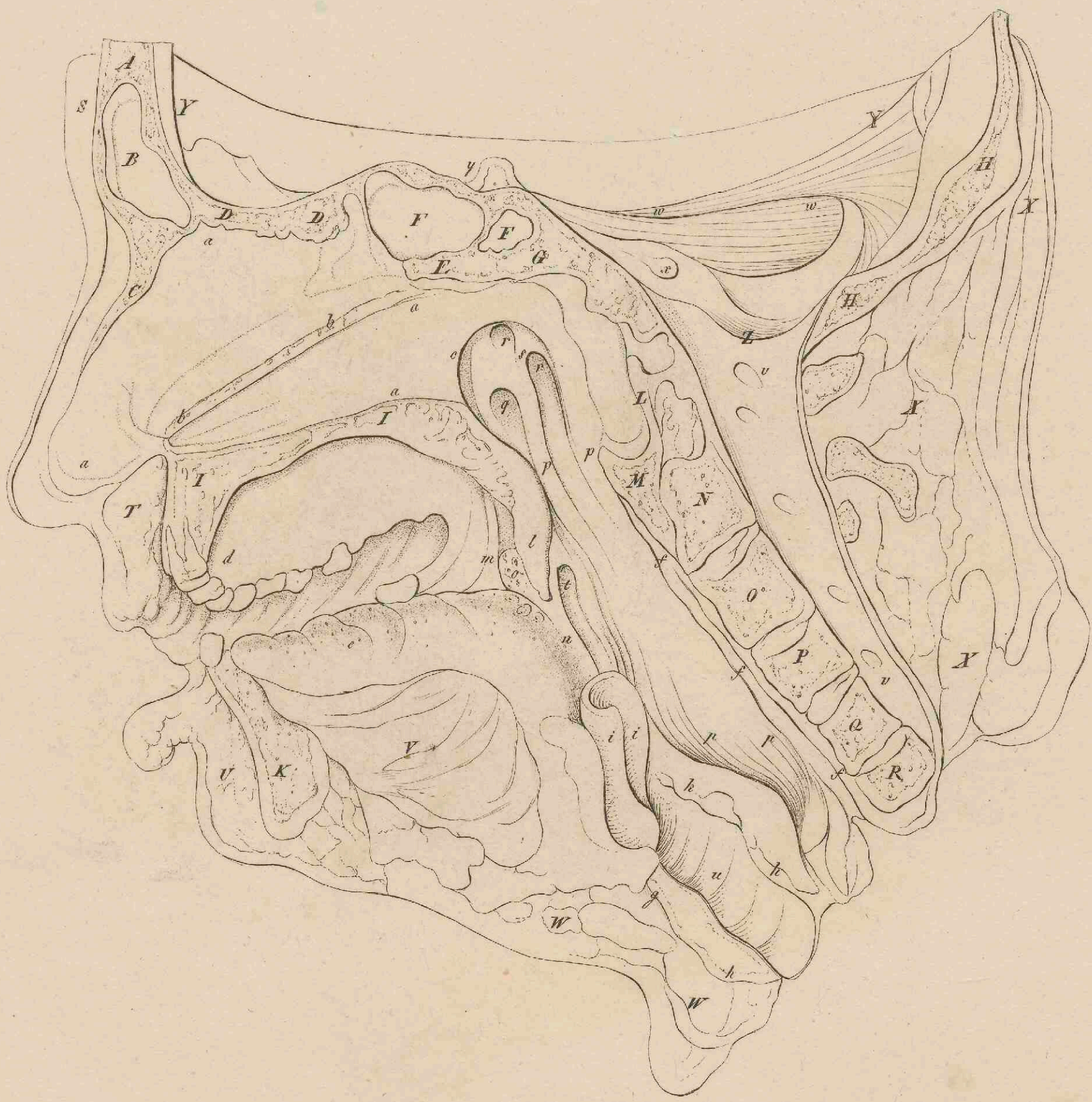
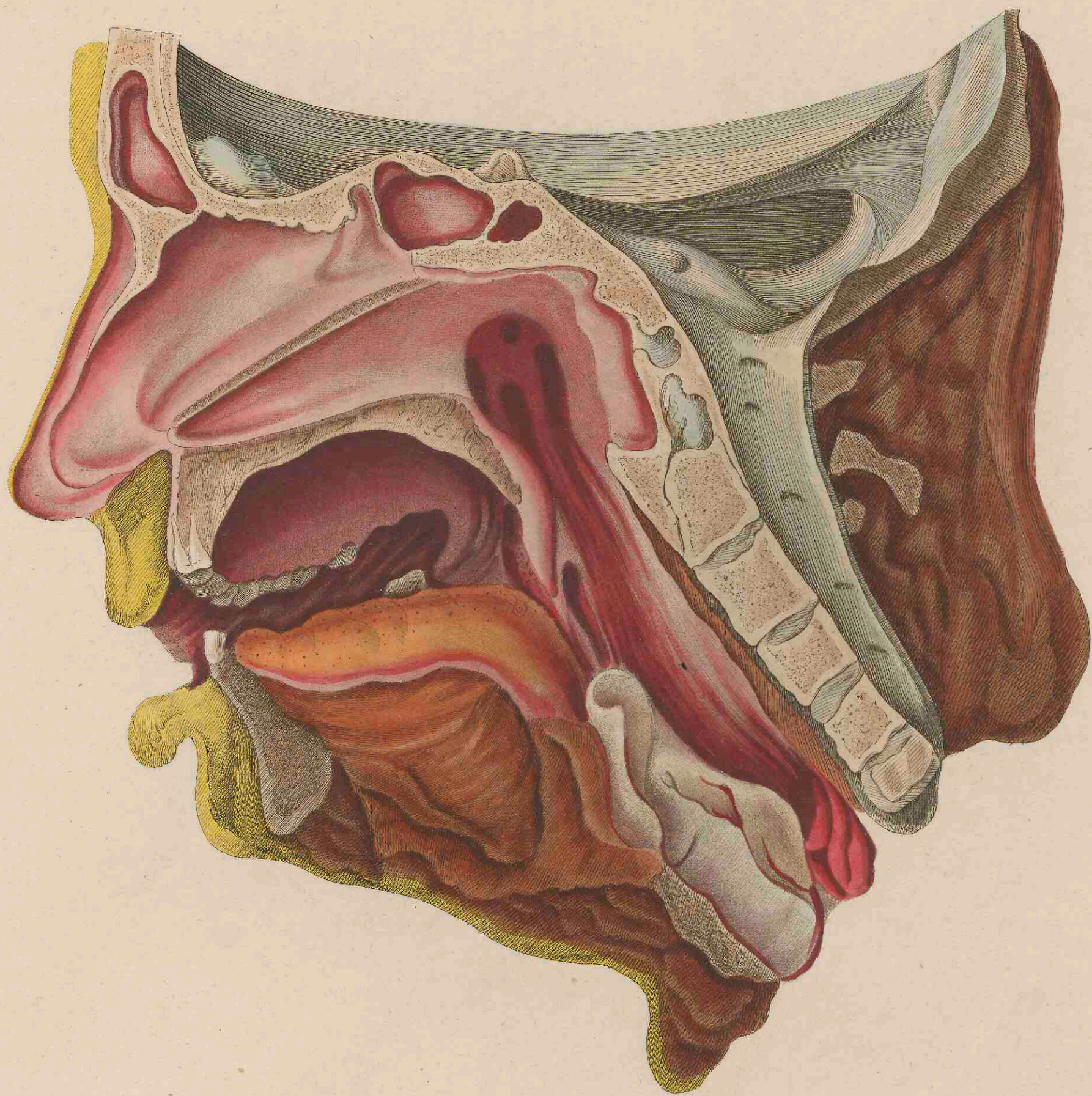
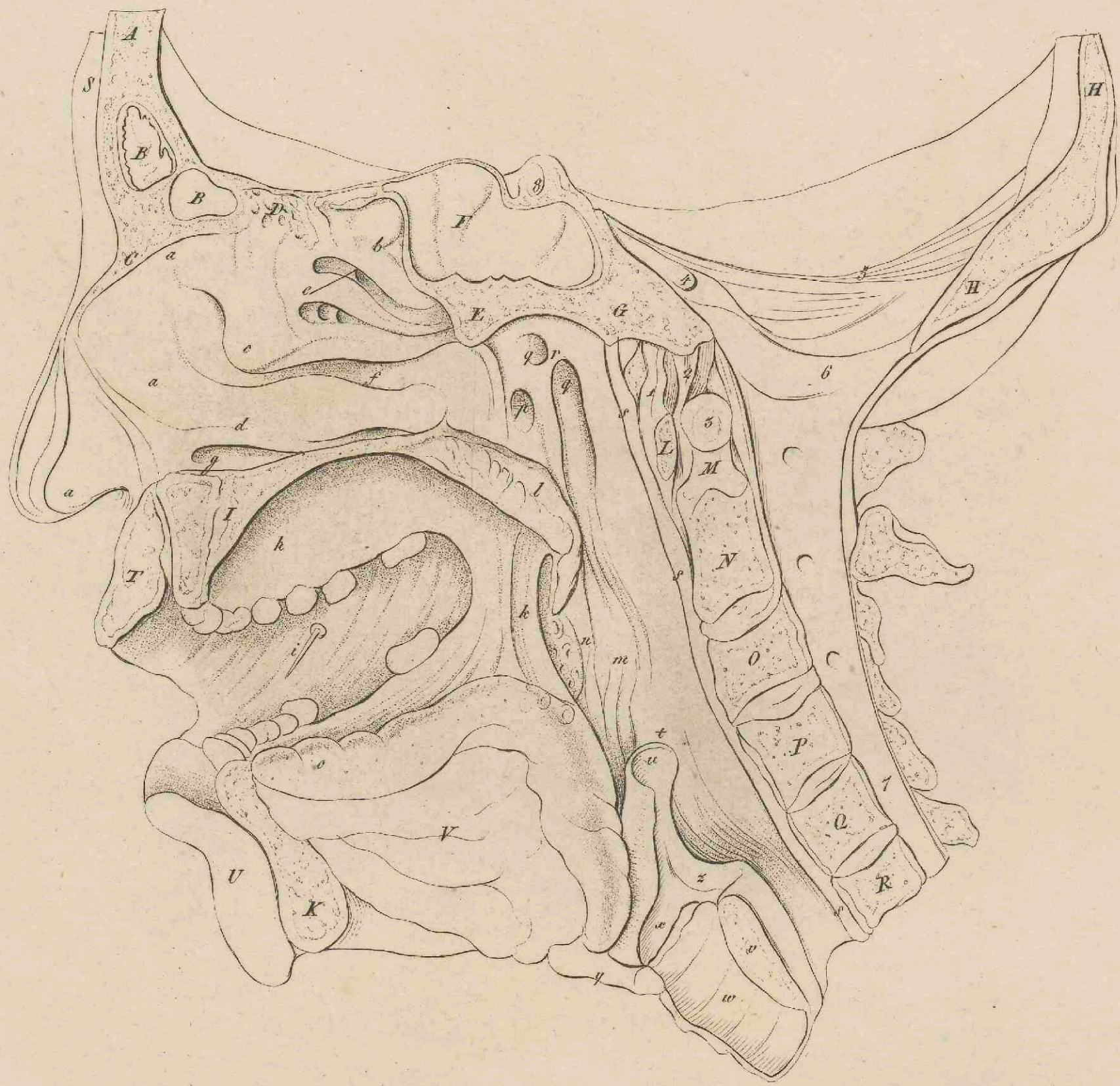

Fig. 2.

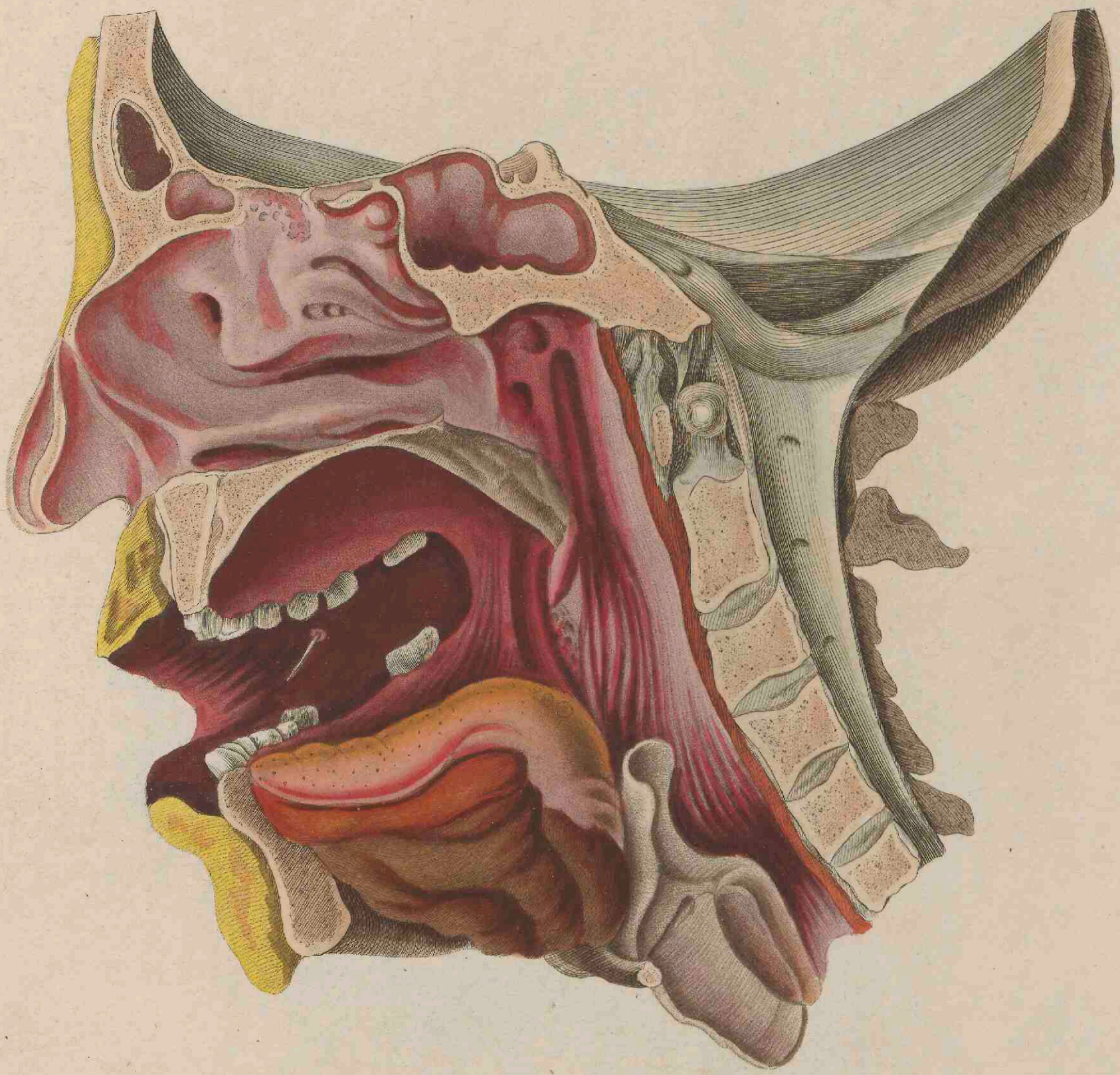






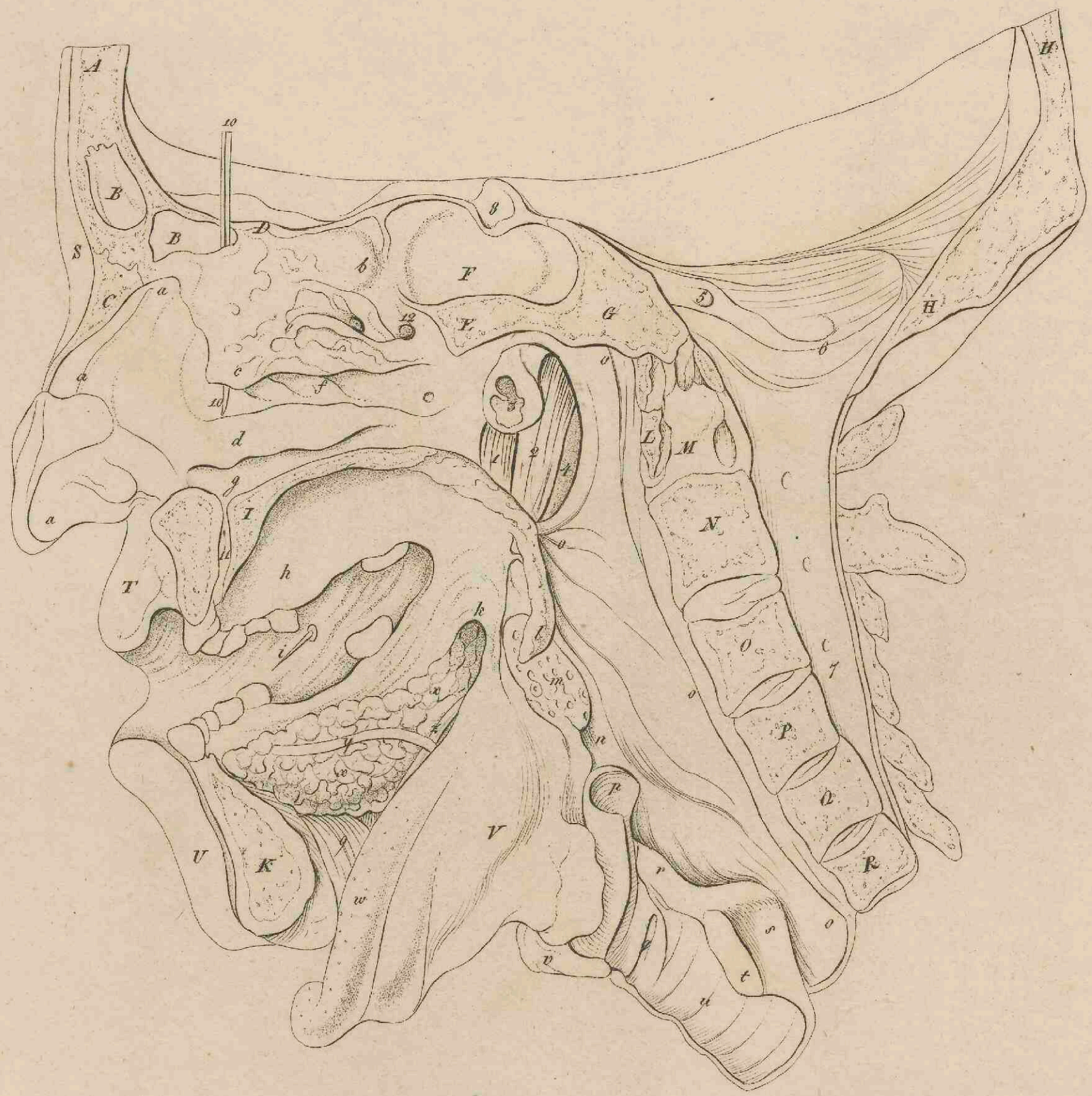


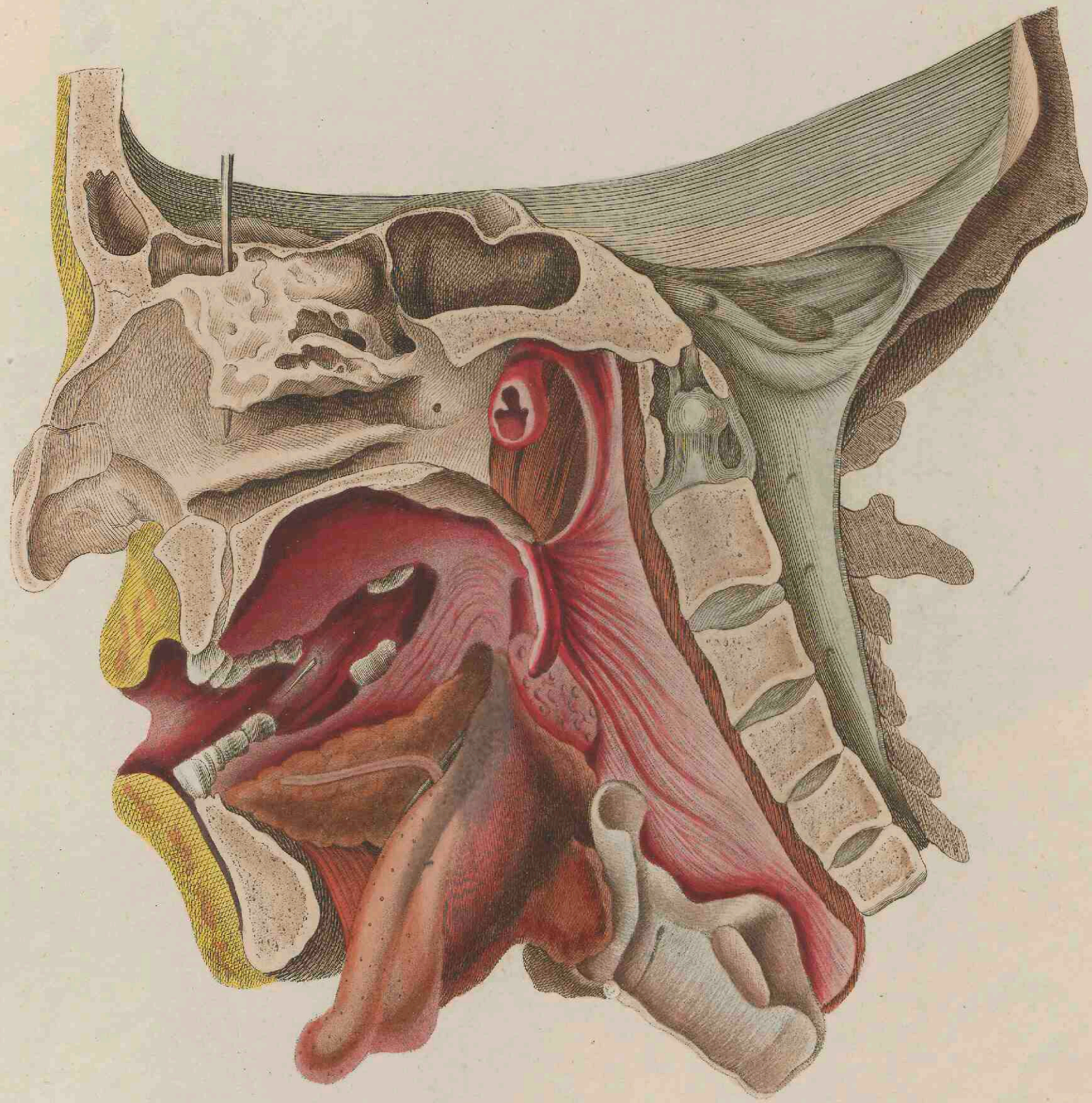
T. IV.



Rosenmüller. ad nat. del.

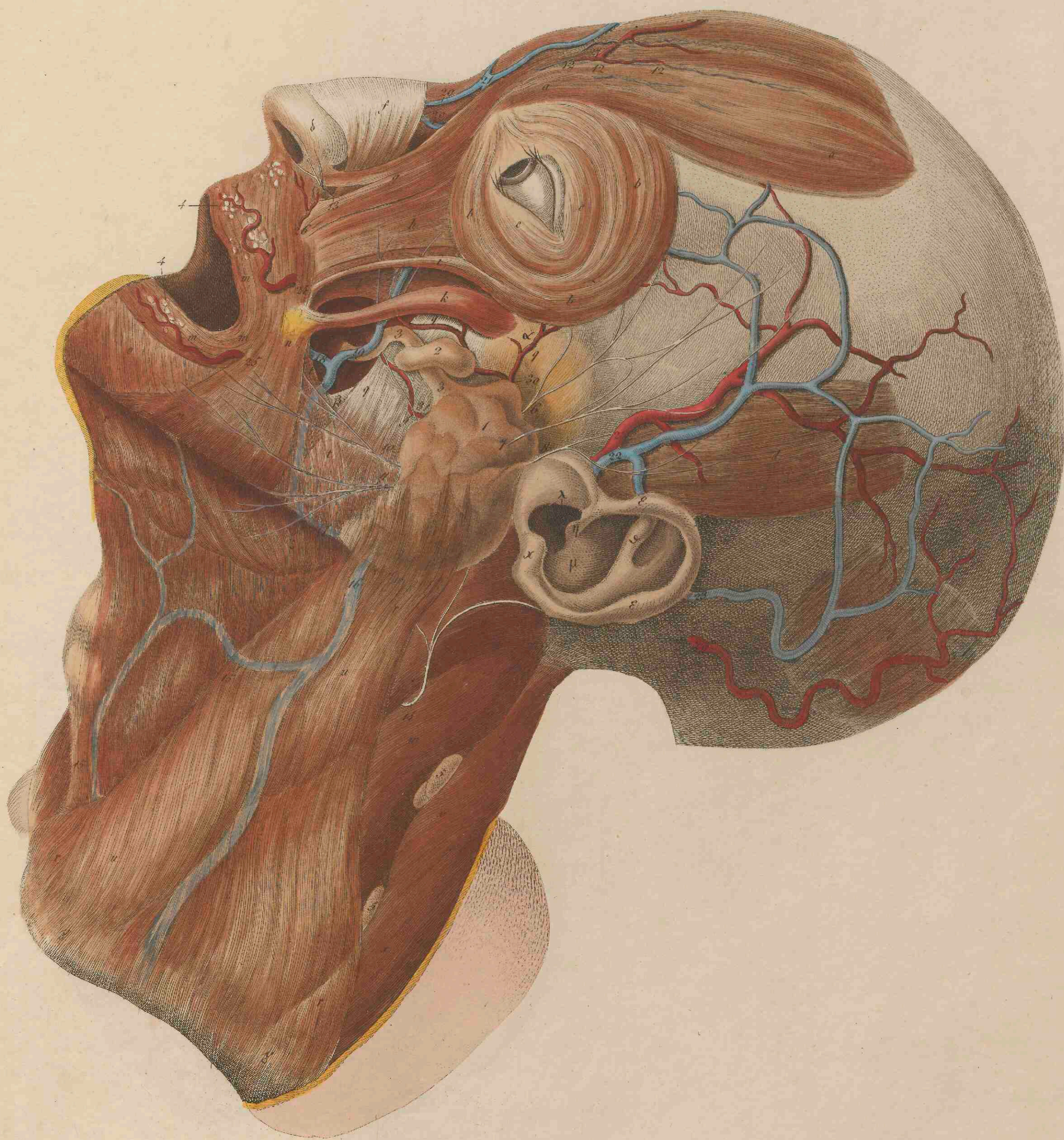
J. F. Schröter. sculp.





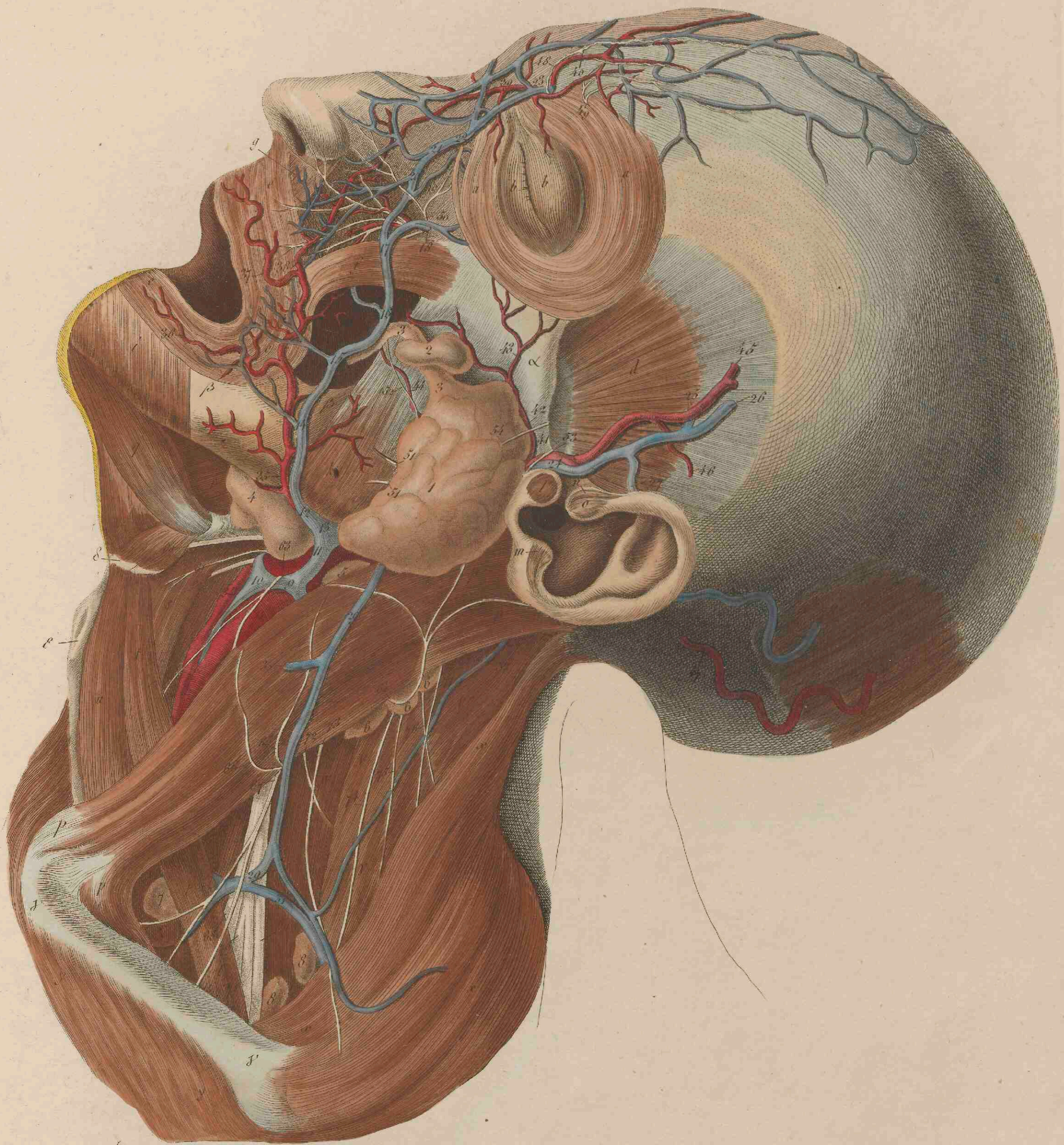
Profenmüller. del. nat. del.

J. F. Schröter. sculp.



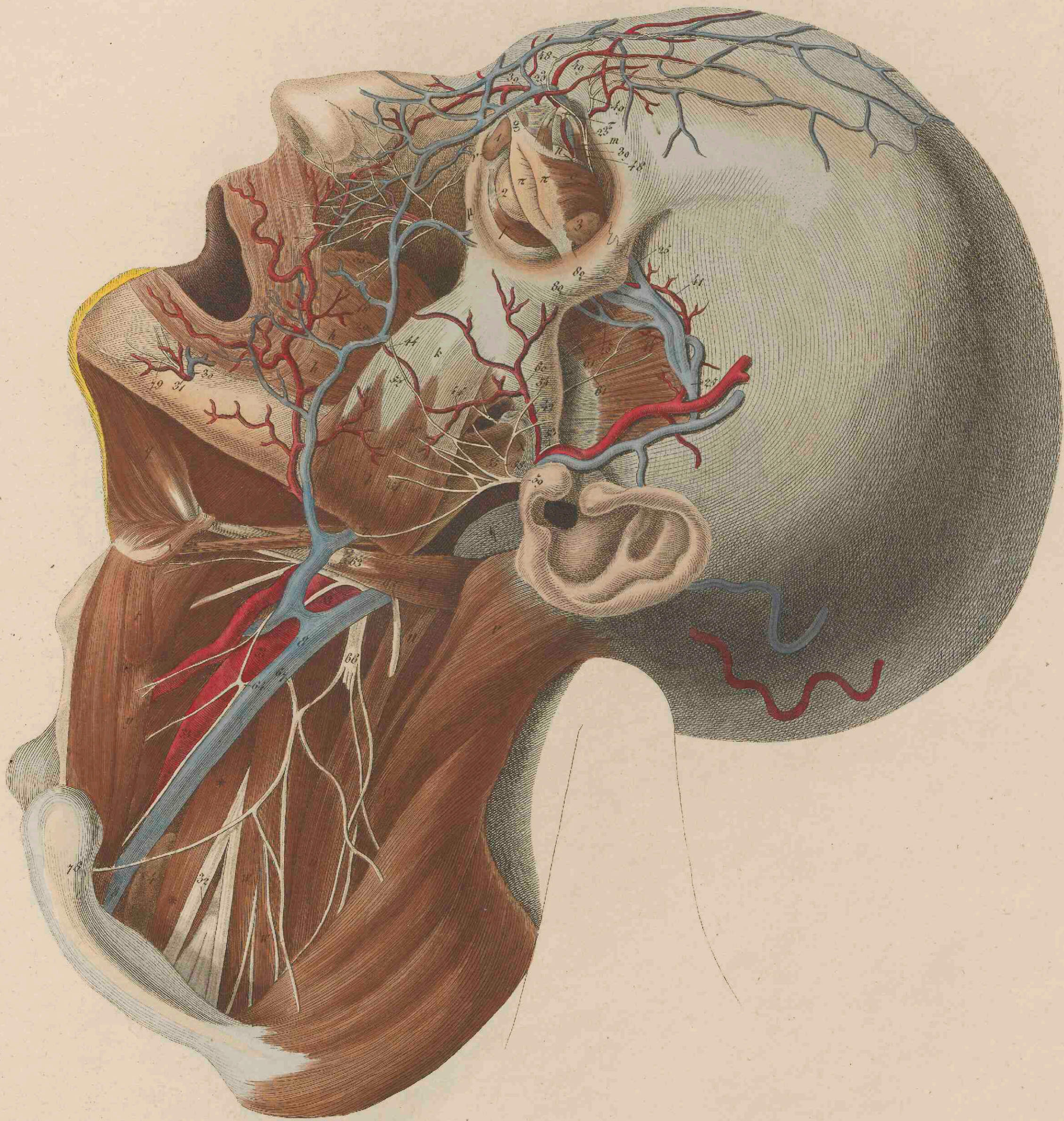
Rossmüller ad. nat. del.

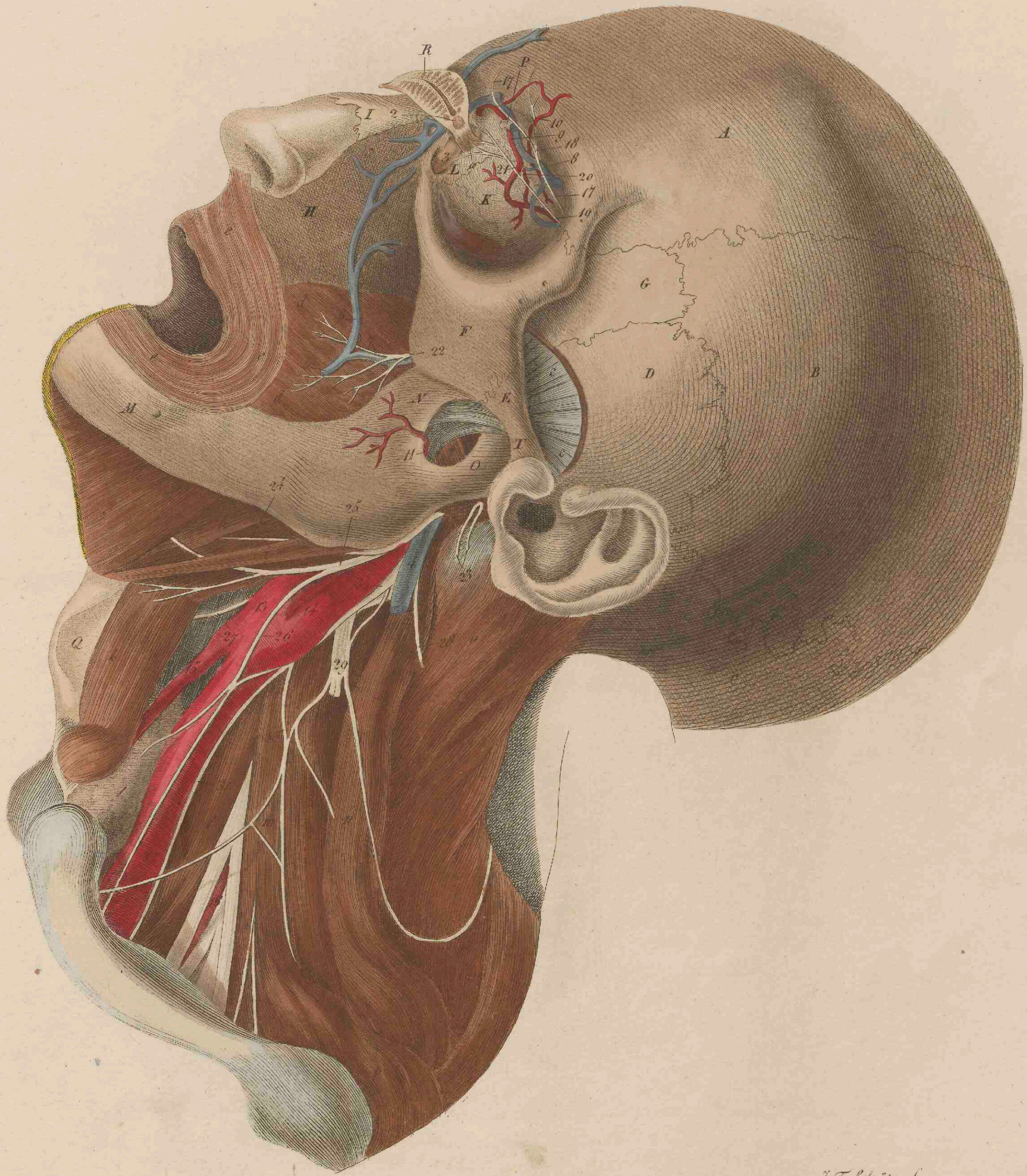
J. F. Schröter, sc. Lipsia.



Rosenmüller. ad nat. del.

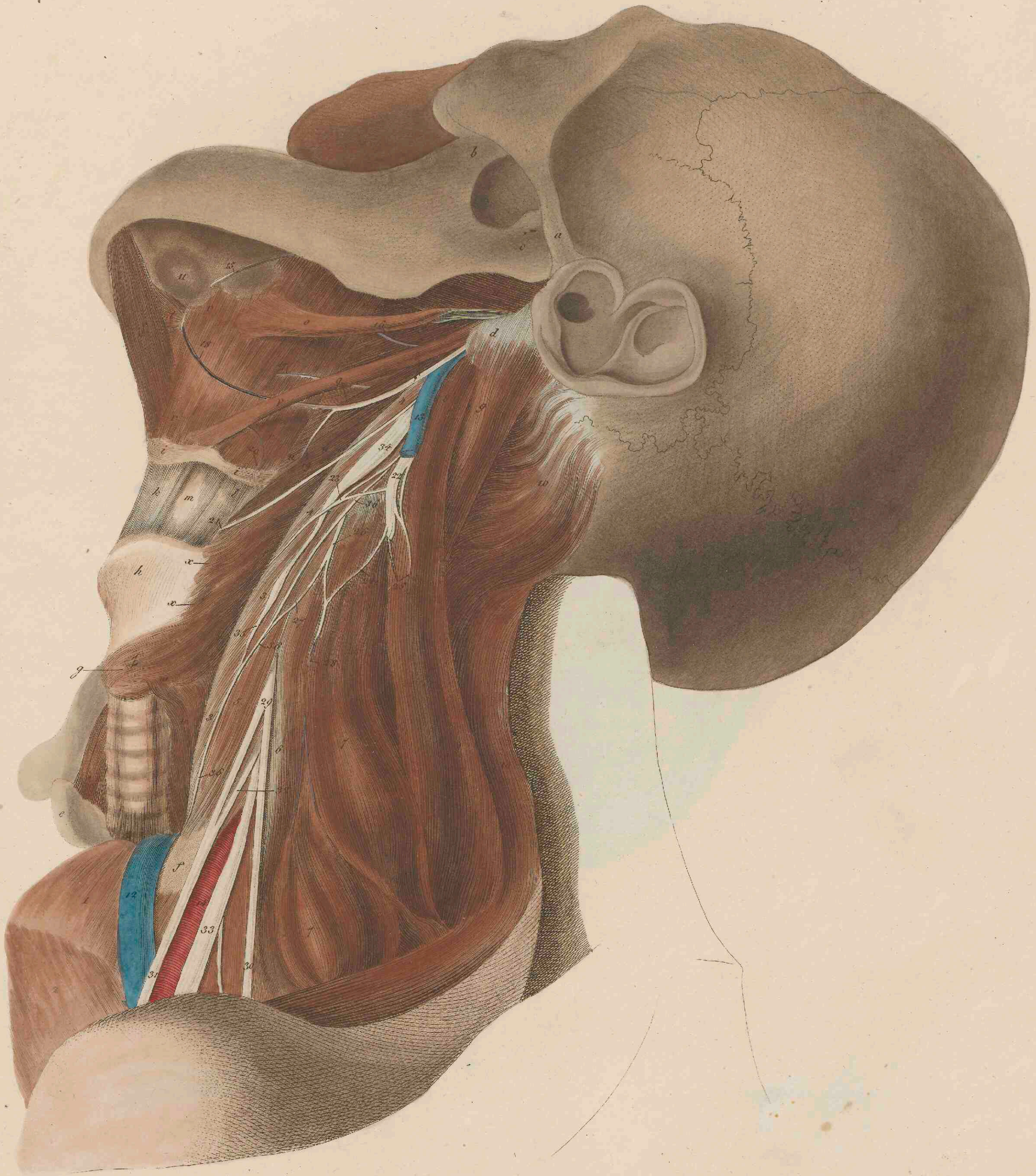
J. F. Schröter. Sc. Lips.

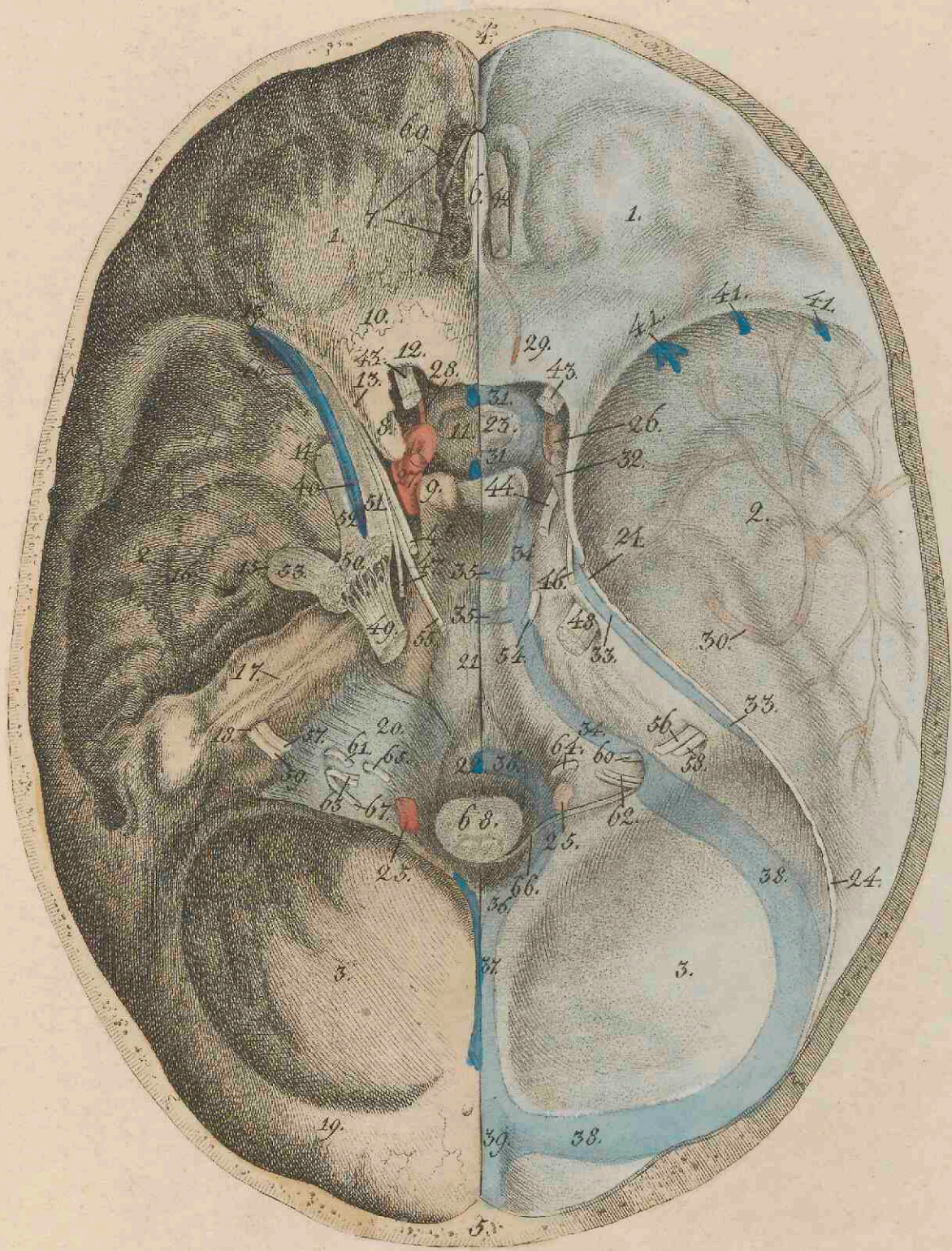




Rosenmüller ad nat. del.

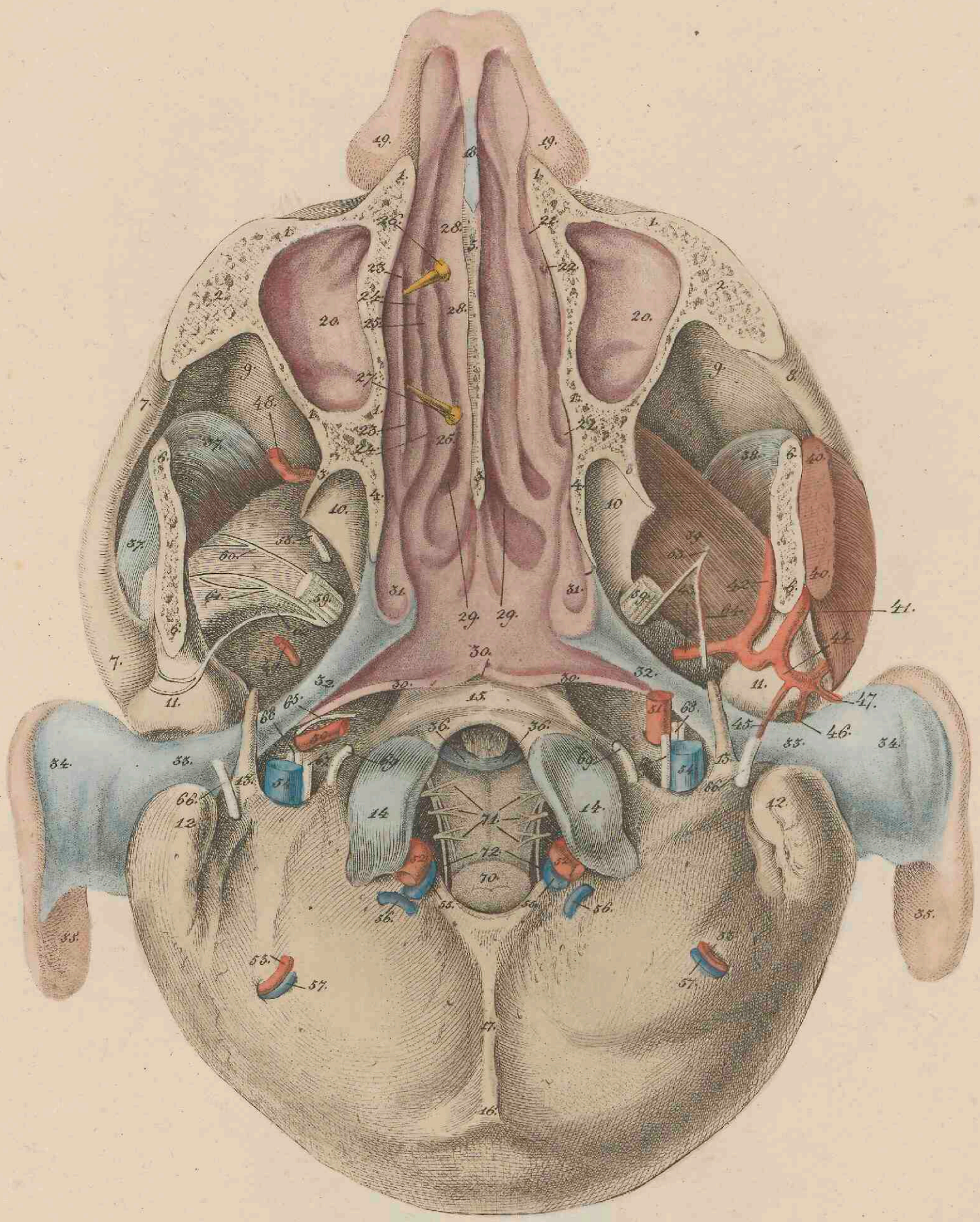
J. F. Schröter sc.





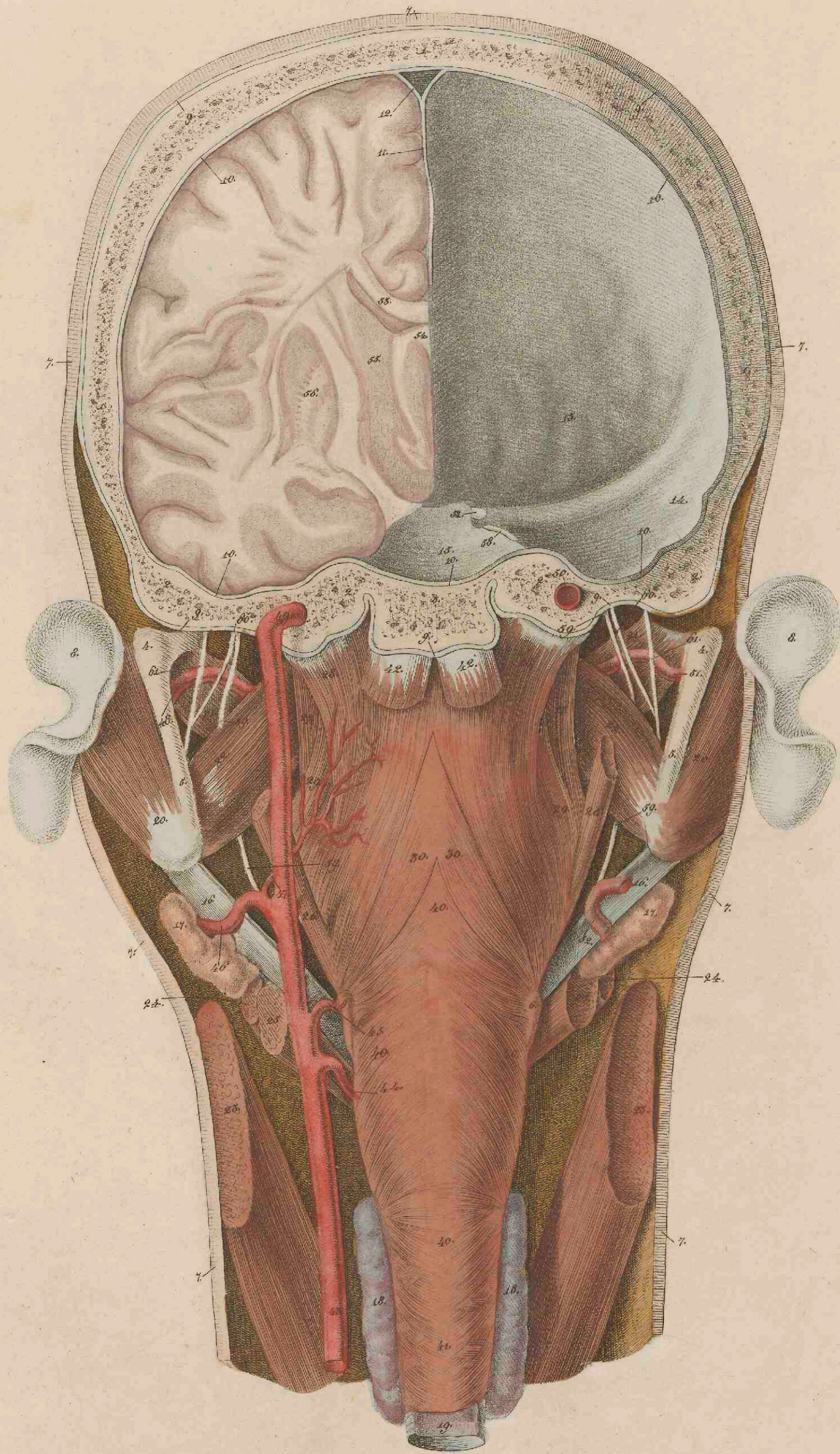
Rosenmüller. ad. not. del.

I. F. Schröter. sculps.



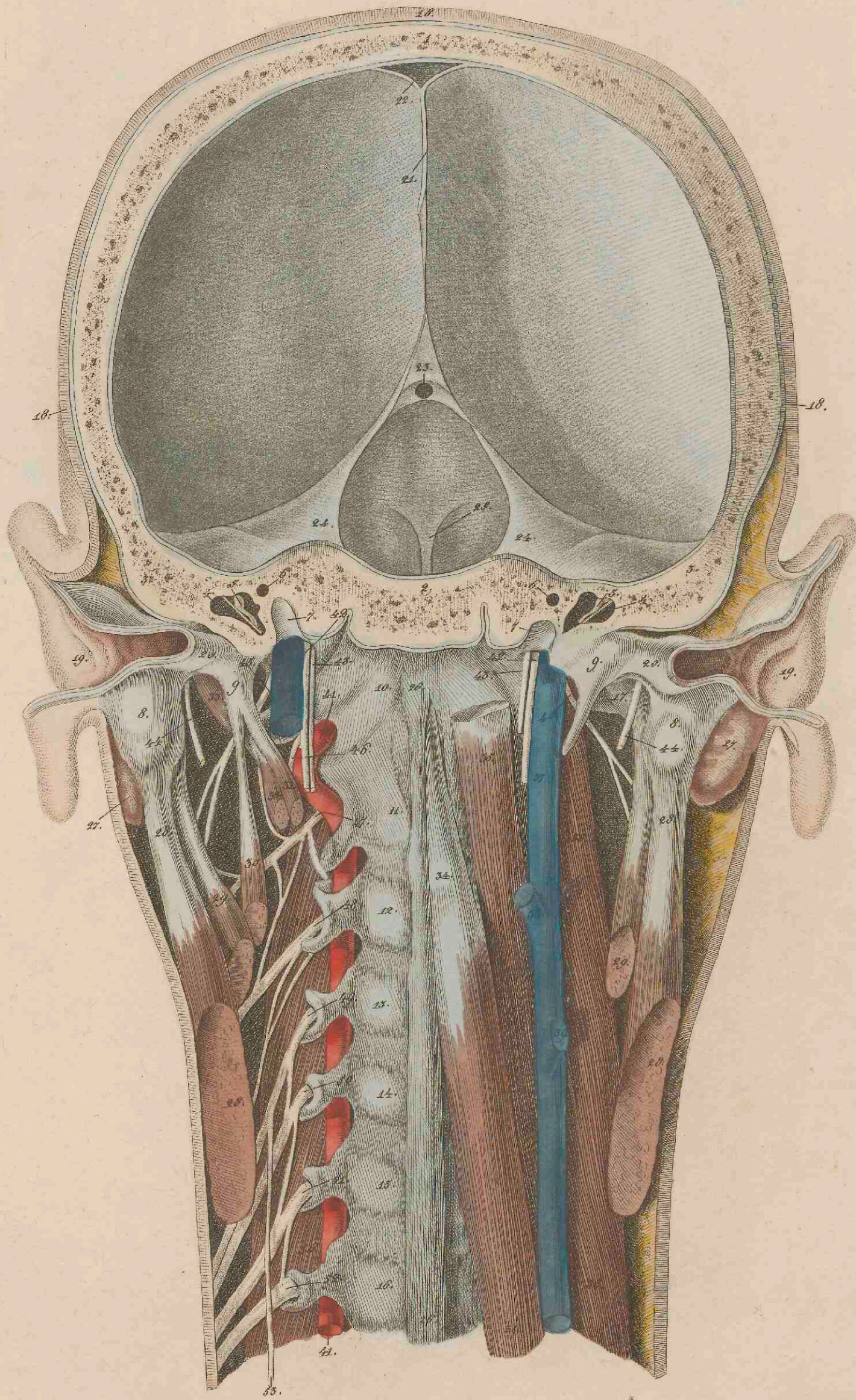
L. C. Rosenmüller ad. nat. del.

J. E. Schröten sculp.



I. C. Rosenmüller. ad. nat. del.

I. F. Schröder. sculp.



I. C. Rosenmüller. ad. nat. del.

I. F. Schröter. sculps.