



Chirurgisch-anatomische Abbildungen für Ärzte und Wundärzte

<https://hdl.handle.net/1874/284751>

J. C. Rosenmüllers

Chirurgisch - Anatomische

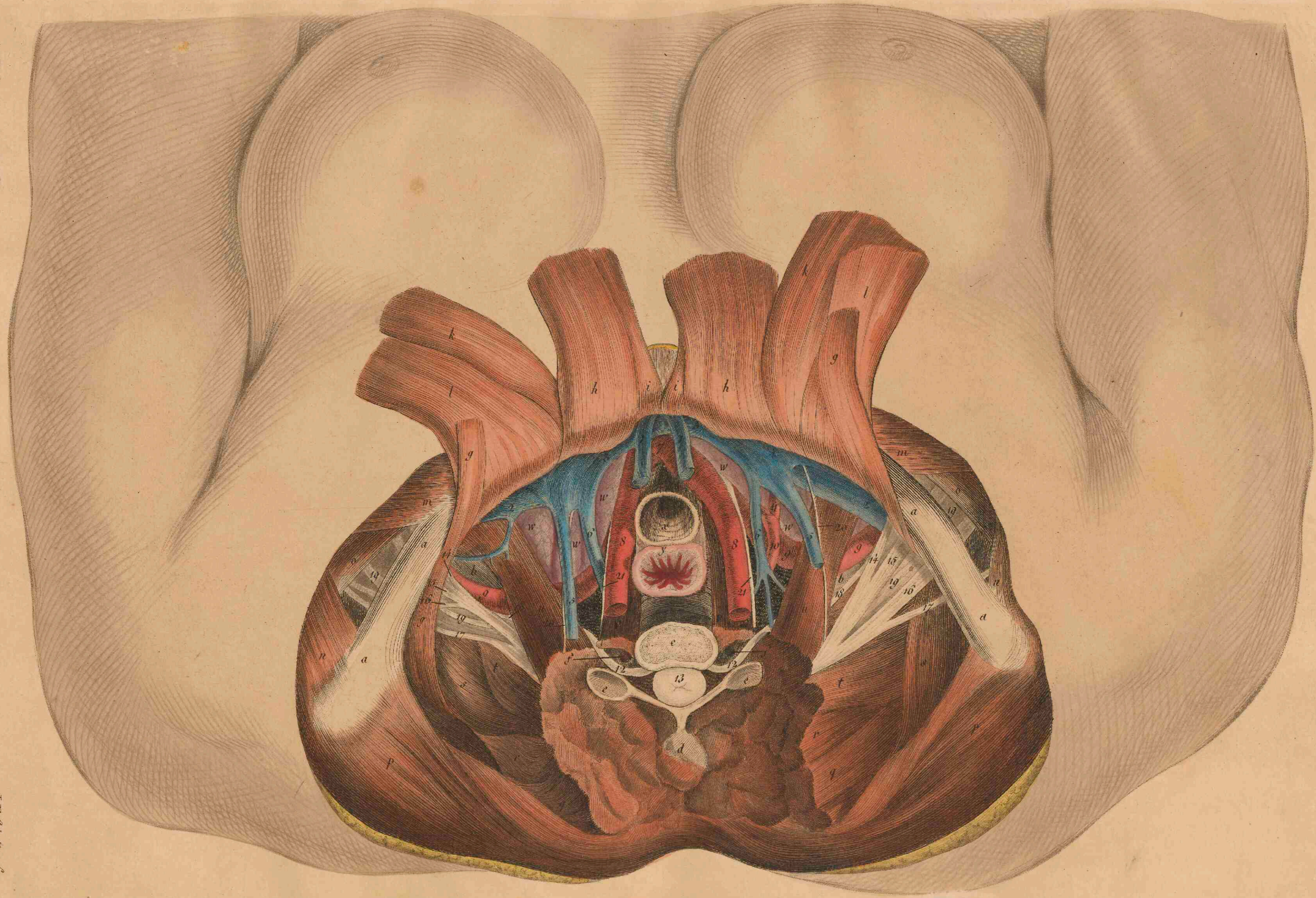
ABBILDUNGEN.

ZWEITER THEIL

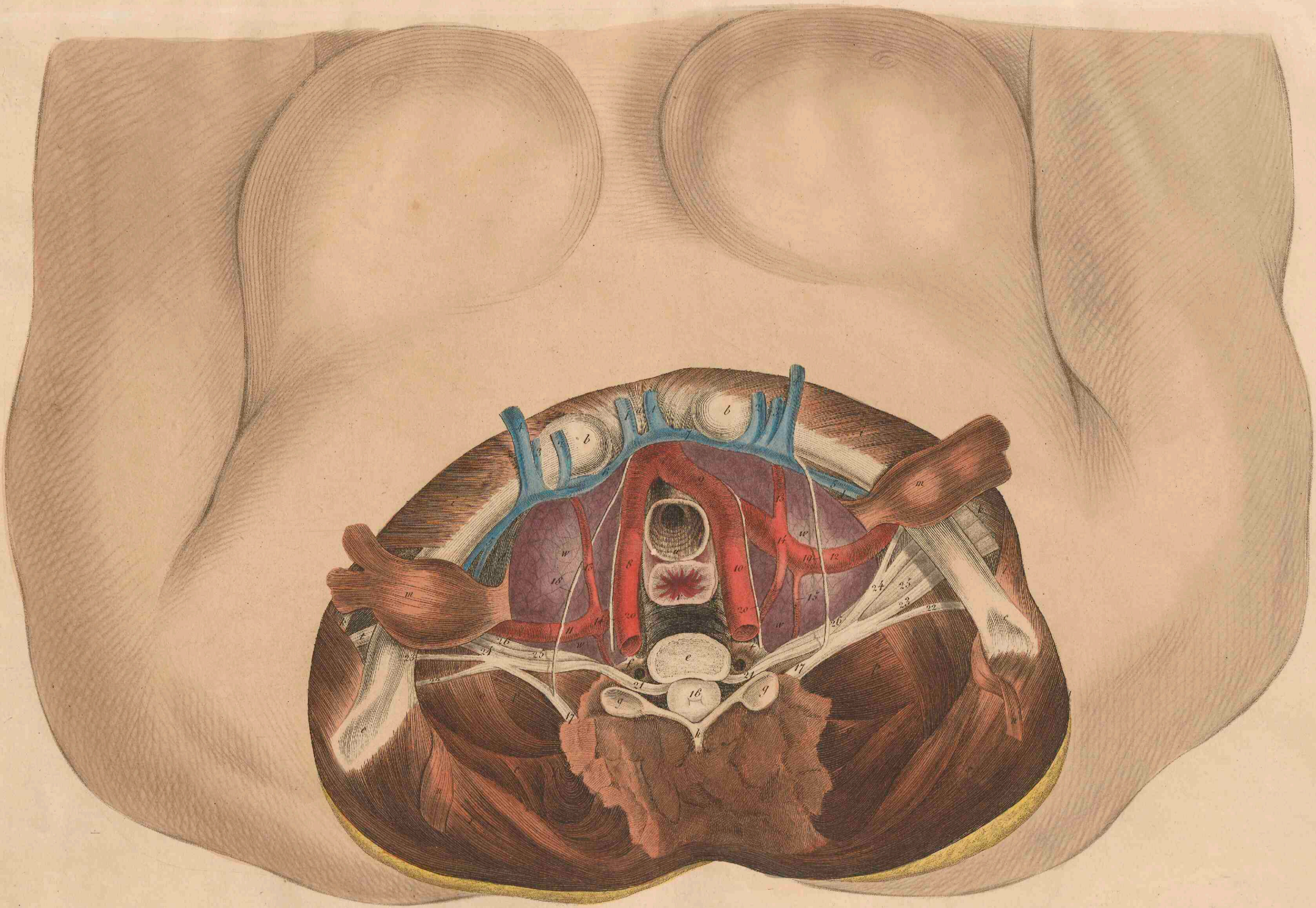
welcher die Theile der Brust und die Brustglieder
begreift.

I. Lieferung.

Respiration, cut. med. del.



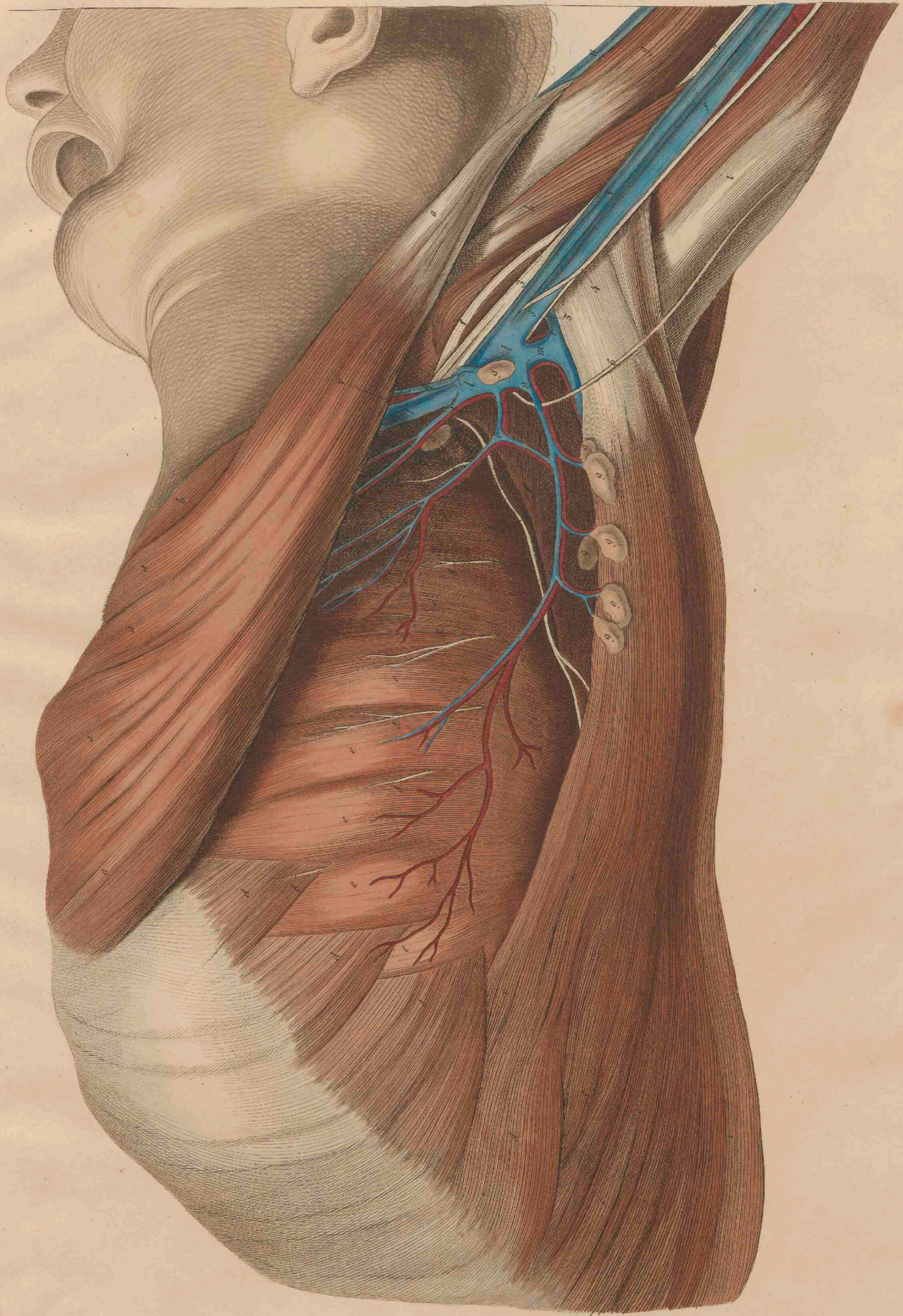
J. F. Schaefer, sc.

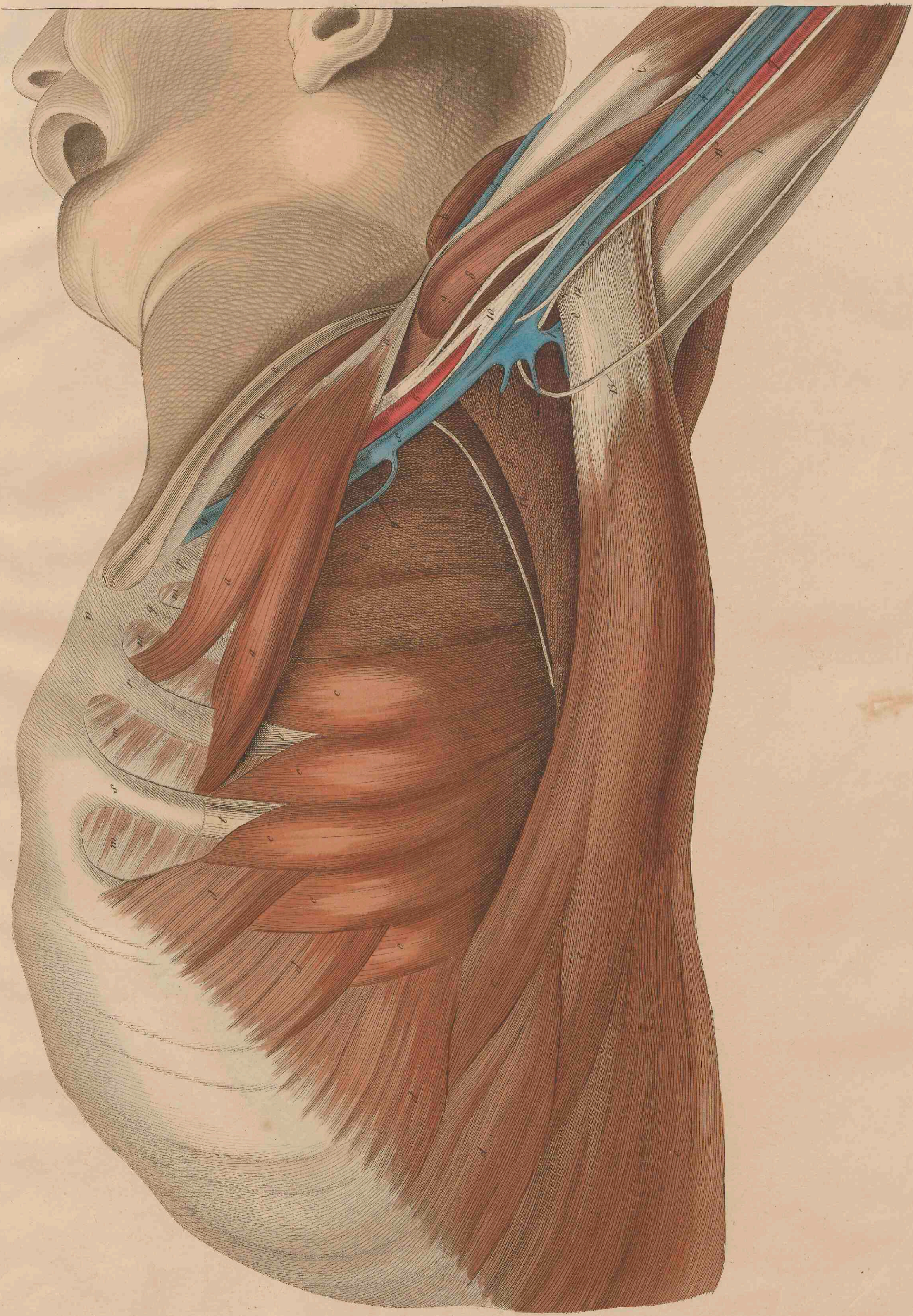


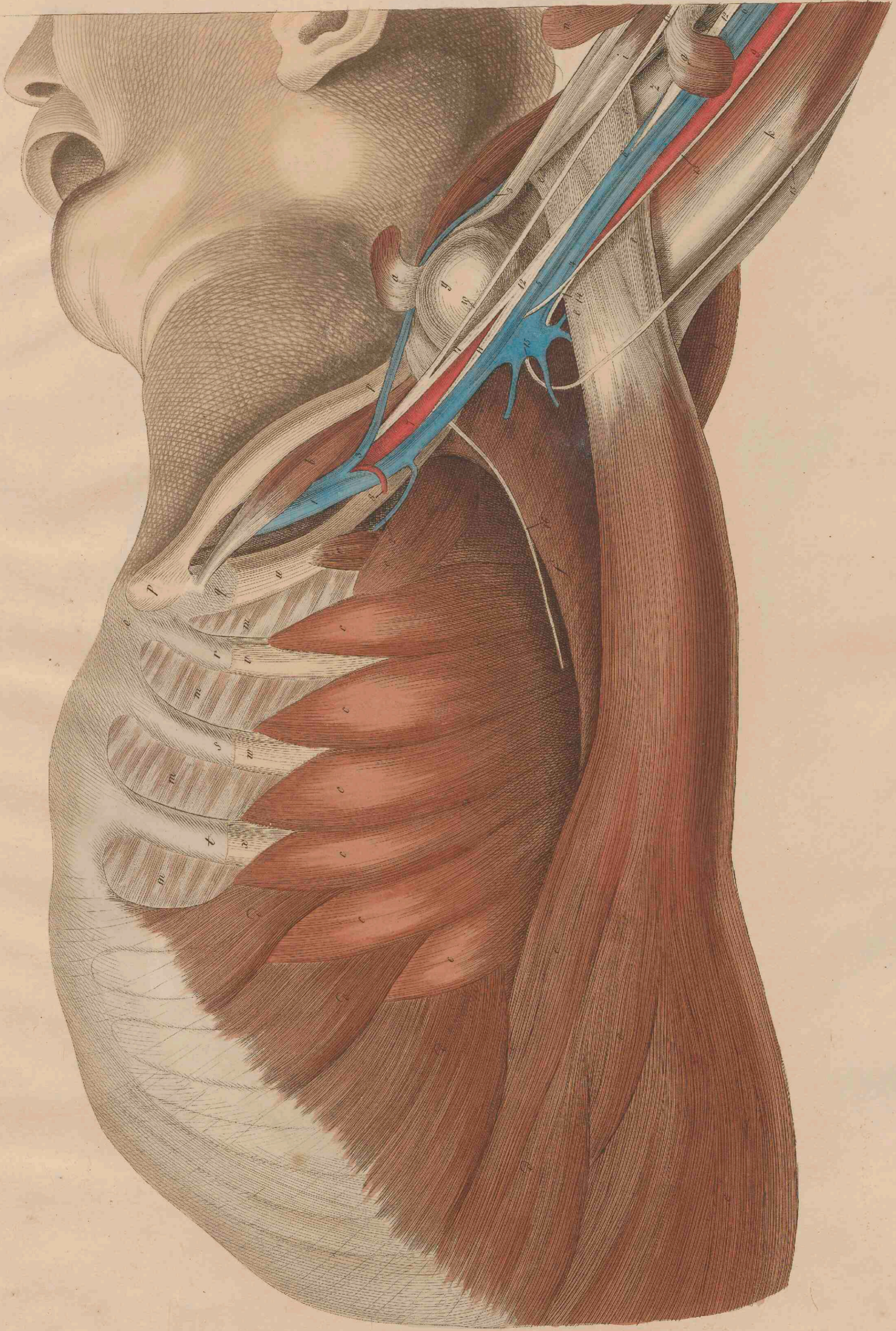
Resonator ad nat. 17.

J. P. Schöner junp.

T. II.

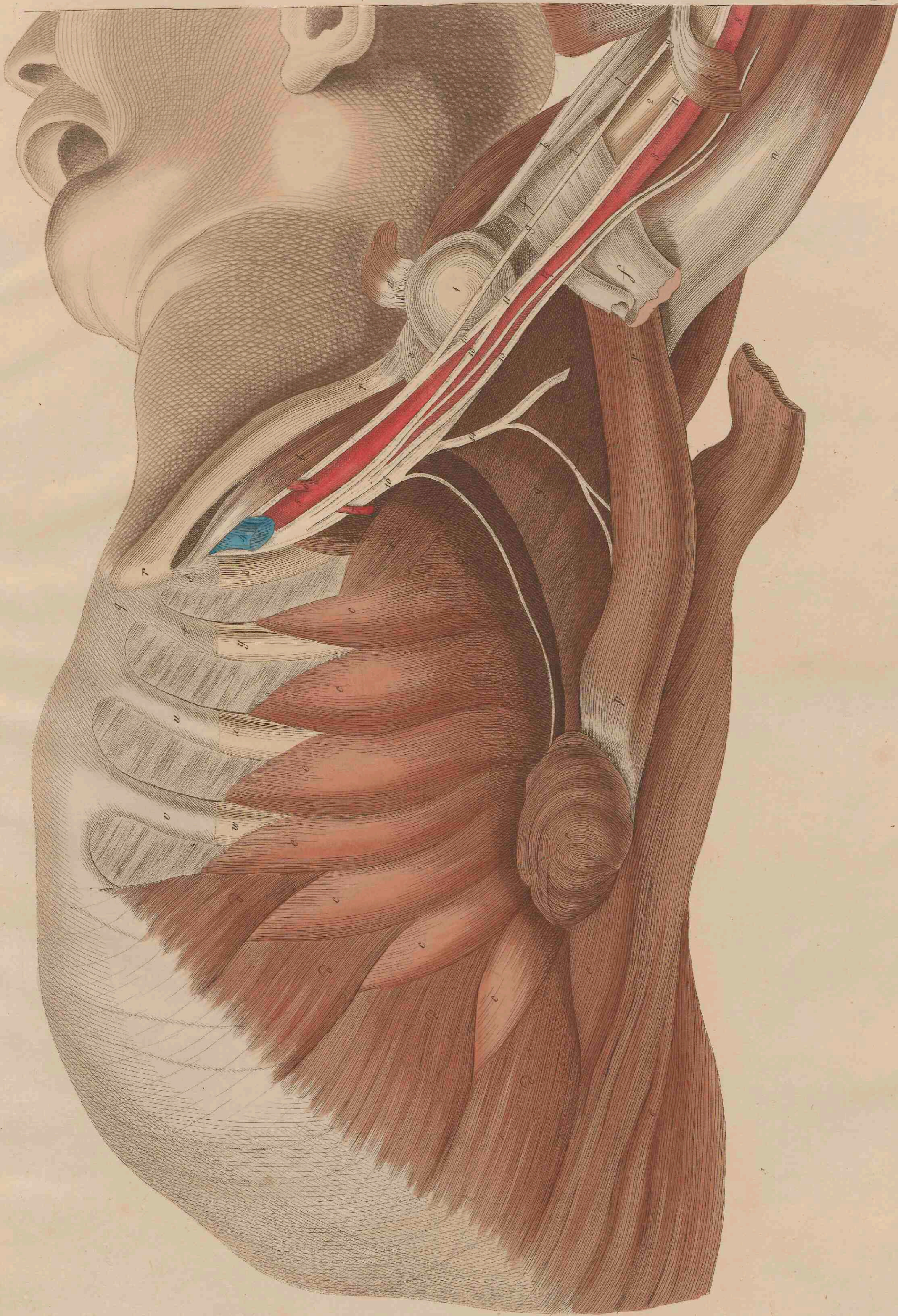






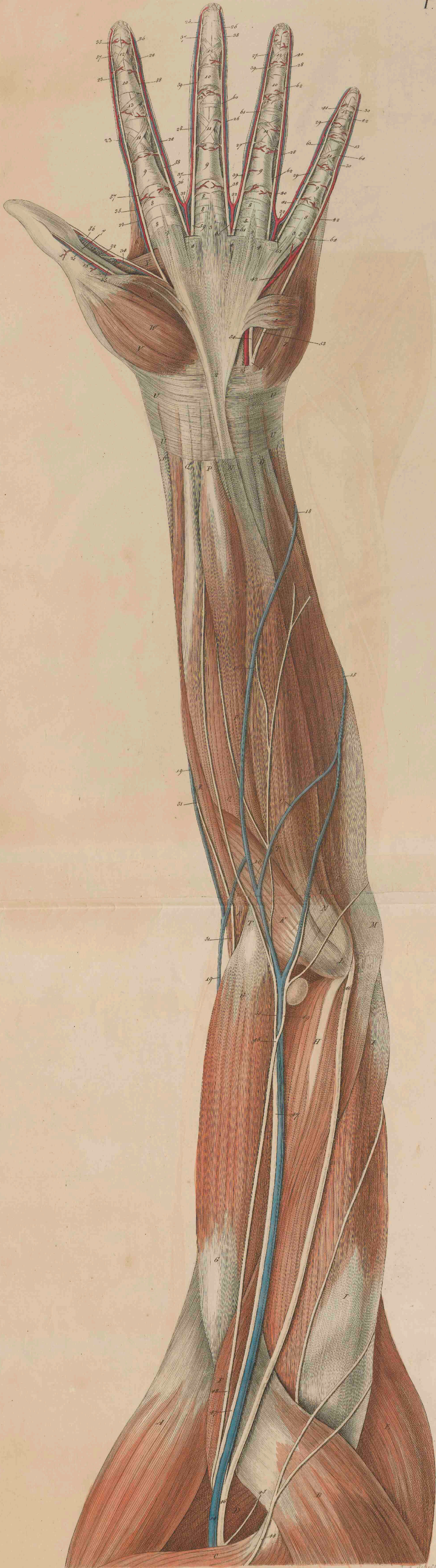
Rossmüller ad nat. del.

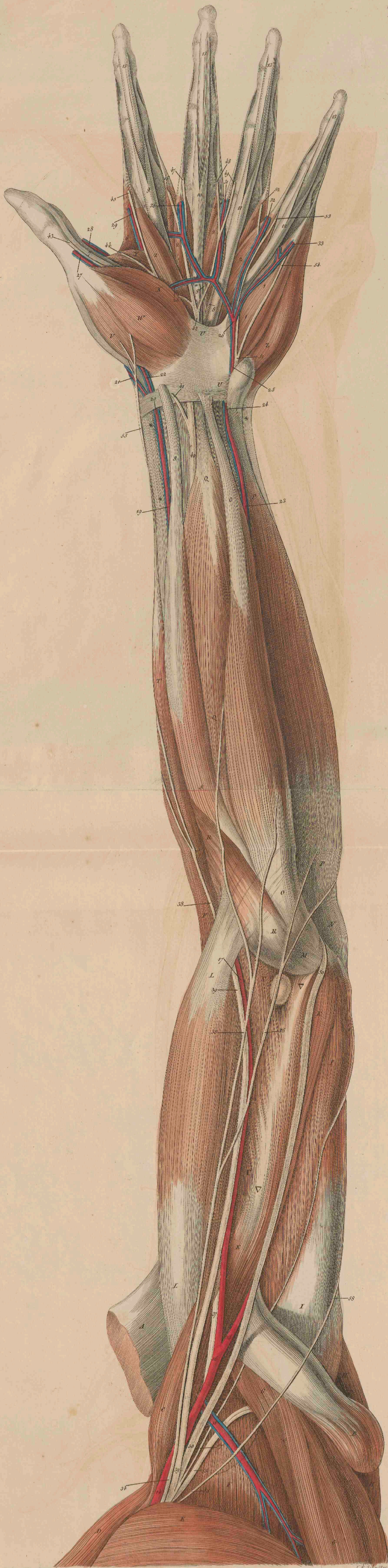J. F. Schröter sculp.



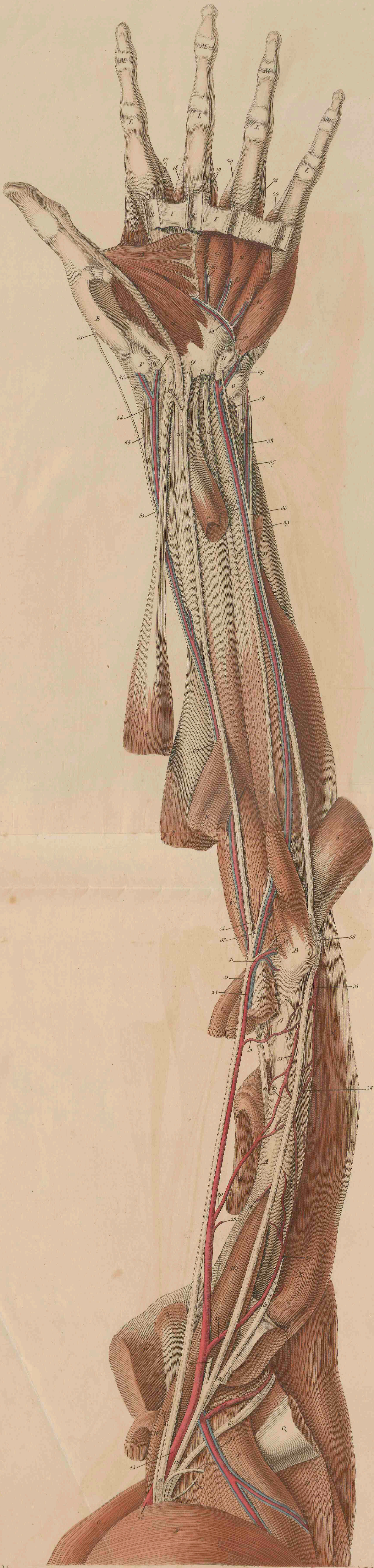
Borramillo ad nat. del.

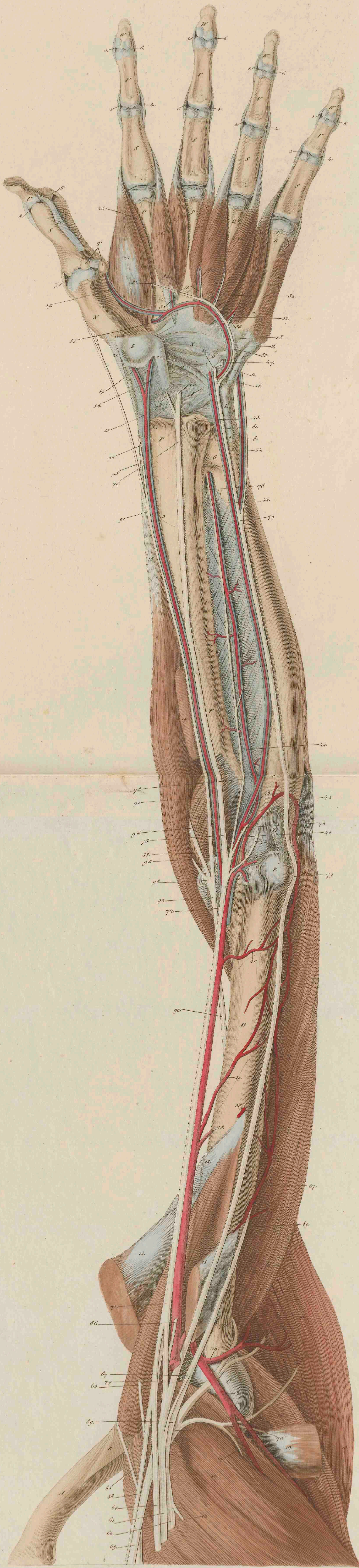
J.F. Schröder sculp.

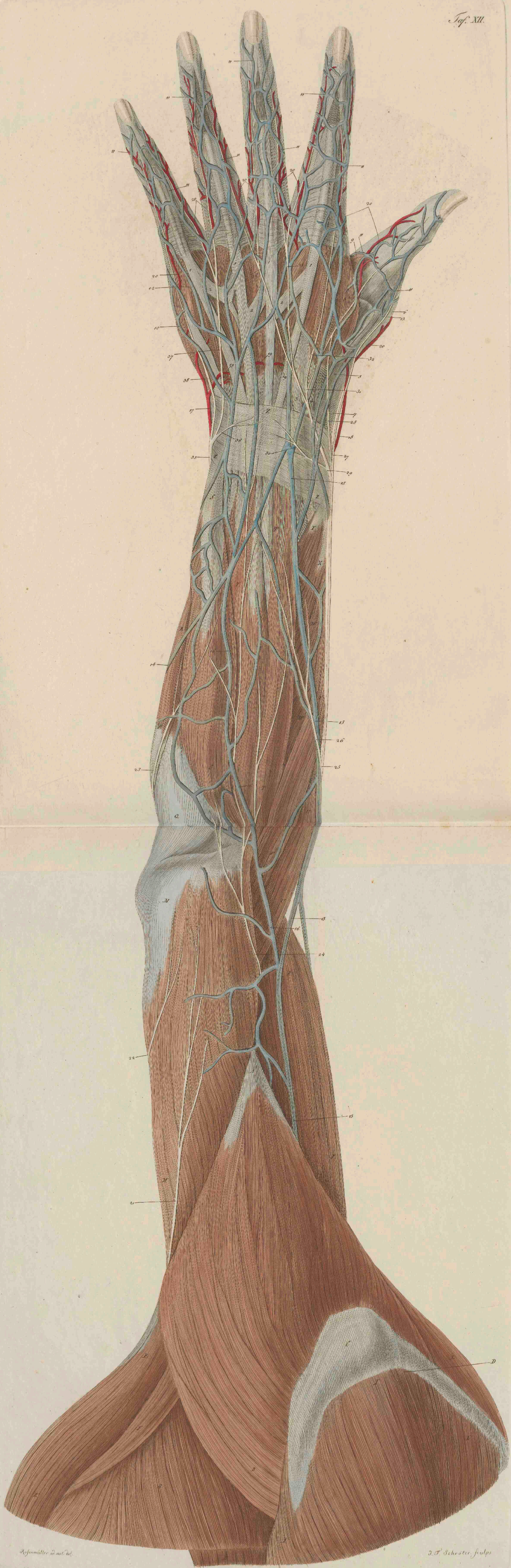


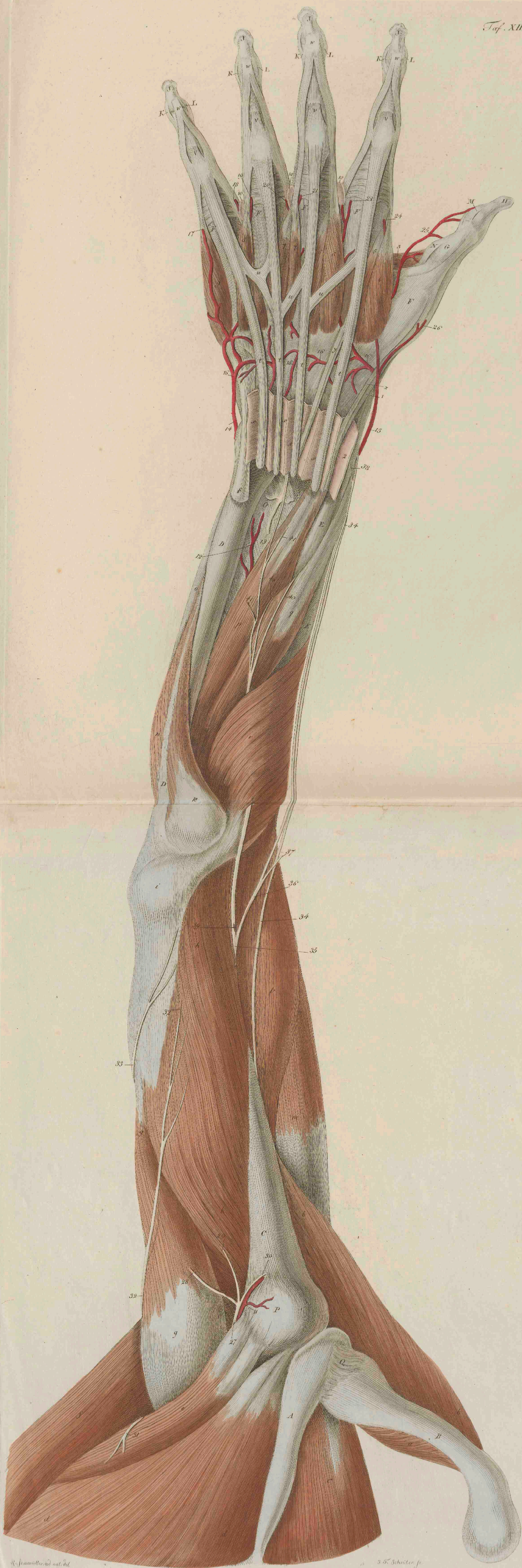


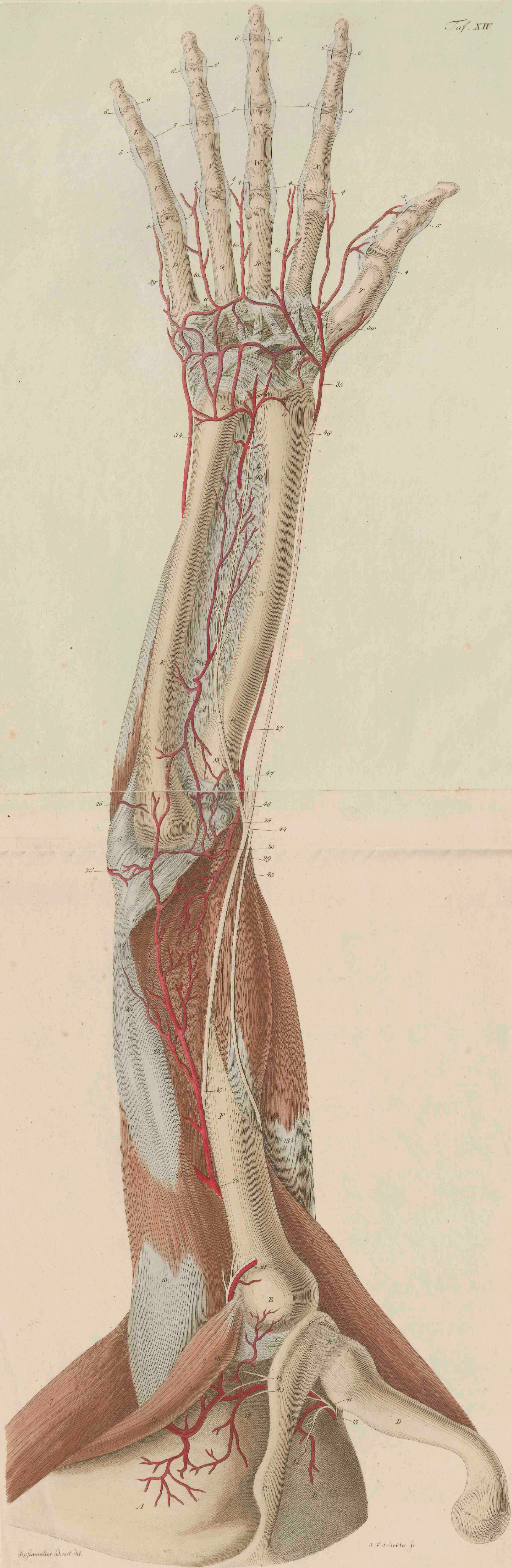


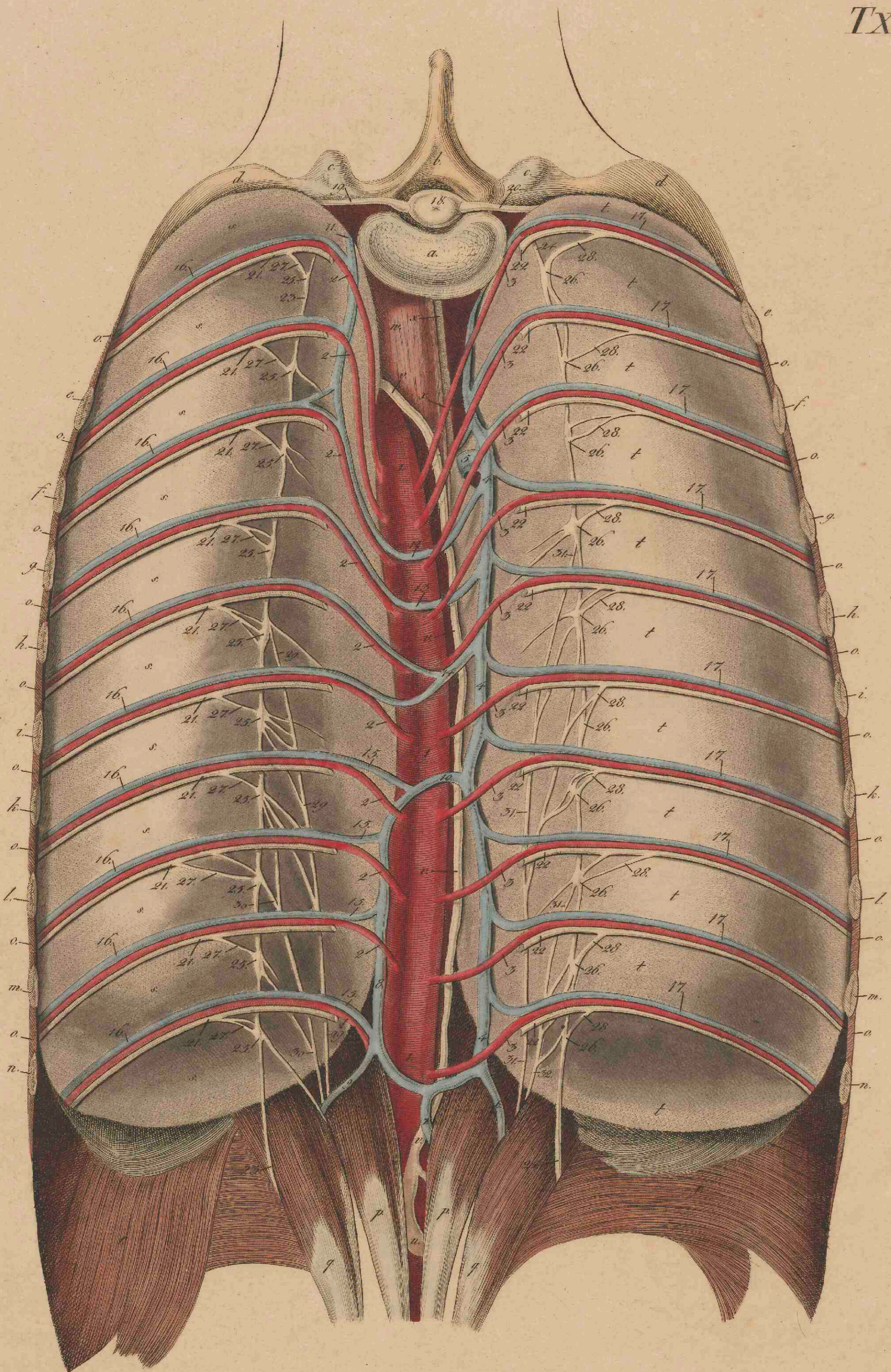










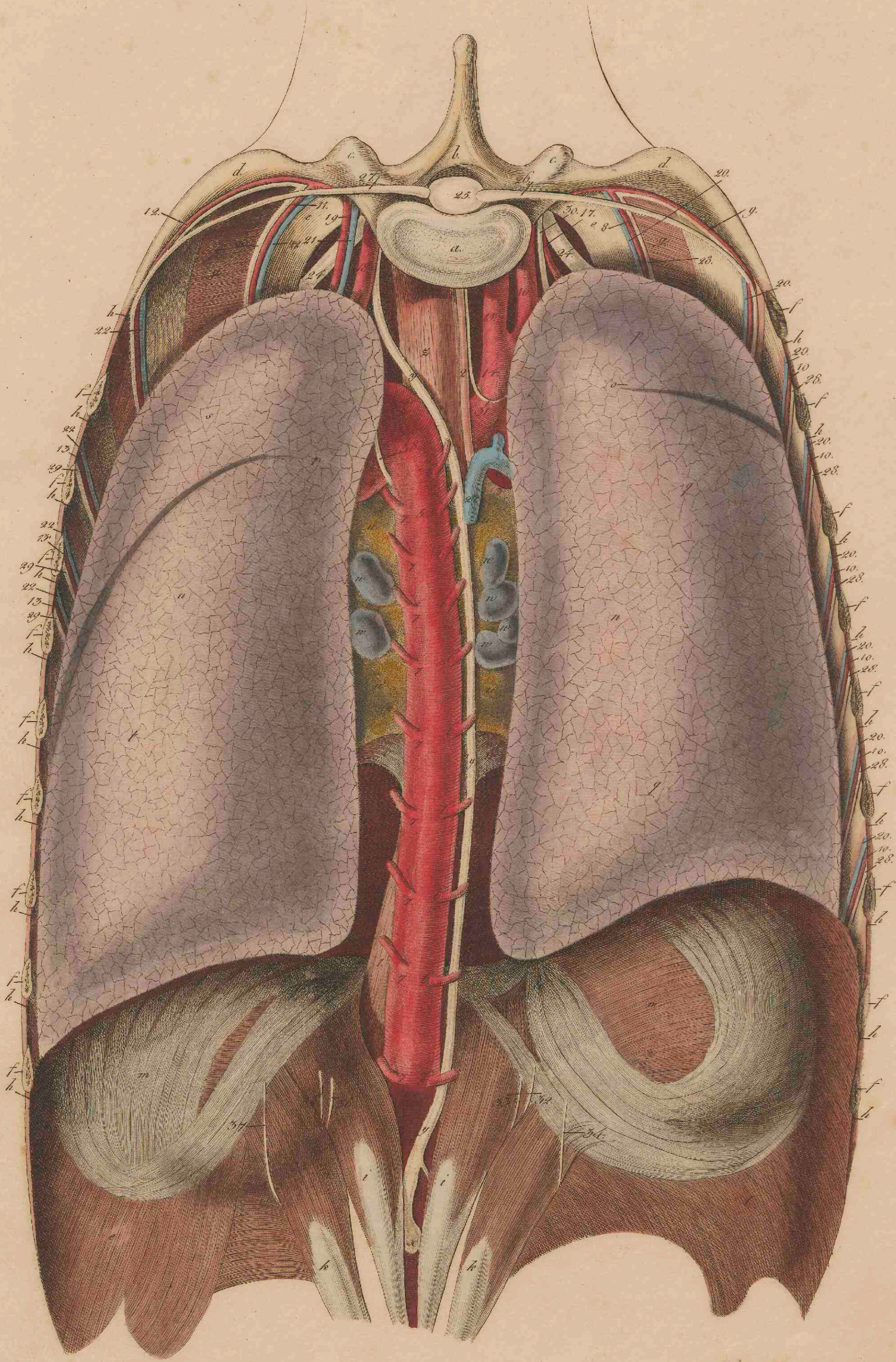


f
o
g
o
h
a
i
o
h
o
l
o
m
a
n

a
f
a
g
h
i
a
h
a
m
a
n

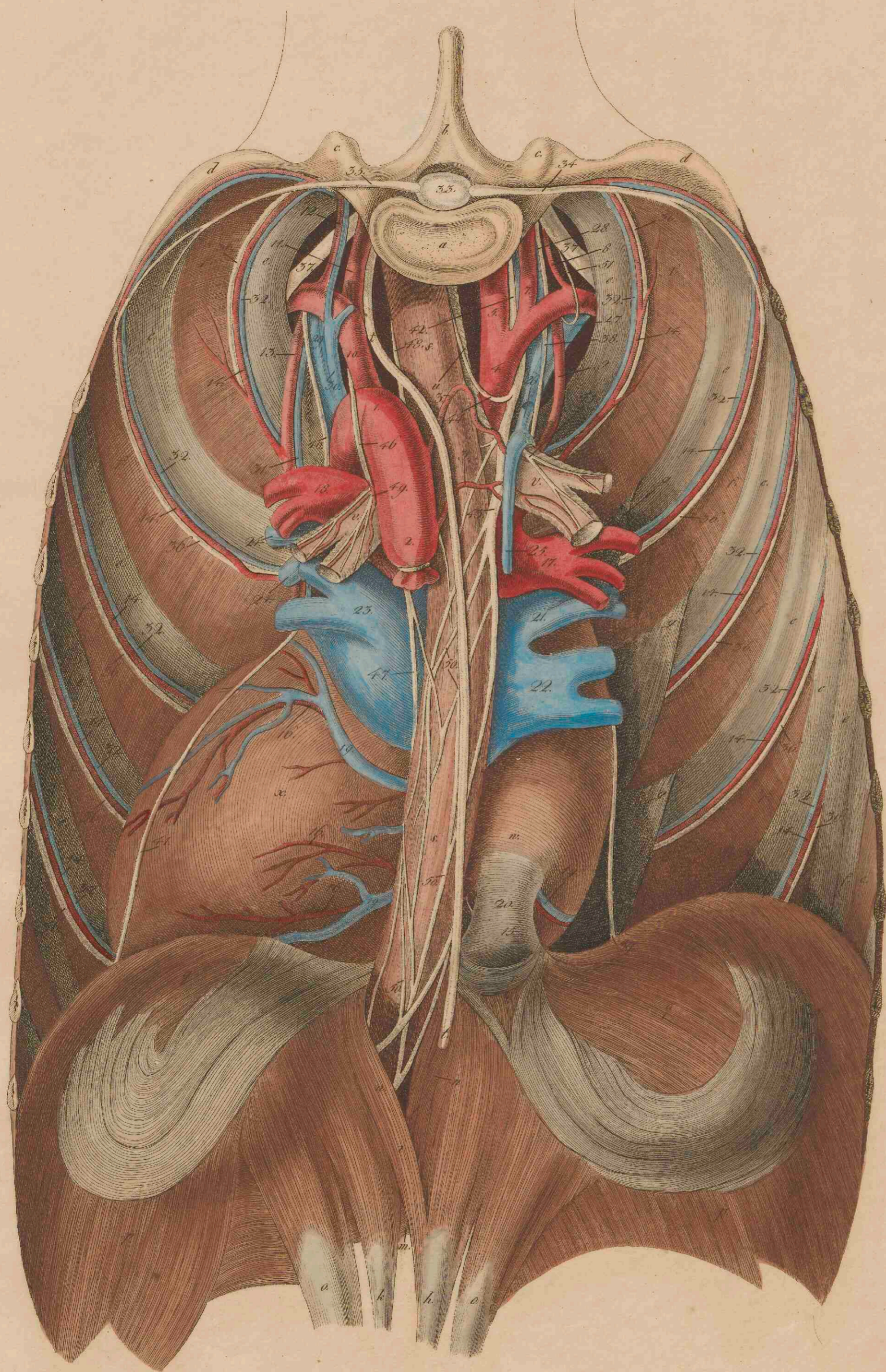
Rosenmüller ad nat. del.

J.E. Schröter sculp.



Rosenmüller ad nat. del.

J. E. Schröter sculp.



Rosenmüller ad nat. del.

J.E. Schroter sculp.

