



Chirurgisch-anatomische Abbildungen für Ärzte und Wundärzte

<https://hdl.handle.net/1874/284752>

J. C. Rosenmüllers

Chirurgisch - Anatomische

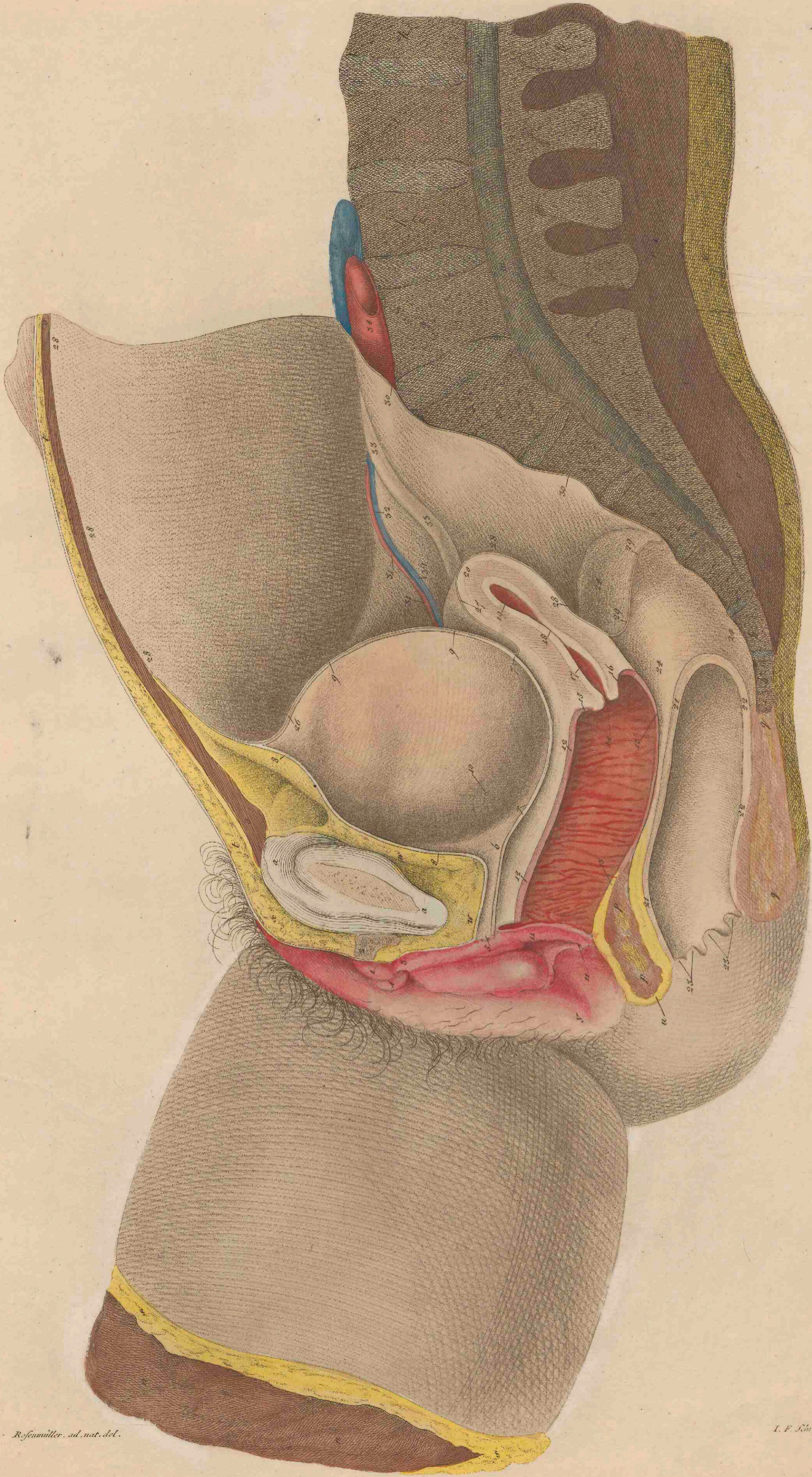
ABBILDUNGEN.

DRITTER THEIL

welcher die Theile des Bauches und die Bauch-
glieder begreift.

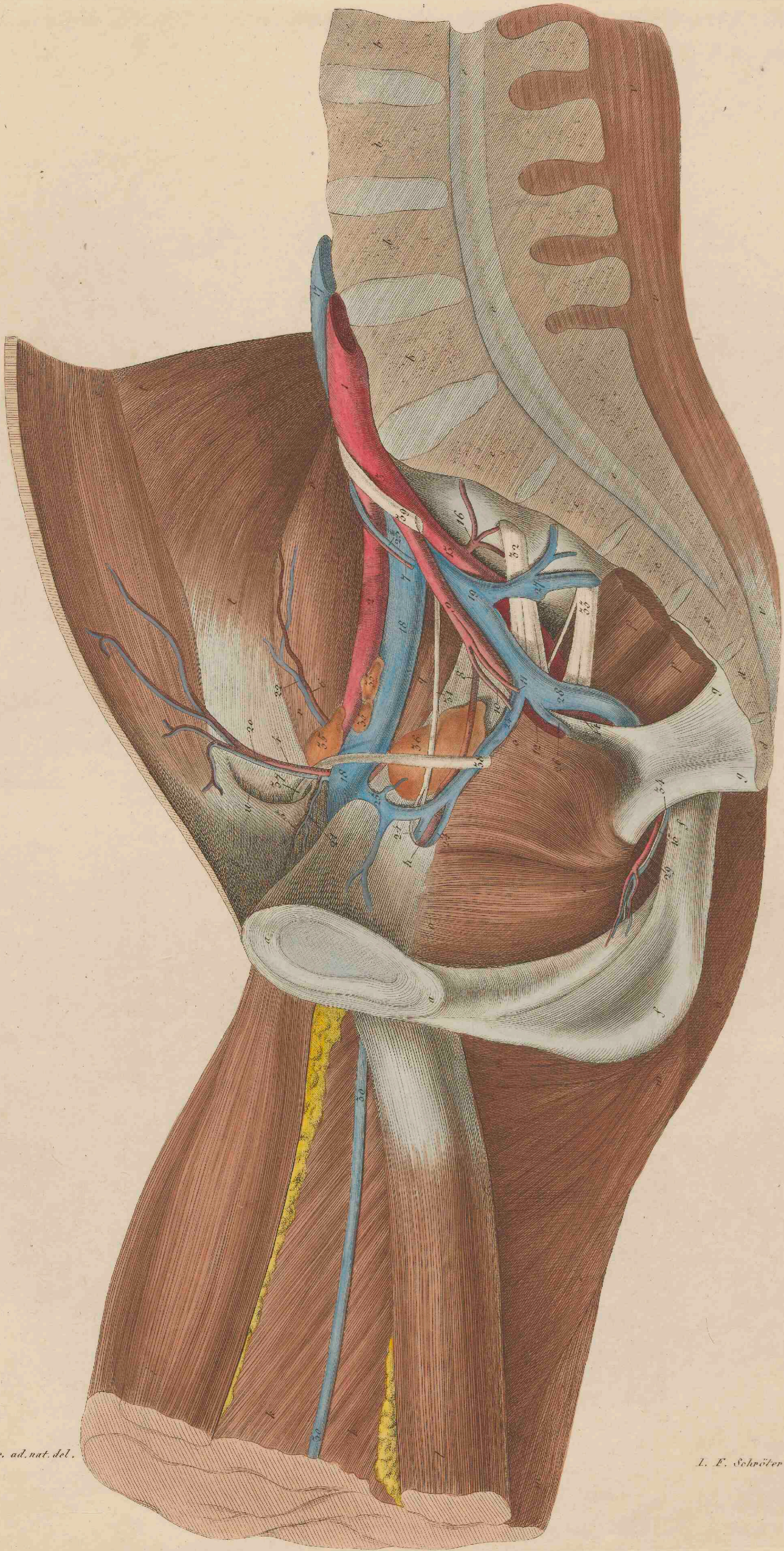
I. Lieferung.

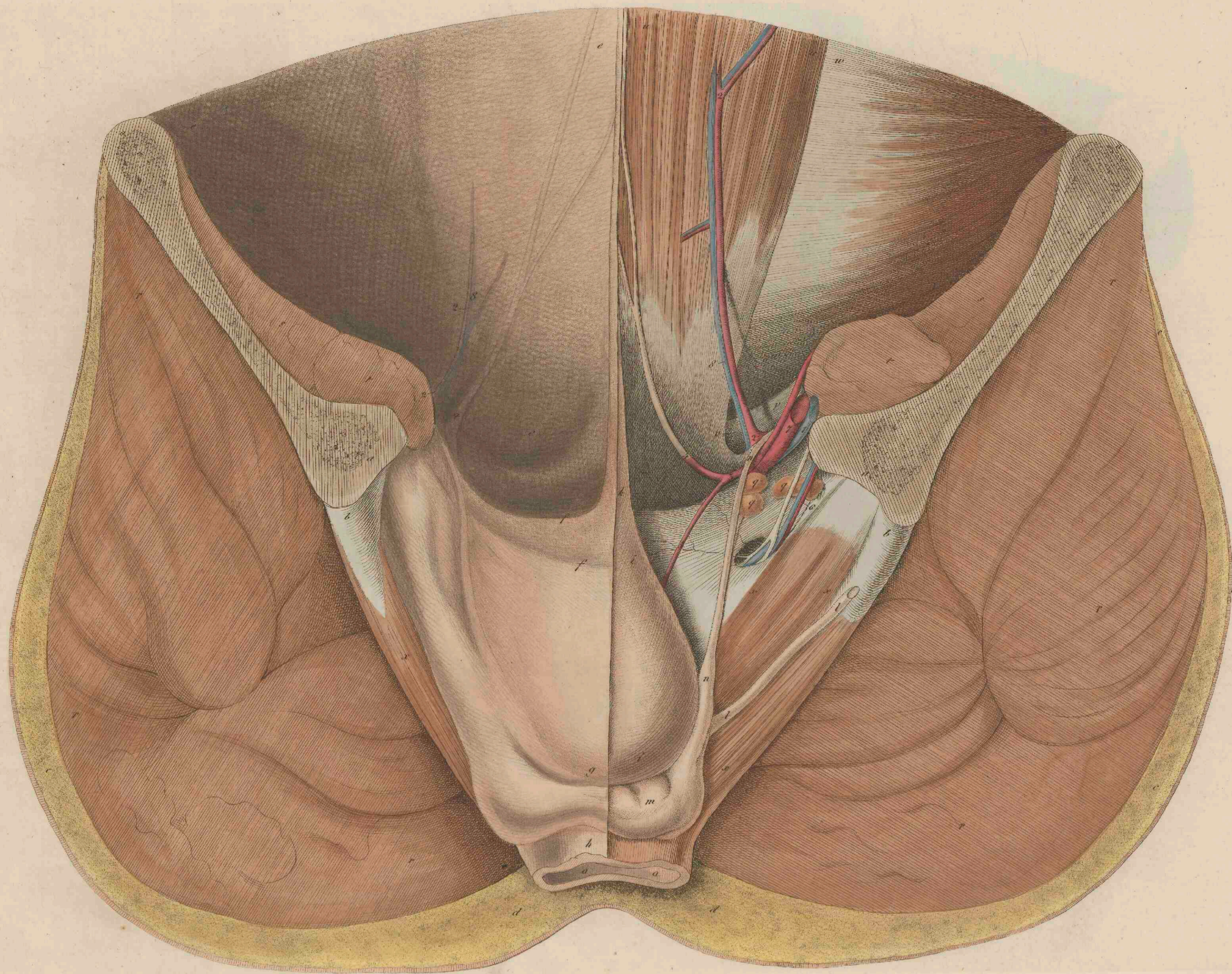
Tab. I.



R. J. Müller, ad. nat. del.

L. F. Klein, sc.





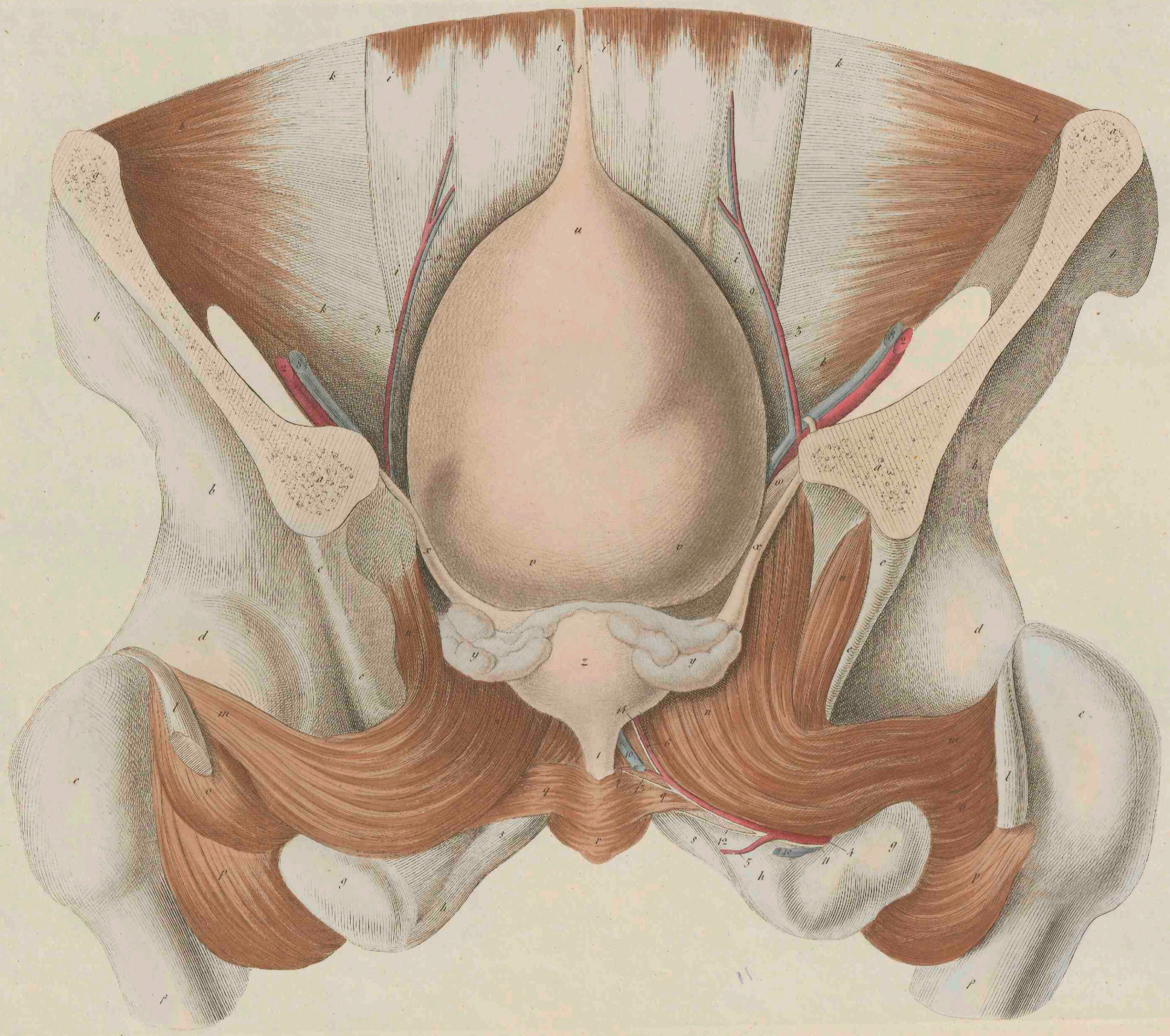
Reynolds, del. 1734.

J. P. Wilson, sculp.

Tab. III.

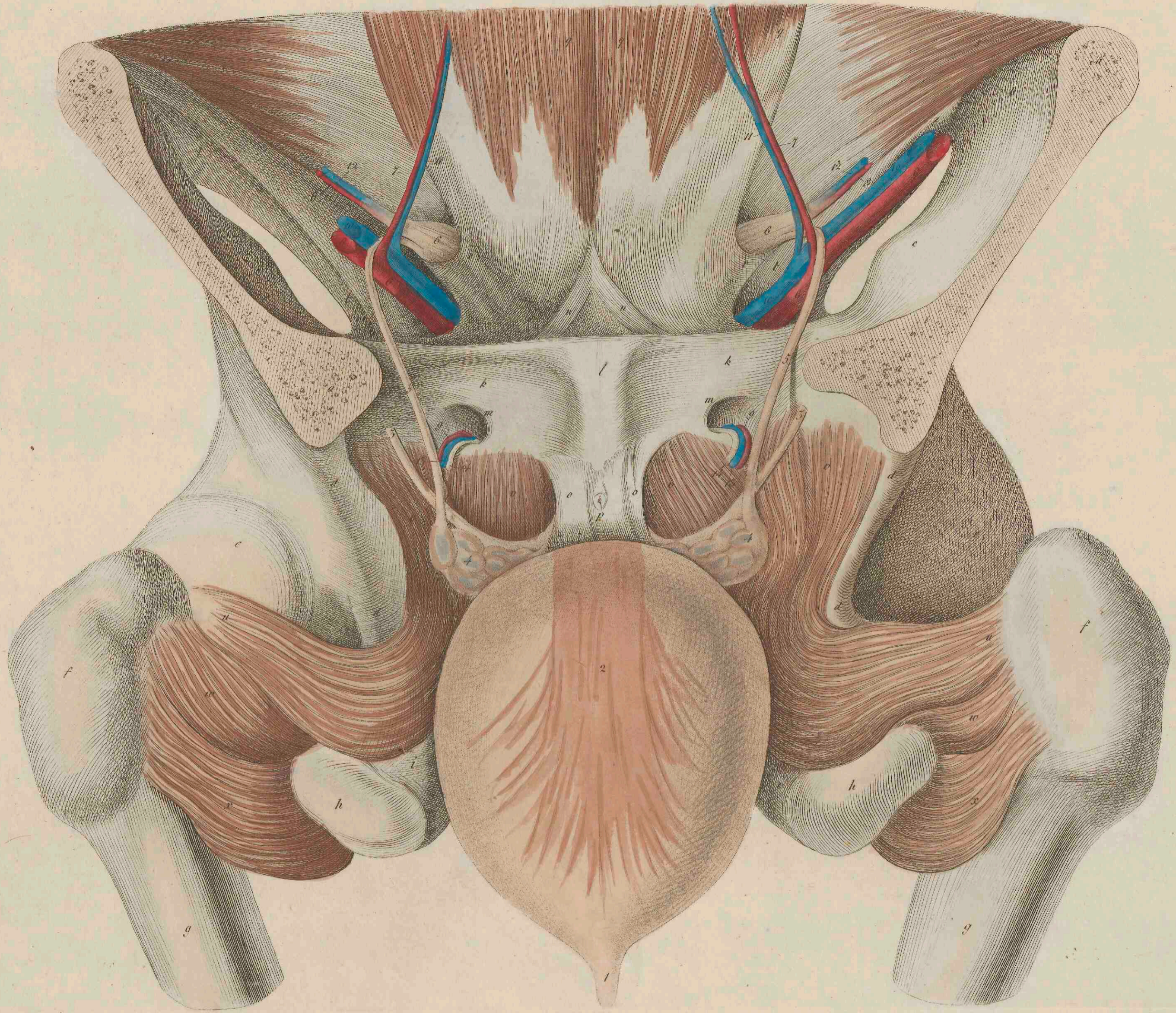
Reynolds, at. nat. del.

L. P. Scultetus sc.



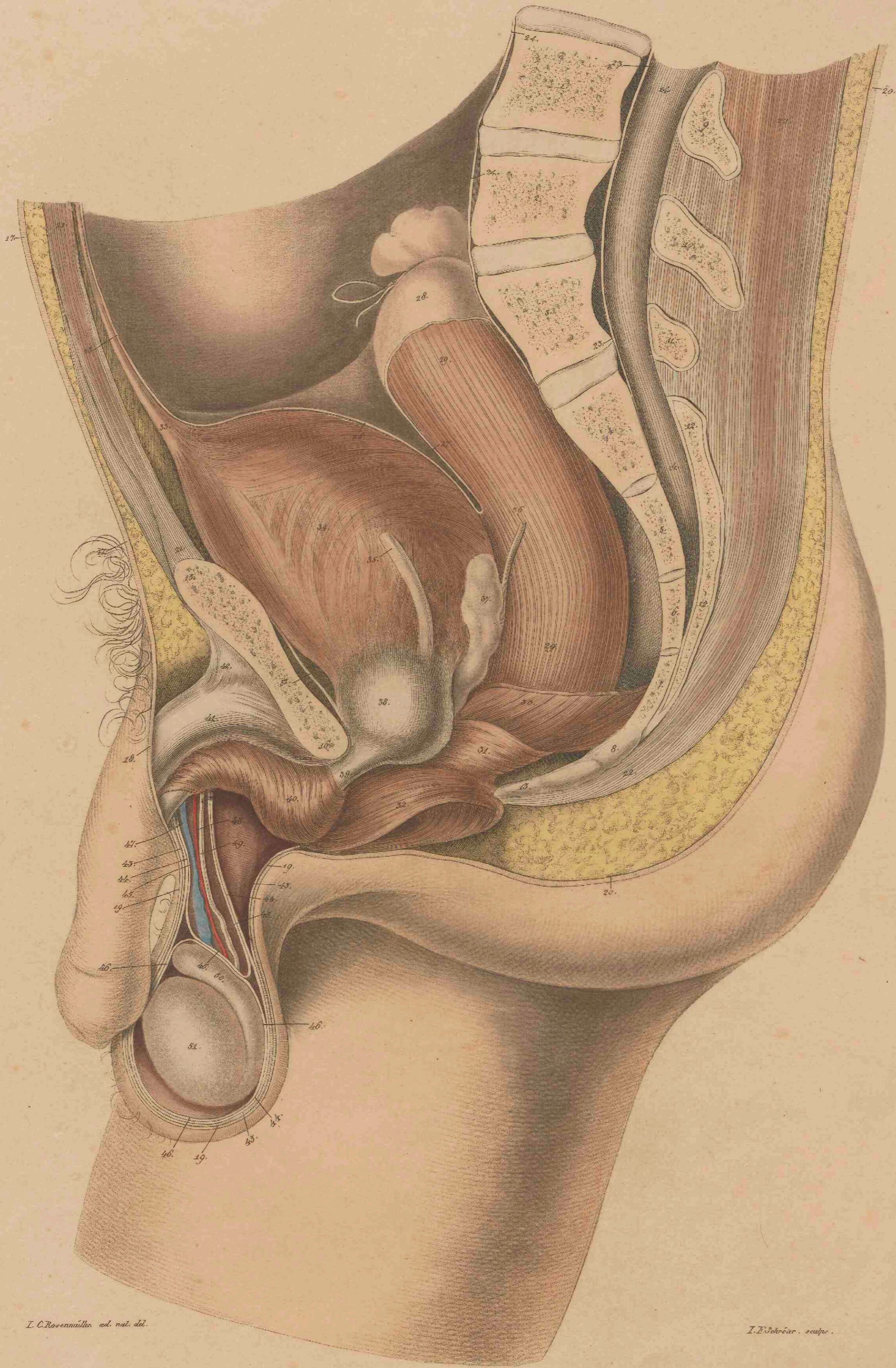
Tab. III.

Reynolds, ed. and del.



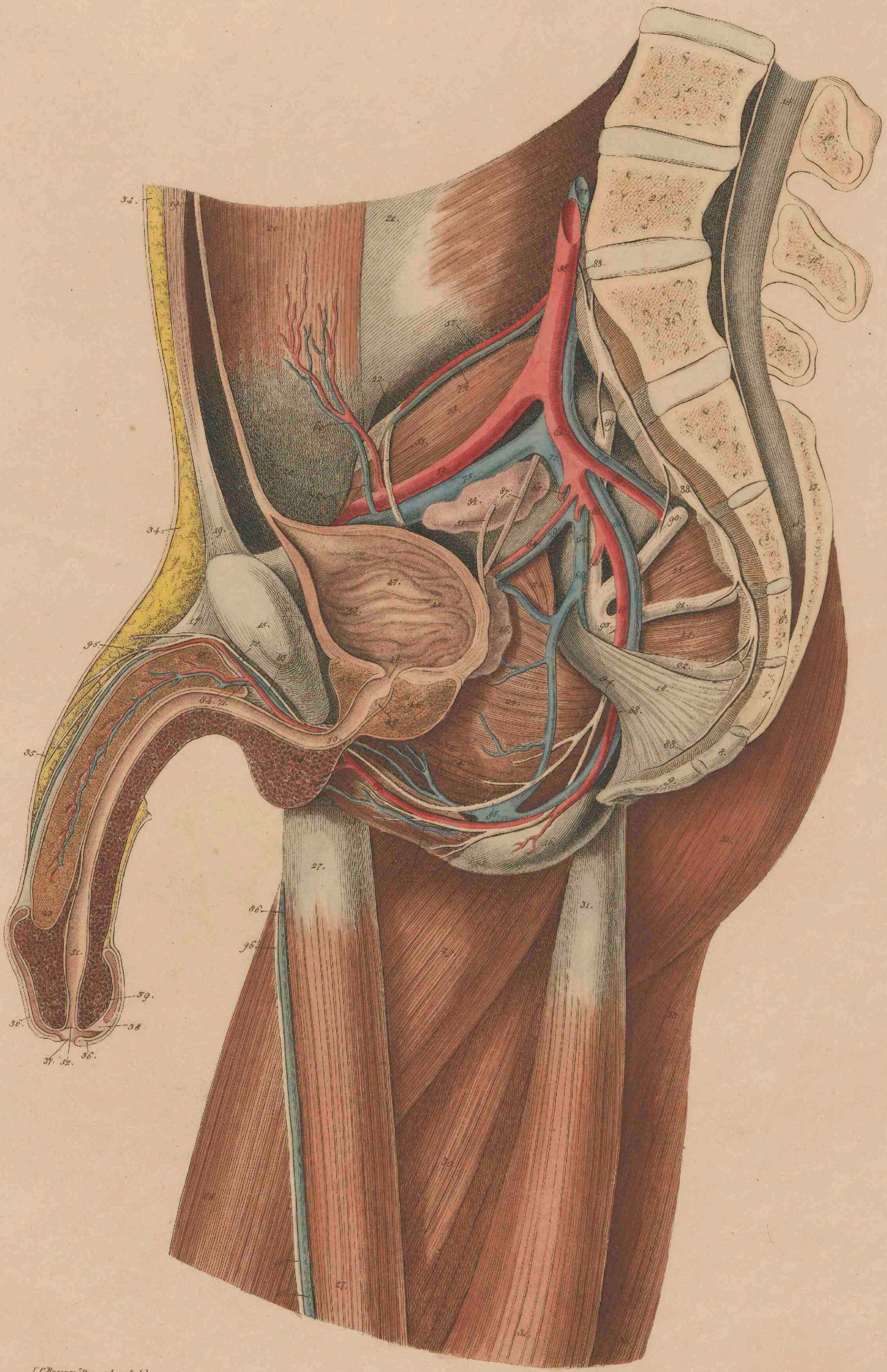
L. F. Schaefer sculp.

Tab. V.



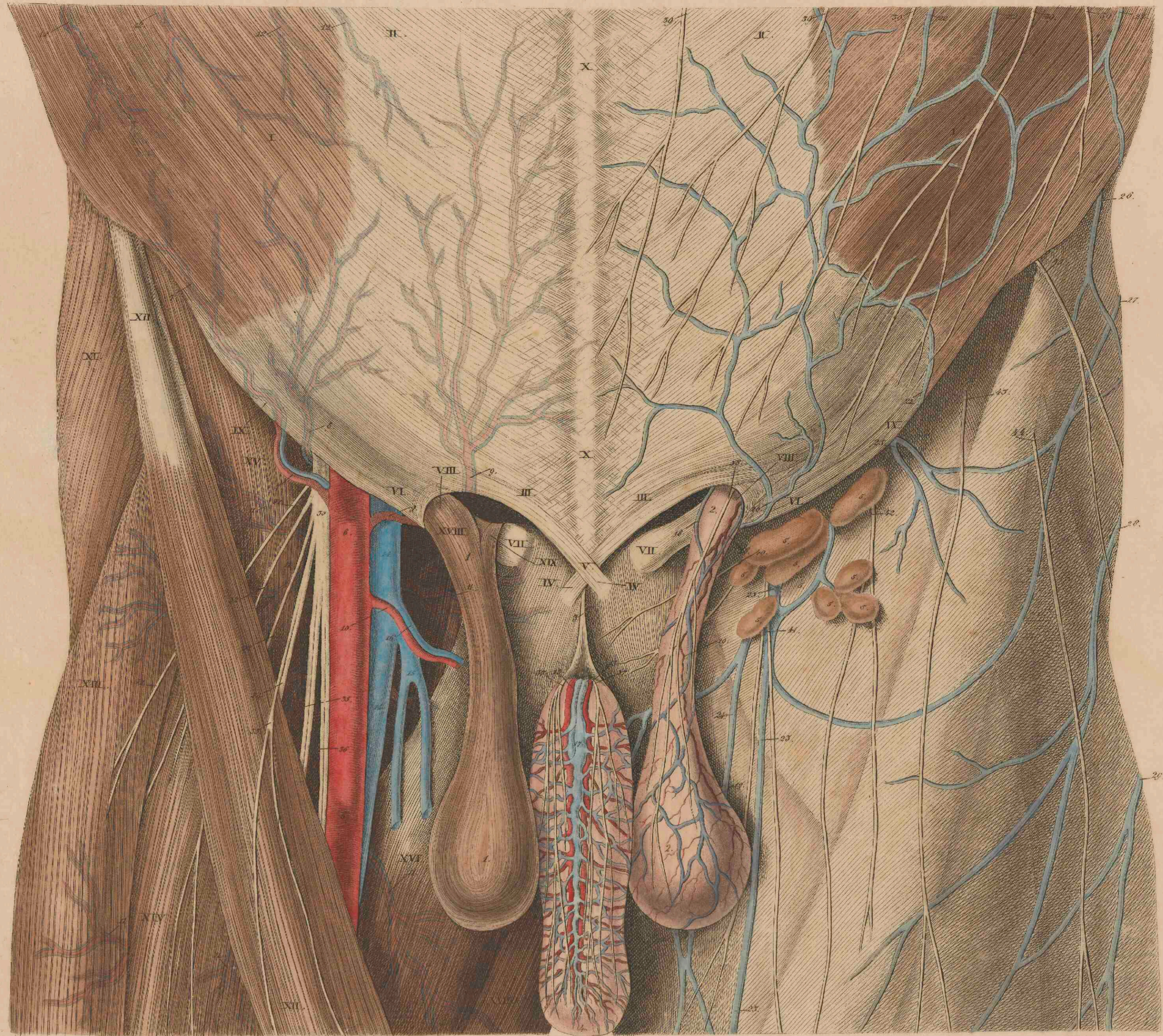I. C. Rosenmüller ad. nat. del.

I. F. Sobrius sculp.



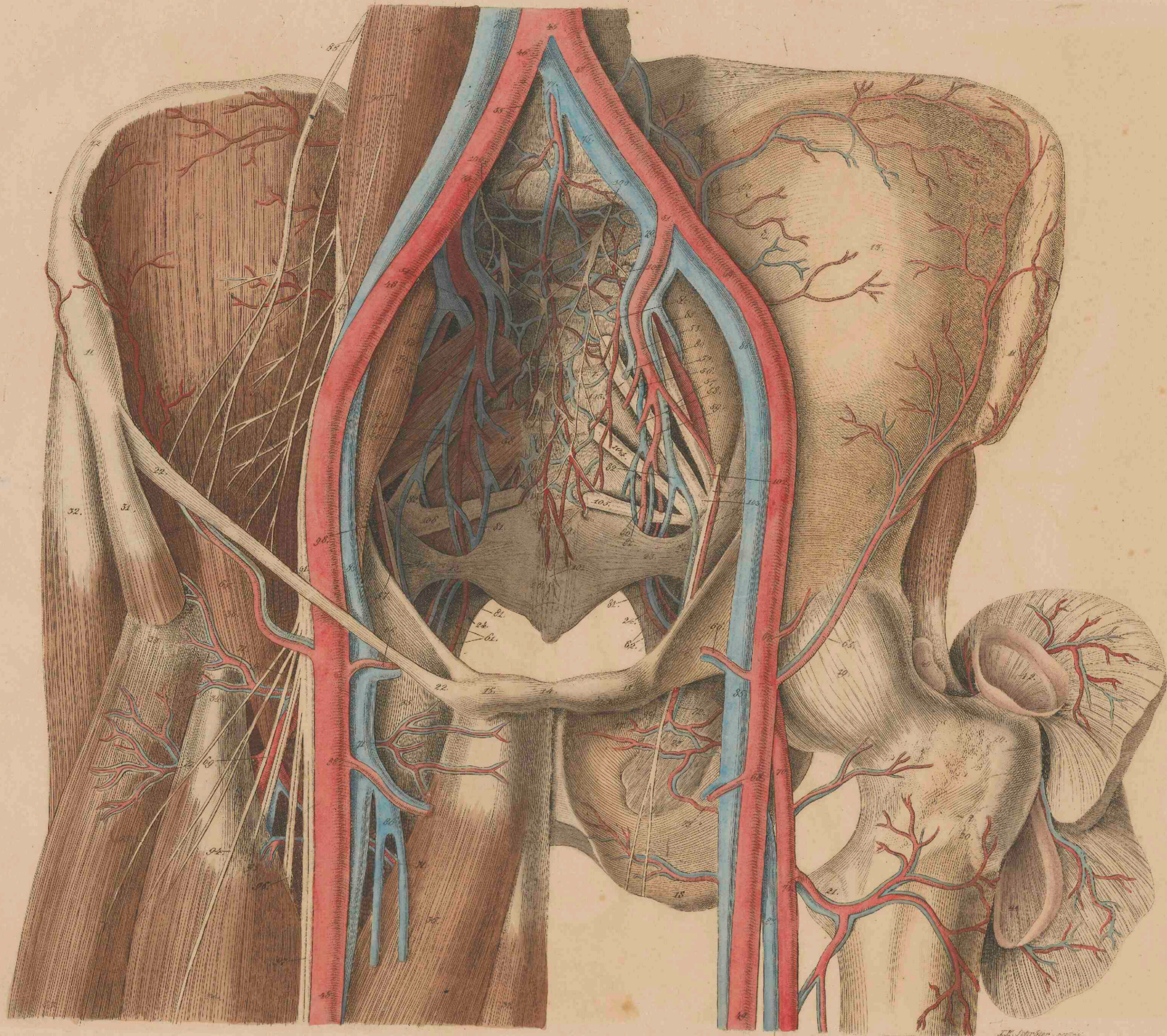
J. C. Rosenmüller. ad. nat. del.

J. F. Schröter. sculp.



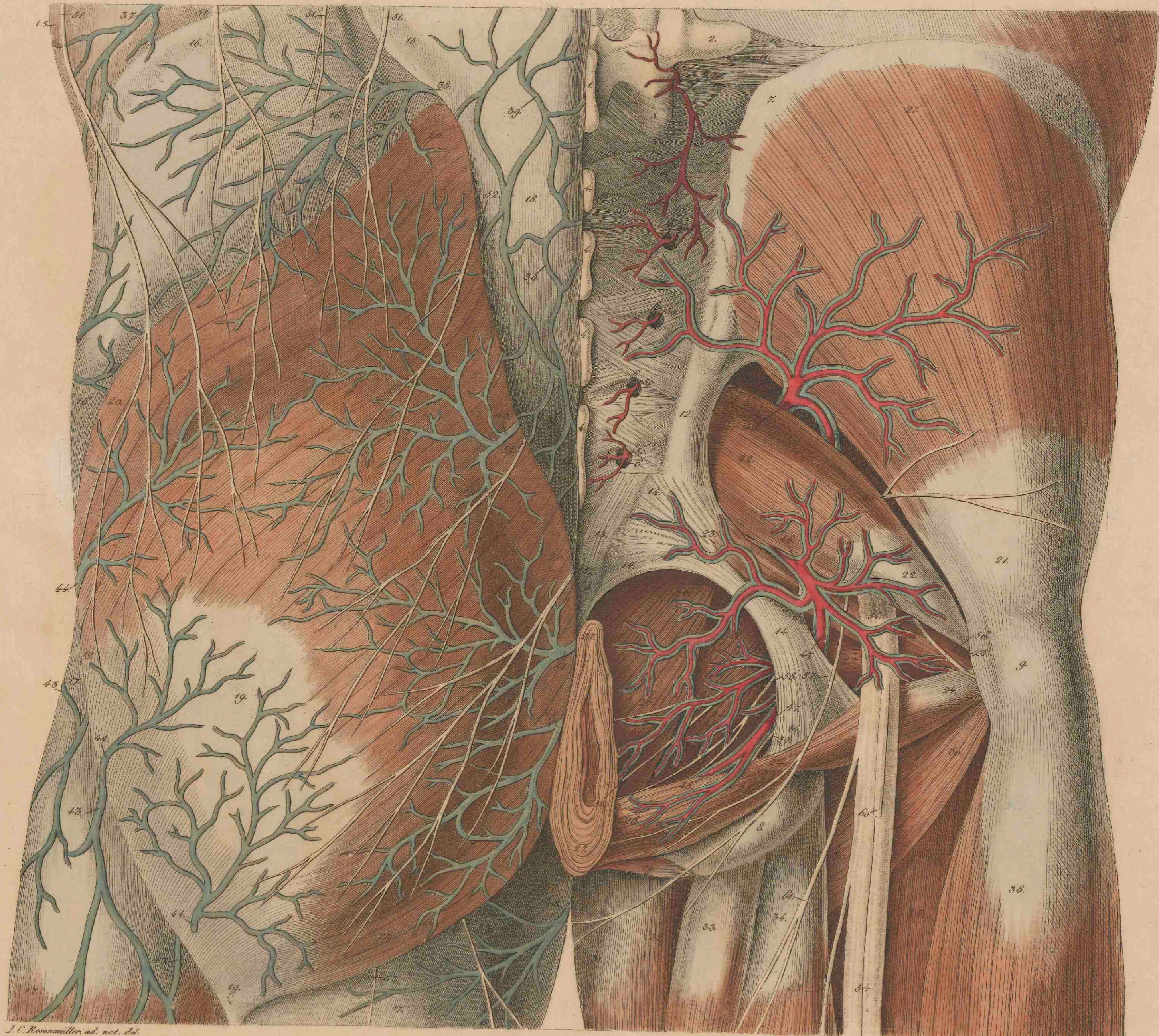J. C. Boreman del.

J. F. Schöner sculp.



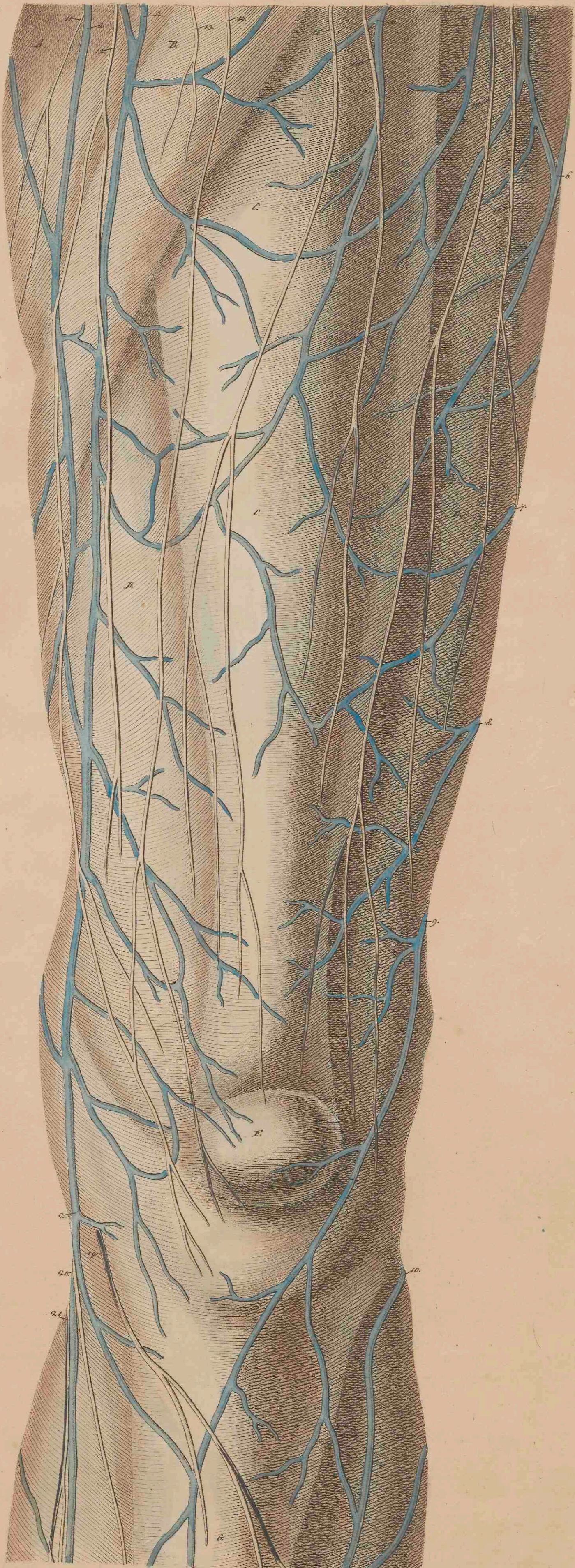J. C. Rosenmüller. ad. nat. del.

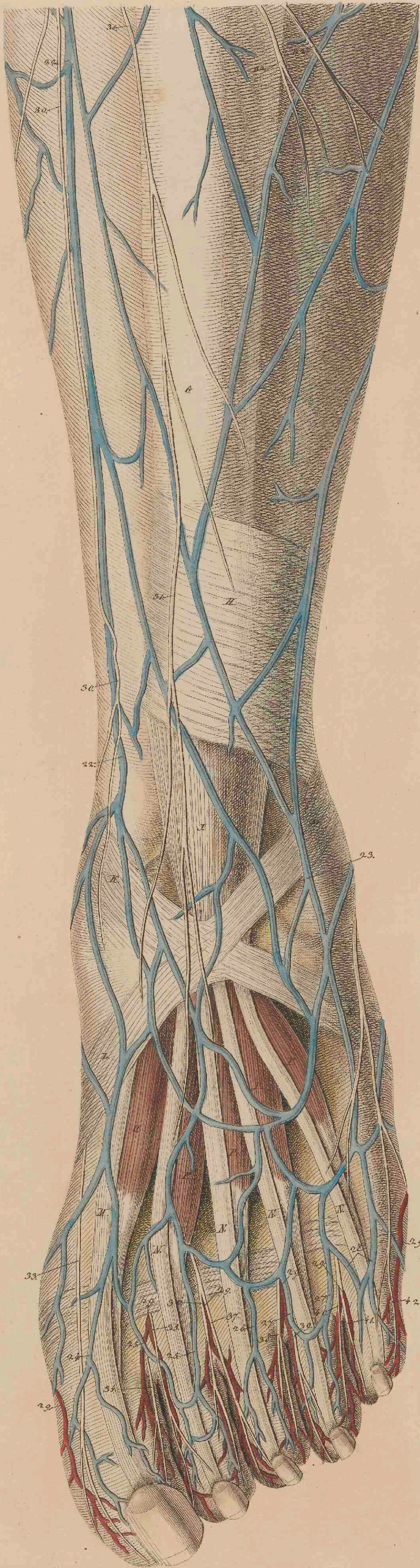
II. Intertus occip.

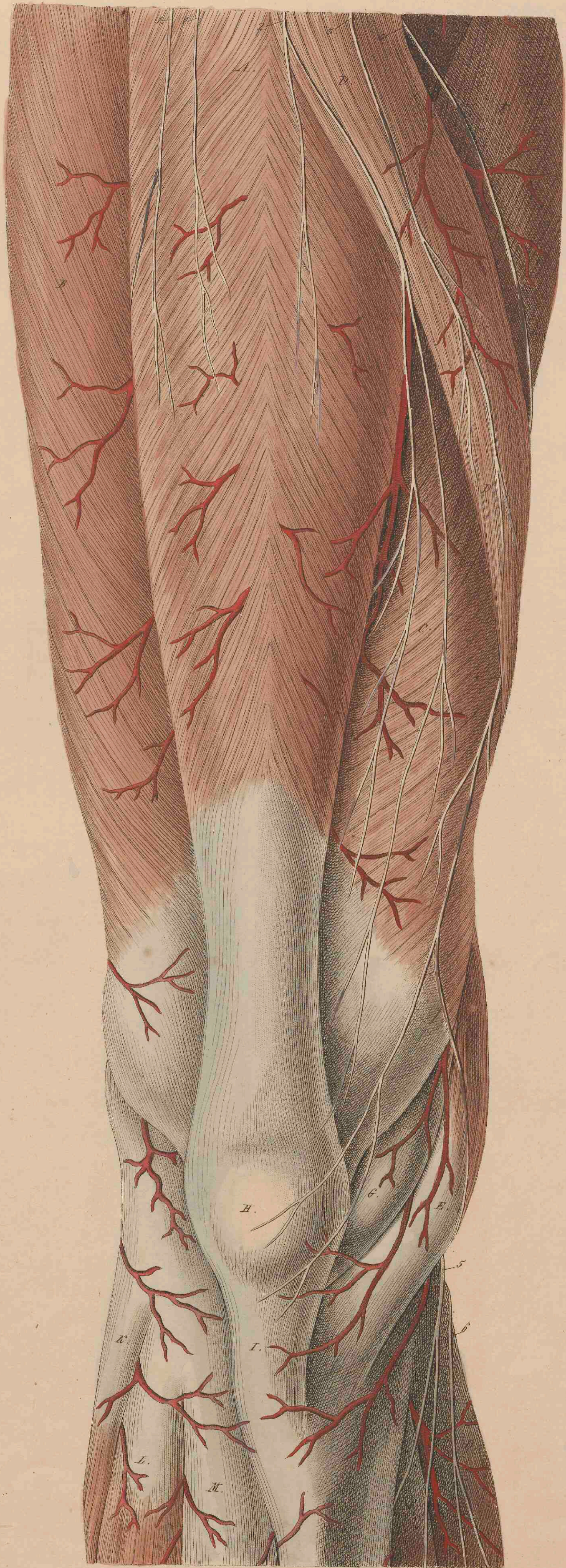

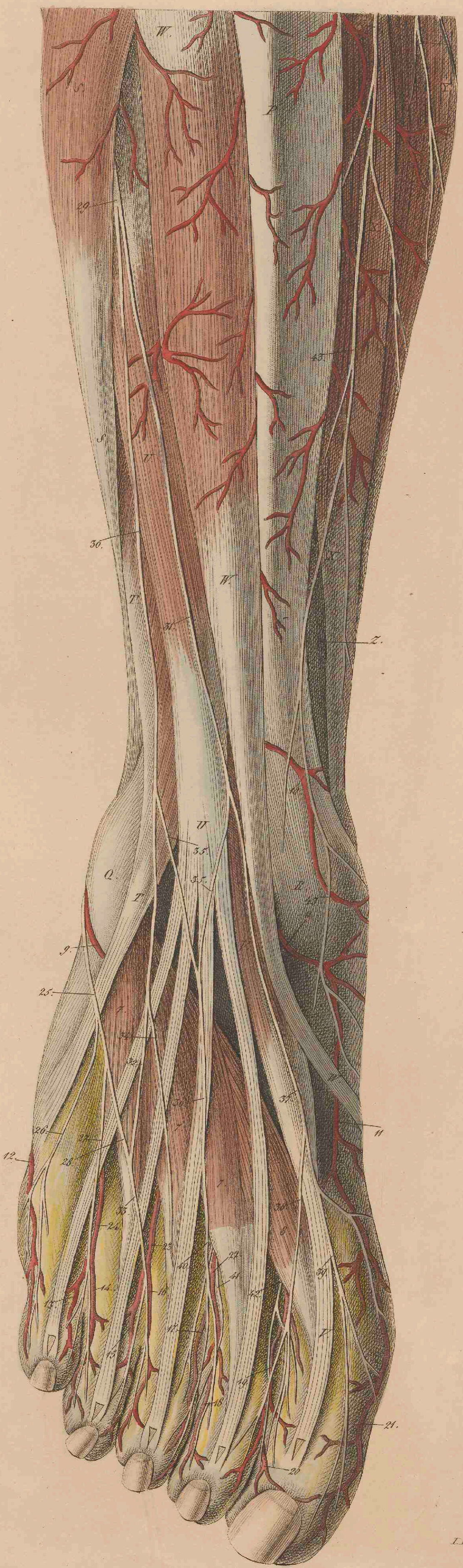
J. C. Rosenmüller ad. nat. del.

J. F. Schröter Sculps. Lipsiæ.









J. C. Rossmüller ad. nat. del.

J. E. Schröter sculp.

